AJNR

Cranial sonography of the occipital horns and gyral patterns in the occipital lobes.

A Vade and R Otto

AJNR Am J Neuroradiol 1986, 7 (5) 873-877
http://www.ajnr.org/content/7/5/873

Cranial Sonography of the Occipital Horns and Gyral Patterns in the Occipital Lobes

A. Vade[1]
R. Otto

Cranial sonographic examinations of 199 neonates were evaluated (1) to determine the incidence of an echogenic pattern in the occipital lobe that simulated a mass, (2) to relate that finding to the birth weight, and (3) to correlate it with the gyral development of the occipital lobe. This echogenic pattern was seen in infants weighing less than 1750 g at birth and was identified on both sides of the midline on the most medial paramedian sagittal sonogram scans of the head. This pseudomass was found to be due to close approximation of a large occipital horn and calcarine fissure joining other adjacent secondary fissures. The multiple fissures formed an echogenic star, and the proximity of the occipital horn and premature brain tissue texture contributed to the relatively hypoechoic background of the pseudomass. The pseudomass is limited superiorly by the parietooccipital fissure and inferiorly by the tentorium. This sonographic pattern should be recognized as a normal variant.

A characteristic echogenic pattern superimposed over a hypoechoic background is often seen in the occipital lobes of newborns on cranial sonography. This pattern may be seen on both sides of the midline and can appear prominent enough to suggest a mass lesion in the occipital lobe. The purpose of this study was to determine the incidence of this finding as related to birth weight and to correlate it anatomically with the gyral development of the occipital lobe.

Materials and Methods

Cranial sonography examinations of 199 neonates with birth weights ranging from 510–4680 g obtained from November 1983 to December 1984 were reviewed retrospectively. The scans were obtained initially for the evaluation of premature and term infants to rule out intracranial hemorrhage or congenital anomalies. All examinations were obtained with an ATL MK 500 real-time scanner with either a 7.5 or 5.0 MHz transducer. The exams were performed through the anterior fontanelle.

The sagittal views were reviewed for a characteristic echogenic pattern in the occipital lobes that consisted of several straight lines intersecting one another. Each scan was assigned a grade of either (++) for clear visualization (Fig. 1A), (+) for incomplete visualization (Fig. 1B), or (−) for no visualization of the characteristic echogenic pattern (Fig. 1C). Thirty-three scans were excluded from the study because of technical difficulties, intraventricular hemorrhage, hydrocephalus, or congenital anomalies. Technical difficulties included suboptimal imaging of the occipital lobe due to either a loss of transducer contact with the fontanelle or an improper choice of transducer or filming technique. A total of 166 scans were included in the study and graded. Each neonate was grouped into one of the eight weight classifications ranging from below 750 g to above 2500 g (Table 1).

Autopsy brain specimens from four neonates were also obtained. Three of these were premature infants who had the characteristic echogenic pattern and one was a full-term infant who did not show that pattern. Multiple sagittal sections of each brain were obtained and photographed to demonstrate fissures on the medical surface of the occipital lobe (Fig. 2) and to determine the relationship of the calcarine fissure to the occipital horns of the lateral ventricles (Figs. 3, 4, and 5). Diagramatic illustration of the same coronal projection and of

Received August 6, 1985; accepted after revision March 10, 1986.

[1] All authors: Department of Radiology, University of Illinois Hospital, 1740 W. Taylor St., Chicago, IL 60612. Address reprint requests to A. Vade.

AJNR 7:873–877, September/October 1986
0195–6108/86/0705–0873

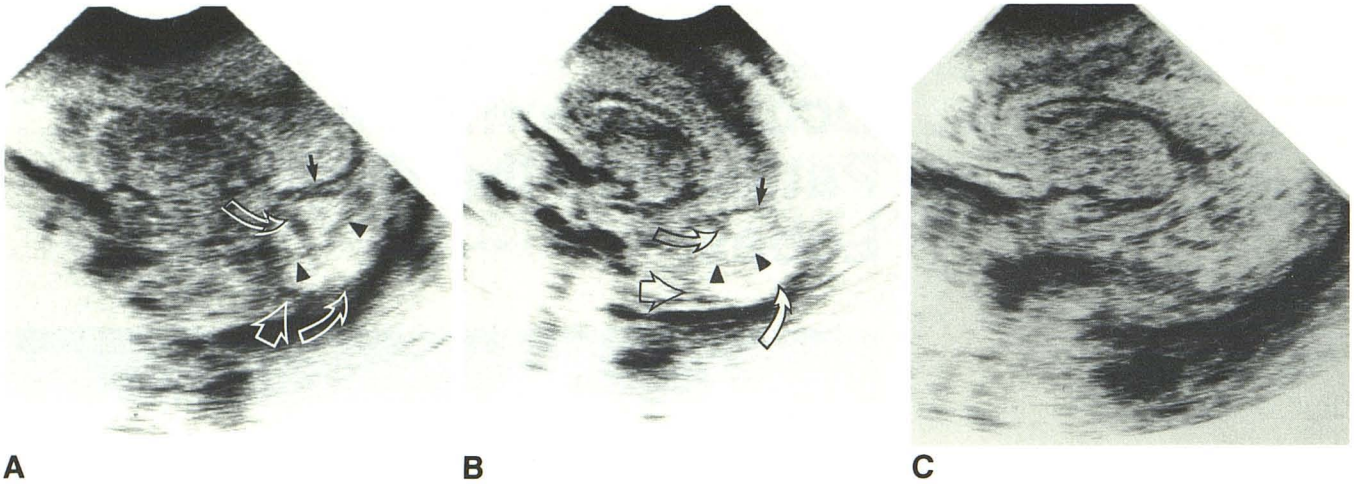

Fig. 1.—Real-time cranial sonograms of two premature infants (**A**, **B**) and one full-term infant (**C**), obtained in sagittal plane adjacent to midline, demonstrate characteristic echogenic pattern in occipital lobe clearly in **A** (birth weight 950 g), incompletely in **B** (birth weight 1050 g), and not at all in **C** (birth weight 2700 g). *Black arrows* = parietooccipital fissure; *curved arrows* = calcarine fissure; *large*, *open arrowheads* = tentorium; *small black arrowheads* = secondary fissures.

TABLE 1: **Occipital Pseudomass vs Birth Weight**

Birth Weight (grams)	++	+	−	Total	No. of Patients Showing Echogenic Pattern	Percent of Patients Showing Echogenic Pattern
Below 750	7	1	0	8	8	100
751–1000	11	0	1	12	11	92
1001–1250	14	6	5	25	20	80
1251–1500	5	9	14	28	14	50
1501–1750	2	3	18	23	5	22
1751–2000	0	0	16	16	0	0
2001–2500	0	0	20	20	0	0
2500 +	0	0	31	31	0	0

Note.—++ = pseudomass clearly visualized; + = pseudomass incompletely visualized; − = pseudomass not visualized.

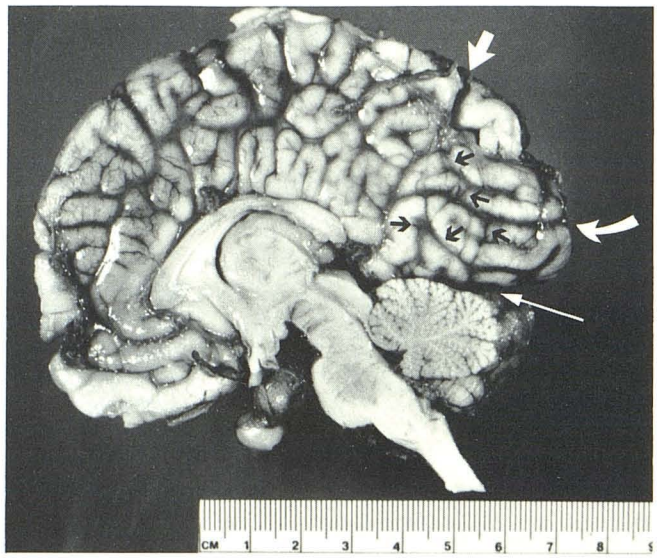

Fig. 2.—Midline section through brain of full-term infant at autopsy shows calcarine fissure (*curved arrow*) meeting parietooccipital fissure (*short*, *thick arrow*) rostrally. *Long*, *thin arrow* = tentorium; *small black arrows* = secondary fissures).

the echogenic artifact in the occipital lobe as seen on cranial sonography is presented in Figures 6 and 7, respectively.

Results

The results are presented in Table 1 and Figure 8. In newborns with birth weights up to 1750 g, a pseudomass lesion containing a characteristic echogenic pattern in the occipital lobes can be seen on the most medial of the parasagittal sonogram scans of the head (Fig. 9). The incidence of this normal finding gradually diminishes from 100% for birth weights less than 751 g to 22% for birth weights ranging between 1501–1750 g. The pseudomass lesion with the echogenic pattern is not seen in neonates with birth weights above 1750 g.

Variation in scanning technique may cause some false-negative results if the appropriate section is not obtained. Also, if the gain settings are not increased enough, the characteristic echogenic pattern in the occipital lobes may not be appreciated.

Discussion

The growth of the cerebral hemispheres is slow and steady between the second month and early part of the sixth month of gestational life, and it accelerates thereafter [1]. The flat (lissencephalic) brain of the fetus slowly acquires the gyral pattern of adults. The calcarine fissure is believed to appear

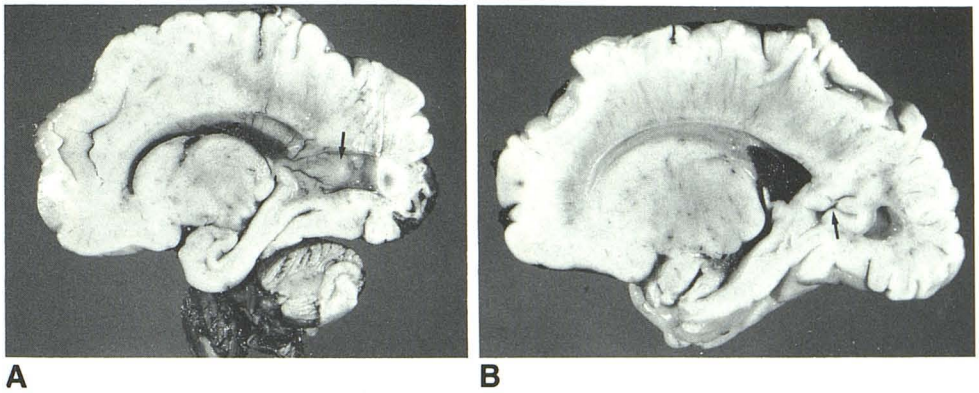

Fig. 3.—Paramidline sagittal section (**A**) through brain specimen of premature infant who had shown characteristic echogenic pattern in occipital lobe at birth (seen in Figure 1A). The prominent impression on medial aspect of occipital horn (*arrow* in **A**) is made by calcarine fissure. A more medial section (**B**) from same brain specimen shows calcarine fissure and its adjacent secondary fissures (*arrow*), which gave rise to the echogenic lines in pseudomass on sonogram. Note that the calcarine fissure is closely applied to the occipital horn.

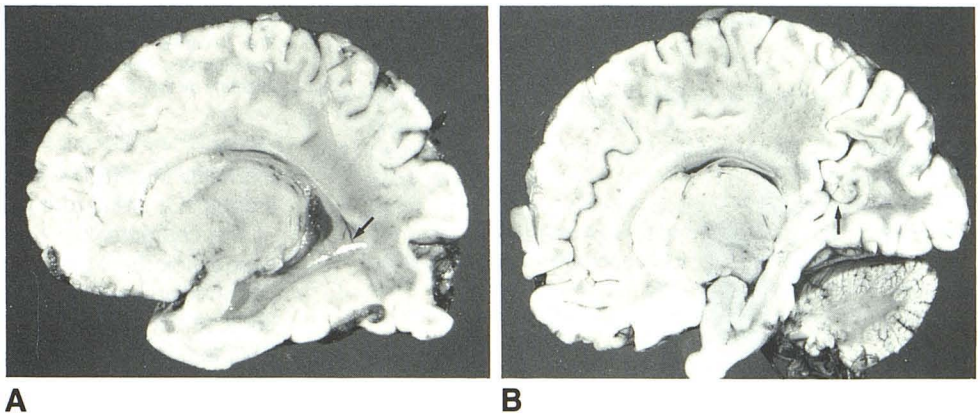

Fig. 4.—**A**, Paramidline sagittal section through brain specimen of full-term infant who did not show characteristic echogenic pattern in occipital lobe (seen in Fig. 1C) shows that the impression made by calcarine sulcus on medial wall of occipital horn is much less prominent (*arrow*) than as seen in Figure 3A. **B**, More medial section from same brain specimen shows calcarine and its adjacent secondary fissures (*arrow*) not so closely approximated to occipital horn as in Figure 3B.

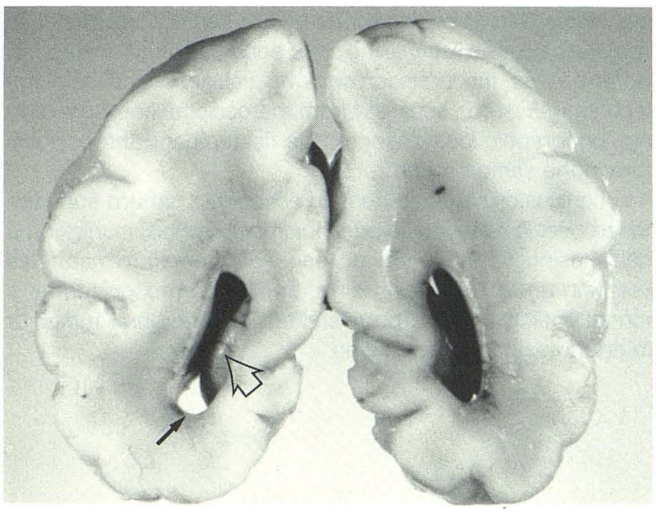

Fig. 5.—Coronal section through brain of premature neonate weighing 1750 g at birth shows the effect of calcarine fissure causing a hump (*large open arrow*) in medial wall of occipital horn (*small black arrow*).

between the 16th and 26th weeks of gestational life [1, 2]. As the calcarine fissure deepens, the adjacent cuneus and medial occipitotemporal gyri become distinct by the 27th week of gestational age [2]. As the calcarine fissure deepens, it also indents the medial aspect of the occipital horn of the lateral ventricle [2, 3]. The calcarine fissure joins the parietooccipital fissure rostrally [2]. The secondary gyri of the occipital lobules appear at 34 weeks of gestational life.

Premature infants have larger ventricles than do term infants, whose ventricles are usually narrow and slit-shaped [1]. The developmental changes in the contour of fetal cerebral ventricles occur secondary to gradual narrowing of the lumen of the brain vesicle due to growth and increased thickness of its walls [1]. Hence, premature infants of 24–27 weeks gestational age have larger ventricles, less brain mass, and a well-developed calcarine fissure, which causes a prominent identation on the medial wall of the occipital horn of the lateral ventricle. With the onset of growth spurt, around 24 weeks of gestational life, the brain mass increases. By term, the calcarine fissure is not as closely applied to, nor does it

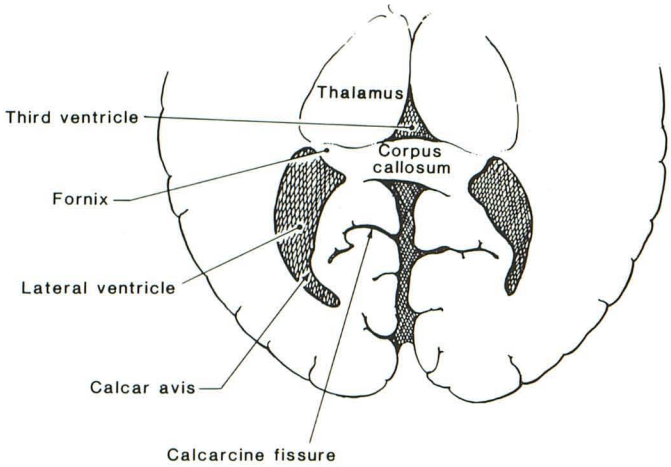

Fig. 6.—Line drawing of coronal section of brain through occipital horns shows relationship of calcarine fissures to occipital horns of lateral ventricle.

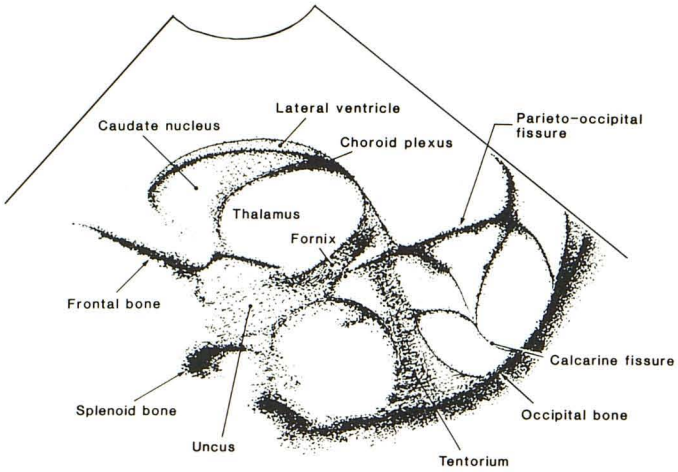

Fig. 7.—Line drawing of parasagittal section through brain as seen on cranial sonography of premature baby with pseudomass lesion in occipital lobe. The calcarine and its secondary fissures form the echogenic lines in the pseudomass, which is limited superiorly by the parietooccipital fissure and inferiorly by the tentorium.

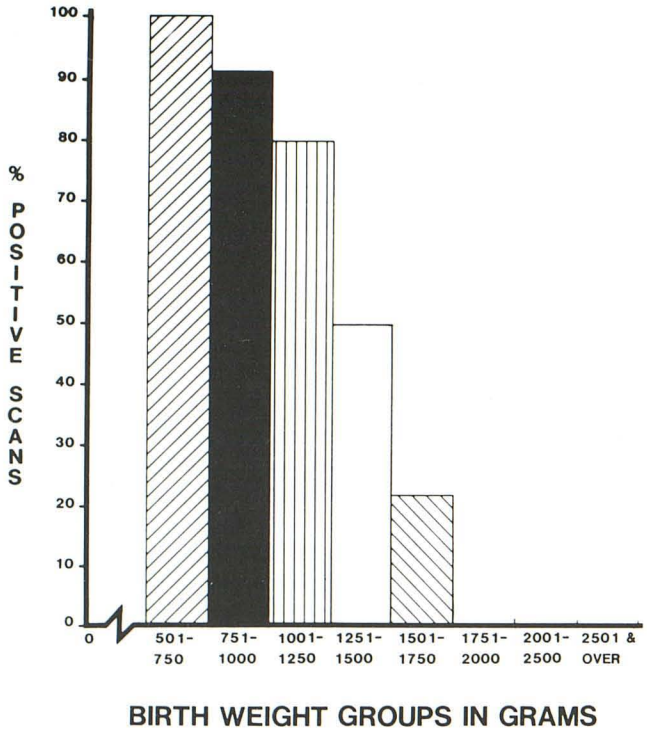

Fig. 8.—Bar diagram showing percentage of sonogram scans that showed pseudomass with star artifact in each birth-weight group.

markedly indent, the occipital horn of the lateral ventricle, as it does in a premature infant.

The characteristic echogenic pattern superimposed on a hypoechoic background is seen on the most medial of the paramedian sagittal sections of cranial sonogram examinations, and it may mimic a mass lesion. The echogenic lines in the pseudomass are caused by the calcarine and adjacent secondary fissures. The superior margin of the pseudomass is formed by the parietooccipital fissure, and the inferior margin is formed by the tentorium. The hypoechoic background of the pseudomass could be due to the premature brain texture [4, 5], which has less sulci, or to the close approximation of the large occipital horn to the calcarine fissure. As the child matures, the brain parenchyma contains less water, and as more secondary and tertiary fissures arise from the calcarine fissure, the brain becomes more echogenic. Moreover, as the brain grows, the calcarine and adjacent secondary fissures separate from the occipital horn, preventing sonographic localization of the fissures and the occipital horn in the same section.

In conclusion, a characteristic echogenic pattern superimposed over a relatively hypoechoic background, mimicking a mass lesion in the occipital lobes of premature neonates weighing under 1751 g at birth, should be recognized as a normal finding and not be mistaken for a cerebral tumor or an arteriovenous malformation.

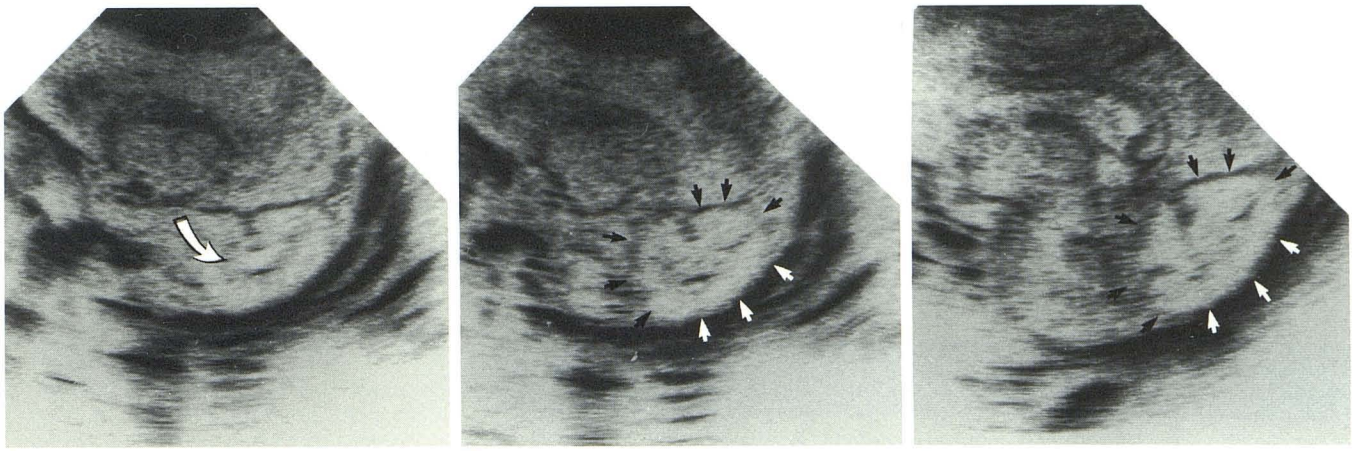

A B C

Fig. 9.—Real-time sagittal sections through head of premature baby with birth weight of 800 g. **A**, lateral; **B**, medial; **C**, midline. **A** shows occipital horn (*arrow*), **B** and **C** show pseudomass (*arrows*) containing characteristic echogenic pattern.

ACKNOWLEDGMENTS

We thank D. Schmidt and J. Ryva for assisting with cranial sonography and for slicing the autopsy brain specimens, and Leah M. Freeman for preparing the manuscript.

REFERENCES

1. Friede RL. Gross and microscopic development of the central nervous system. In: Friede RL, ed. *Developmental neuropathology*. New York: Springer-Verlag, **1975**:1–23
2. Chi JG, Dooling EC, Gilles FH. Gyral development of the human brain. *Ann Neurol* **1977**;1:86–93
3. Last RJ, Tompsett DH. Casts of the cerebral ventricles. *Br J Surg* **1953**;40:525–543
4. Brant-Zawadzki M, Enzmann D. Using computed tomography of the brain to correlate low white matter attenuation with early gestational age in neonates. *Radiology* **1981**;139:105–108
5. Case KJ, Hirsh J, Case MJ. Simulation of significant pathology by normal hypoechoic white matter in cranial ultrasound. *JCU* **1983**;11:281–285