

Are your **MRI contrast agents** cost-effective?

Learn more about generic **Gadolinium-Based Contrast Agents**.



FRESENIUS
KABI

caring for life

AJNR

CT of ischemic infarctions in the territory of the anterior choroidal artery: a review of 28 cases.

G L Paroni Sterbini, L M Agatiello, A Stocchi and F M Solivetti

AJNR Am J Neuroradiol 1987, 8 (2) 229-232

<http://www.ajnr.org/content/8/2/229>

This information is current as
of April 19, 2024.

CT of Ischemic Infarctions in the Territory of the Anterior Choroidal Artery: A Review of 28 Cases

G. L. Paroni Sterbini¹
L. Mossuto Agatiello²
A. Stocchi¹
F. M. Solivetti¹

The purpose of the present study was to examine the incidence, causal factors, and anatomic localizations of infarction in the territory of the anterior choroidal artery. We studied 28 patients who had CT evidence of infarction in this territory. The affected structures taken into consideration were the posterior limb of the internal capsule, the retrolenticular portion of the internal capsule, the internal portion of the globus pallidus, and the lateral thalamus. Three conclusions are drawn: (1) that ischemic infarcts in the territory of the anterior choroidal artery are rare, representing 2.9% of all cerebral ischemic lesions in our material; (2) that the incidence of a possible embolic origin is significant; and (3) that the posterior two-thirds of the posterior limb of the internal capsule and the retrolenticular segment are the more frequently affected structures, and conversely, that the medial pallidus and the thalamus are less often involved.

The anterior choroidal artery usually arises from the internal carotid artery near the posterior communicating artery and the optic tract, although it is sometimes a branch of the middle cerebral or posterior communicating artery. However, variation in the origin of the artery does not produce any changes in its specific vascular territory. Two segments are differentiated by angiography: the basal cisternal segment and the intraventricular plexal segment [1]. The first, directed backward and laterally upward, ends in the temporal horn of the lateral ventricle; the latter is clearly in an upward and medial direction with a wide concave curve, ending near the choroidal plexus in the lower portion of the lateral ventricle (Fig. 1).

The anterior choroidal artery has numerous deep penetrating branches that supply a large somewhat variable territory of the telencephalon [2-6]: the posterior two-thirds of the posterior limb of the internal capsule, the genu and retrolenticular segment of the internal capsule with the optic and acoustic radiations, the medial portion of the globus pallidus, the lateral portion of the optic tract, the lateral half of the lateral geniculate body, the upper portion of the cerebral peduncle, the uncus, part of the amygdaloid nucleus, the anterior portions of the hippocampus, the anterior portions of the dentate fascia, the tail of the caudate nucleus, and the temporal portions of the choroid plexus (Fig. 2).

According to Percheron [7], the anterior choroidal artery cannot be considered an arterial source for thalamic vascularization, and the vascularization of this territory is only irregular and superficial. Anastomoses with branches of the posterior cerebral artery and posterior communicating artery often coexist.

The anterior choroidal artery syndrome was first described by Foix et al. in 1925 [8]. When complete, the syndrome includes hemiplegia, hemianesthesia, and homonymous lateral hemianopsia. Hemiplegia is caused by the interruption of the corticospinal fibers that cross the posterior half of the posterior limb of the internal capsule in the more caudal plane. The sensory deficit is due to the involvement of the thalamocortical radiations. The homonymous lateral hemianopsia may be caused by the lesion of the proximal geniculocalcarine tract and/or of the lateral geniculate body and/or of the optic tract. The neurologic picture may also be

Received December 11, 1985; accepted after revision July 29, 1986.

¹ Department of Diagnostic Radiology, San Giovanni Battista Hospital, SMOM, Via Luigi Dasti, 7, 00148 Rome, Italy.

² Department of Neurology, San Giovanni Battista Hospital, SMOM, Via Luigi Dasti, 7, 00148 Rome, Italy.

AJNR 8:229-232, March/April 1987

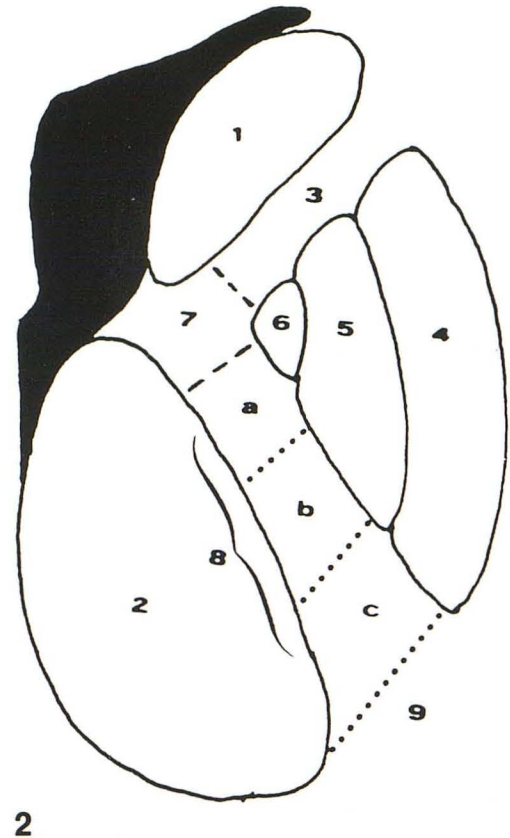
0195-6108/87/0802-0229

© American Society of Neuroradiology

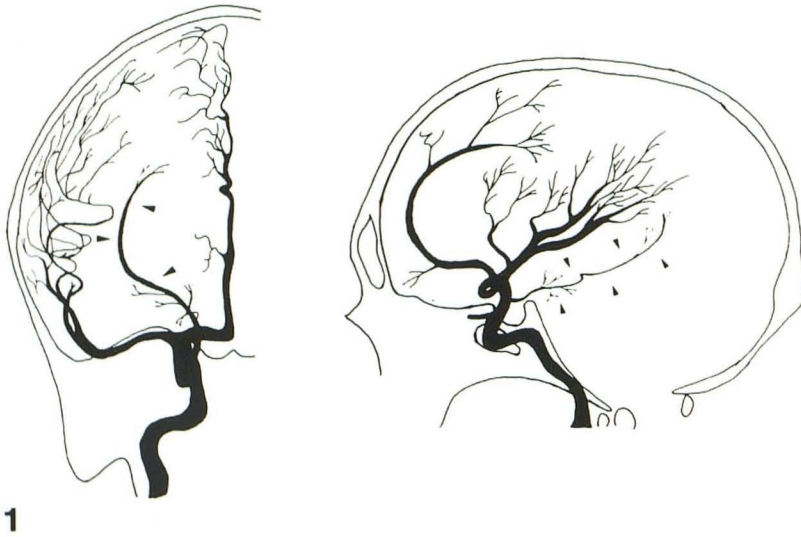

Fig. 1.—Anterior choroidal artery (arrowheads). Frontal (left) and lateral (right) angiographic view.

Fig. 2.—20° CT horizontal plane at level of internal capsule surrounded by pertinent structures. 1 = Head of caudate nucleus; 2 = Thalamus; 3 = Anterior limb of internal capsule; 4 = Putamen; 5 = Lateral globus pallidus; 6 = Medial globus pallidus; 7 = Genu of internal capsule; 8 = Posterior limb of internal capsule: a = anterior third, b = middle third, c = posterior third; 9 = Retrolenticular segment.



associated with neuropsychological symptoms, including visual neglect, disorders of visuospatial strategy, constructional apraxia and anosognosia in the lesions of the minor hemisphere, and disorders of speech in dominant hemisphere lesions [9].

Subjects and Methods

This study includes 28 patients with CT evidence of infarction in the area of distribution of the anterior choroidal artery observed in the 2-year period between January 1983 and December 1984. Of these, 27 patients were examined by neurologists according to a protocol, and usual risk factors for cerebrovascular disease were taken into consideration.

Among the 28 patients in our study who had acceptable evidence of infarction in the territory of the anterior choroidal artery, 20 were hospitalized in a neurorehabilitation hospital and account for 2.9% of all 680 cerebral ischemic lesions found during the period 1983–1984.

The scans consisted of eight 10-mm thick sections, which extended from the base to the vertex of the skull. The internal capsule could be visualized in three slices. In some cases 5-mm thick slices were obtained. In selected cases the scan was repeated with contrast infusion.

The diagnosis of an ischemic lesion in the territory of the anterior choroidal artery was made according to the topographic criteria and clinical pictures mentioned above. The anatomic territories affected were carefully studied in spite of the difficulties in carrying out this task. Indeed, it is well known that although the inclination angle of

the gantry remains constant (20°), standardization of the various layers is almost impossible. The differentiation of single territories supplied by the anterior choroidal artery was particularly difficult because of their limited volume and similar Hounsfield-unit values. According to the estimated time of the lesion the scans were divided into three groups: acute (within 10 days), subacute (between 11 and 30 days), and stable (more than 30 days).

To evaluate the extent of the lesion we considered only the anatomic structures that we believed to be the most detectable by CT in a horizontal plane [10]: the posterior limb and the retrolenticular portion of the internal capsule at midthalamic-pineal level, the internal capsule (posterior limb) at subthalamic level, the medial globus pallidus, and corresponding to plates 20° – 9 and 20° – 10 in the atlas of Matsui and Hirano [11]. Using their measurements, we divided the lesions into two groups: total infarctions and partial infarctions. Total infarctions were considered those that involved all the above-listed structures; partial infarctions were those that involved only a few of those structures. The latter group was subdivided into lacunar and nonlacunar infarctions; lacunar infarctions were considered only the smallest ones—less than 4 ml estimated volume, according to the criteria followed by Pulicino et al. [12]. The involvement of the thalamus and the coexistence with other ischemic lesions were also considered.

Results

Age, sex, and vascular risk factors are given in Table 1. One lesion was acute, 11 subacute, and 16 stable. The

hemispheres were equally affected: 14 lesions on the right, 14 on the left. Four patients had CT evidence of total infarction, seven patients showed ischemic lesions of the lacunar type, and the remaining 17 patients had partial nonlacunar infarctions (Figs. 3, 4, and 5).

The anatomic distribution of the lesions is summarized in Table 2. The single territories were involved as follows: the posterior limb of the internal capsule, including the anterior third (in addition to the four cases of total infarction) was entirely involved in four other cases; however, in one case a

deep infarction in the territory of the middle cerebral artery was also present. Infarctions in the posterior two-thirds of the posterior limb of the internal capsule were seen in 10 cases. Lesions involving only the posterior third of the posterior limb were present in nine cases, and the middle third was only involved in one case. The retrolenticular portion of the internal capsule was involved in 16 cases. In this area the lesion was always associated with infarction in the posterior portion of the posterior limb: six cases with the entire posterior limb, eight cases with the posterior two-thirds, and two cases with the posterior one-third. The more caudal portion of the internal capsule (subthalamic level) was involved in 12 cases. This accounts for prominent caudal extension in the vertical plane, but hypodensity never extended upward to the corona radiata. The internal portion of the globus pallidus was involved in six cases, including the total infarctions. In five cases the lesion extended medially involving the most lateral portion of the thalamus. Fifteen patients had associated ischemic lesions, mostly located in the territory supplied by the middle cerebral artery.

TABLE 1: Etiological Features in 28 Patients with Infarctions in the Anterior Choroidal Artery Territory

Age (in years)	
Mean	63.1
Range	34-81
Gender	
Men	15
Women	13
Vascular risk factors ^a	
Hypertension	11 (40.7%)
Possible embolic source	8 (29.6%)
Possible carotid source	3 (11.1%)
Possible cardiac source	5 (18.5%)
Diabetes mellitus	7 (25.9%)
Clinical transient ischemic attacks	2 (7.4%)
Peripheral vascular disease	1 (3.7%)
Other etiology ^b	1 (3.7%)

^a Data available for 27 patients.

^b Infarction after intracranial ligation of posterior communicating aneurysm.

Discussion

This study confirms that ischemic infarctions in the territory of the anterior choroidal artery are rare. In this series of 28 cases, only 13 (46%) of the patients with infarction located in this territory had a single lesion without evidence of other ischemic lesions. Occlusion of the artery at its origin, involving the entire territory, was very rare: four cases (14%). On the

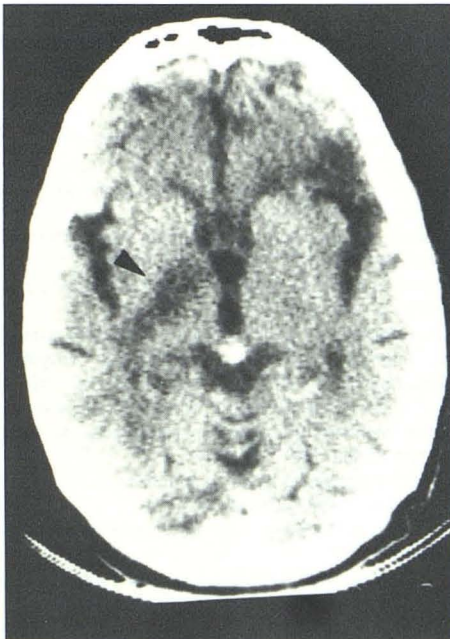


Fig. 3.—Case 16. CT scan showing large right infarction (total infarction) in territory of anterior choroidal artery (arrowhead) with associated left watershed anterior infarction.

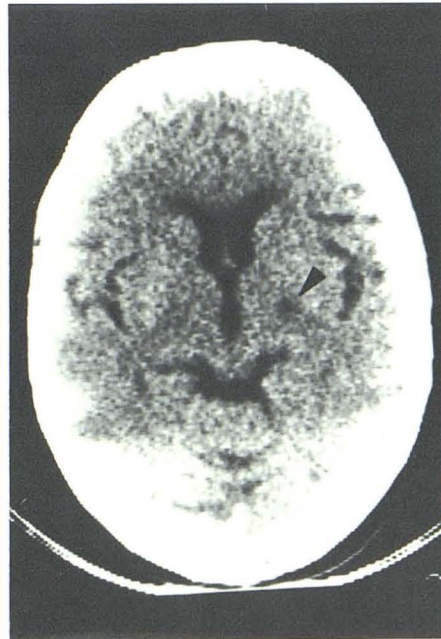


Fig. 4.—Case 9. CT scan showing lacunar infarct in posterior third of posterior limb of left internal capsule (arrowhead).

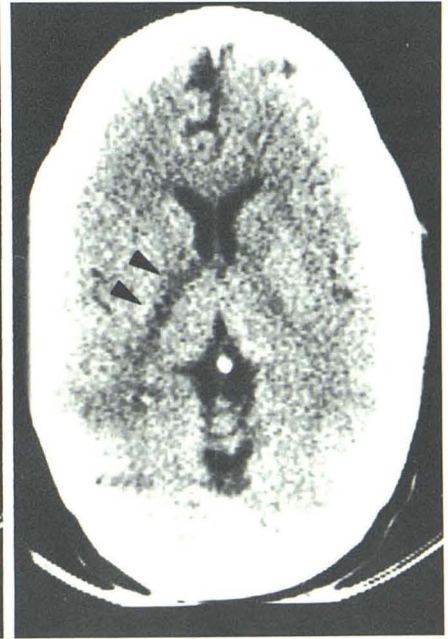

Fig. 5.—Case 10. CT evidence of nonlacunar infarction involving entire posterior limb of right internal capsule (arrowheads).

TABLE 2: Summary of CT Findings in 28 Patients with Infarctions in the Territory of the Anterior Choroidal Artery

Anatomic Distribution of the Lesions	Lacunar Infarctions (No. of Cases)	Total and Partial Nonlacunar Infarctions (No. of Cases)	Total Cases
Posterior limb of the internal capsule at midthalamic-pineal level			
Entered posterior limb	—	8	8
Posterior two-thirds	—	10	10
Middle third	1	—	1
Posterior third	6	3	9
Retrolenticular portion	—	16	16
Internal capsule at subthalamic level	1	11	12
Medial globus pallidus	—	6	6
Thalamus	—	5	5

other hand, the most constantly affected site was the posterior portion of the posterior limb of the internal capsule supplied by the deep penetrating arterioles.

It is interesting to note that in eight cases (one of these cases was associated with a large infarct in the territory of the middle cerebral artery), accounting for 28% of the 28 cases, the anterior third of the posterior limb of the internal capsule was also involved. This finding supports the hypothesis that the anterior choroidal artery may share in the vascularization of this capsular segment, usually supplied by the deep branches of the middle cerebral artery. A frequent finding was the involvement of the retrolenticular portion (57%), always associated with a lesion in the posterior third of the posterior limb of the internal capsule.

The incidence of infarction involving the internal portion of the globus pallidus was low (21%) and may suggest the possibility that the contribution of the anterior choroidal artery in this area is not constant. The possible reasons for this low incidence might be two. First, the lesion of the medial pallidus is small and consequently undetected on CT scan. Second, the medial pallidus may also be supplied by deep penetrating branches of the lenticulostriate vessels. This view is supported by the anatomic study of Percheron and Escourolle [13], who found in 96 cases of infarctions in the deep middle cerebral territory four cases with involvement of the internal portion of the globus pallidus. On the other hand, we have observed numerous cases with CT evidence of striatocapsular infarctions involving the entire globus pallidus.

The limited involvement of the lateral thalamus confirms also that the contribution of the anterior choroidal artery in the thalamic blood supply is very poor and accounts for individual variations.

Analyses of the concomitant vascular risk factors show the high incidence of hypertension (40.7%), diabetes mellitus (25.9%), and combined possible cardiac and carotid sources of emboli (29.6%). The significant incidence of a possible embolic source suggested that many of these cases had embolic origins.

The present study was performed exclusively on CT and substantiated by careful clinical examination. The vessel involved was usually a penetrating artery, and its small diameter did not permit visualization by angiography.

Pathologic confirmation is lacking; nevertheless, our data seem to be reliable since they are based on well-defined vascular topographic criteria and on retrospective clinical and CT studies [14].

REFERENCES

- Dietemann JL, Medjek L. Angiographie cérébrale. Berlin: Springer-Verlag, 1982
- Abbie AA. The clinical significance of the anterior choroidal artery. *Brain* 1933; 56:233-246
- Carpenter MB, Noback ChR, Moss ML. The anterior choroidal artery. *Arch Neurol Psychiatry* 1954; 71:714-722
- Truex C, Carpenter M. *Human neuroanatomy*. Baltimore: Williams & Wilkins, 1969:71-72
- Lazorthes G, Gouazé A, Salamon G. Vascularisation et circulation de l'encéphale. Paris: Masson, 1976:129-132
- Rhoton AL, Fujii K, Frodd B. Microsurgical anatomy of the anterior choroidal artery. *Surg Neurol* 1979;12:171-187
- Percheron G. Les artères du thalamus humain. Les artères choroidiennes. *Rev Neurol (Paris)* 1977;133:547-558
- Foix Ch, Chavany JA, Hillemand P, Schiff-Wertheimer S. Oblitération de l'artère choroidienne antérieure. Ramollissement cérébral, hémiparésie, hémianesthésie et hémianopsie. *Soc d'Ophthalmologie* du 30 mai, 1925
- Cambier J, Graveleau Ph, Decroix JP, Elghozi D, Masson M. Le syndrome de l'artère choroidienne antérieure. Etude neuropsychologique de 4 cas. *Rev Neurol (Paris)* 1983;139:553-559
- Damasio H. A computed tomographic guide to identification of cerebral vascular territories. *Arch Neurol* 1983;40:138-142
- Matsui T, Hirano A. *An Atlas of the human brain for computerized tomography*. Tokyo: Igaku-Shoin, 1978
- Pulicino P, Nelson RF, Kendall BE, Marshall J. Small deep infarcts diagnosed on computed tomography. *Neurology* 1980;30:1090-1096
- Percheron G, Escourolle R. Évaluation de la limite la plus médiale du "territoire profond" de l'artère cérébrale moyenne sur 96 cas de ramollissements. *Rev Neurol (Paris)* 1969;120:245-254
- Masson M, Decroix JP, Henin D, Dairou R, Graveleau Ph, Cambier J. Syndrome de l'artère choroidienne antérieure. Etude clinique et tomodensitométrique de 4 cas. *Rev Neurol (Paris)* 1983;139:547-552