

Are your **MRI contrast agents** cost-effective?

Learn more about generic **Gadolinium-Based Contrast Agents**.



FRESENIUS
KABI

caring for life

AJNR

The interventricular extension of choroid plexus papillomas.

K D Hopper, L C Foley, N L Nieves and J G Smirniotopoulos

AJNR Am J Neuroradiol 1987, 8 (3) 469-472

<http://www.ajnr.org/content/8/3/469>

This information is current as
of April 19, 2024.

The Interventricular Extension of Choroid Plexus Papillomas

Kenneth D. Hopper^{1,2}
 L. Christopher Foley³
 Nestor L. Nieves²
 James G. Smirniotopoulos^{4,1}

Four cases of choroid plexus papilloma extending through the foramen of Monro are presented. All four patients were evaluated by contrast-enhanced CT and two of these were also evaluated by neurosonography. No other intraventricular tumor commonly extends through a ventricular outlet. The radiographic demonstration of this extension of an intraventricular mass through the foramen of Monro, cerebral aqueduct, or foramen of Luschka or Magendie represents an ancillary diagnostic sign of choroid plexus papilloma.

Although the occasional interventricular extension of a choroid plexus papilloma through the foramen of Monro, cerebral aqueduct, or foramen of Luschka or Magendie has been well documented in the pathology literature [1-8], its demonstration by CT or sonography has been described only twice [9, 10]. We report here four additional cases of choroid plexus papilloma in which extension through the foramen of Monro was shown by CT and/or sonography. Demonstration by coronal CT, sonography, or MR imaging of this interventricular extension is an ancillary diagnostic sign of a choroid plexus papilloma.

Case Reports

Case 1

A 31-day-old girl presented with a 7-day history of rapidly increasing head circumference and elevated temperature. A spinal tap revealed markedly elevated CSF protein (510) and numerous white cells. Cultures, however, were negative. An axial CT scan showed a large, lobulated, radiodense mass in the body and trigone of the right lateral ventricle with marked enhancement after IV contrast. Direct coronal CT and sonographic studies showed the mass to extend through the foramen of Monro into the roof of the third ventricle (Fig. 1). At surgery, a right lateral ventricular choroid plexus papilloma was found, which extended into the third ventricle. The patient did well postoperatively.

Case 2

A 7-month-old girl presented with rapidly enlarging head circumference. An axial contrast CT scan showed a brightly enhancing homogeneous mass (Fig. 2A) in the third ventricle with severe dilatation of both lateral ventricles. Coronal CT and sonography (Fig. 2B) showed extension of this tumor through the foramen of Monro into the left lateral ventricle. This was demonstrated at surgery.

Case 3

A 7-year-old boy presented with a 10-day history of headache and vomiting. Early right papilledema was found on physical examination. A skull series demonstrated widening of the coronal suture. Contrast CT revealed a 1-cm enhancing lesion in the roof of the third ventricle with extension into the left foramen of Monro with resultant obstruction of the left lateral

Received July 29, 1986; accepted after revision October 8, 1986.

The opinions or assertions contained herein are the private views of the authors and are not to be construed as official or as reflecting the views of the Department of the Army, USUHS, or the Department of Defense.

¹ F. Edward Herbert School of Medicine, Uniformed Services University of the Health Sciences, 4301 Jones Bridge Road, Bethesda, MD 20012.

² Department of Radiology, Fitzsimons Army Medical Center, Aurora, CO 80045-5001. Address reprint requests to Maj. Kenneth D. Hopper.

³ Denver Children's Hospital, 1056 East 19th Ave., Denver, CO 80218.

⁴ Department of Radiologic-Pathology, Armed Forces Institute of Pathology, Washington, DC 20307.

AJNR 8:469-472, May/June 1987

0195-6108/87/0803-0469

© American Society of Neuroradiology

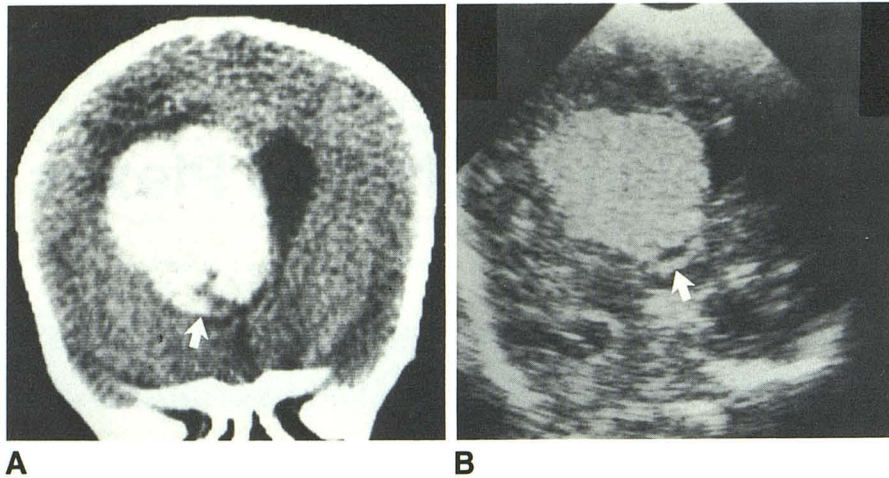


Fig. 1.—A, Direct coronal contrast CT scan shows right intraventricular radiodense mass with an inferior finger of tumor (arrow) extending through foramen of Monro.

B, Coronal sonogram through anterior fontanelle shows sonodense right ventricular mass with extension through right foramen of Monro (arrow).

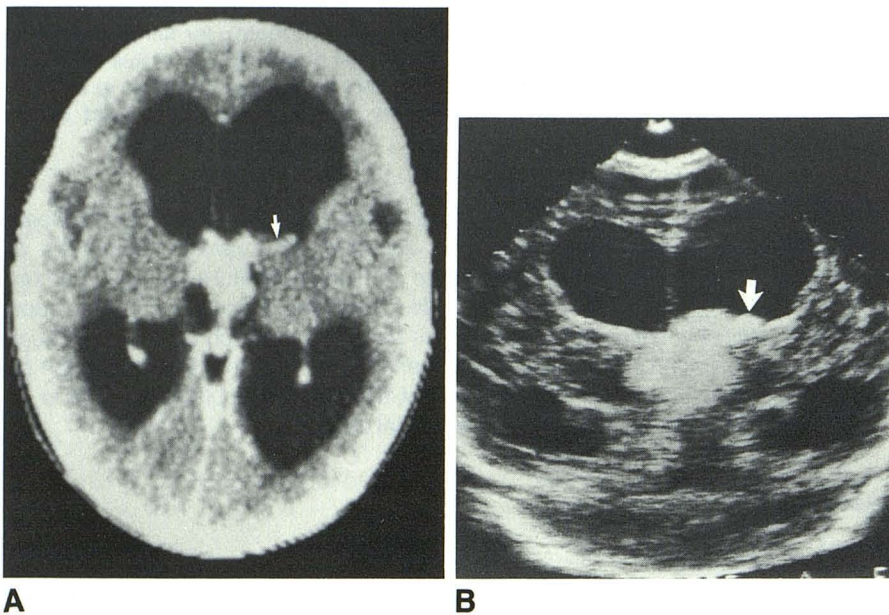


Fig. 2.—A, Contrast axial CT scan shows a third intraventricular enhancing tumor with extension through left foramen of Monro into body of left lateral ventricle (arrow).

B, Coronal sonogram through anterior fontanelle shows a third intraventricular sonodense mass extending through foramen of Monro into left lateral ventricle (arrow).

ventricle. This mass was subsequently removed at surgery without complication and pathologically confirmed to be a choroid plexus papilloma. The interventricular extension of this tumor was confirmed at surgery.

Case 4

A 2-year-old boy had a syncopal episode after minor trauma. On physical examination, the child's head was found to be large for age. A contrast CT scan showed a brightly enhancing mass in the body and atrium of the left lateral ventricle (Fig. 3A). On a lower section the tumor was seen to extend through the left foramen of Monro into the third ventricle (Fig. 3B). At surgery, a left ventricular choroid plexus papilloma with extension into the third ventricle was found.

Discussion

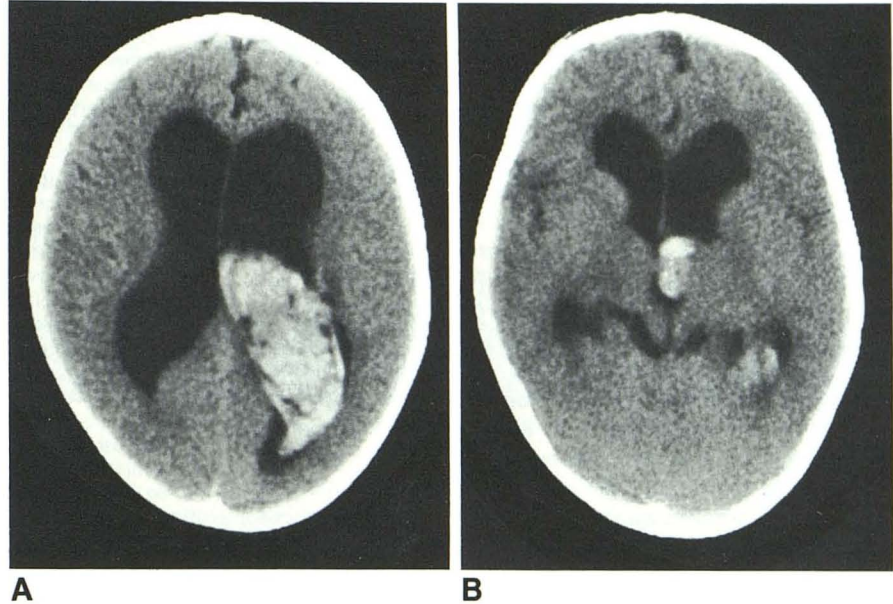
Choroid plexus papillomas are uncommon, lobulated, slow-growing intraventricular tumors, which constitute 0.4–0.6%

of all intracranial neoplasms [1, 11–13]. Thirty-nine percent of choroid plexus papillomas occur in the fourth ventricle, 10% in the third ventricle, and 43% originate in one of the lateral ventricles [11]. There is involvement of the cerebello-pontine angle in another 9%, either separately or via extension of a fourth ventricular choroid plexus papilloma through the foramen of Luschka [1–2]. Another 3.7% are reported to arise at multiple sites [11]. Extension of a lateral ventricular papilloma through the choroidal fissure into the quadrigeminal cistern and the contralateral ventricle has also been reported [1, 2]. Choroid plexus papillomas are usually histologically benign and present with the signs and symptoms of increased intracranial pressure, frequently with obstructive hydrocephalus.

Choroid plexus papillomas are more common in children, with a frequency of from 1.5% [14] to 6.4% [9] of all pediatric intracranial neoplasms. Although there is a predilection for the fourth ventricle in adults, the lateral ventricle, especially

Fig. 3.—A, Contrast axial CT scan shows enhancing mass in body and atrium of left lateral ventricle.

B, A lower section shows extension through left foramen of Monro into third ventricle.



the trigone, is more commonly involved in children, with a preference for the left side. Seventy percent of lateral ventricular choroid plexus papillomas occur in children [11]. In pediatric cases reported in a recent review of the literature, 4% were third ventricular, 80% occurred in one of the lateral ventricles, and 16% were in the fourth ventricle [9].

With the advent of neurosonography and cerebral CT, the preoperative diagnosis of choroid plexus papilloma has been dramatically improved. The unenhanced CT usually demonstrates a homogeneously dense, lobulated mass, which markedly enhances with the administration of IV contrast. Choroid plexus papillomas in children tend to be homogeneous, with inhomogeneity being a sign of carcinomatous change [9]. In adults, however, these tumors are usually inhomogeneous [12], probably secondary to cystic degenerative changes [15]. Tumoral calcification is uncommon, being reported in 4.1% [11] to 20.0% [16] of cases.

Choroid plexus papillomas are pliable, pedunculated tumors arising from a vascular stalk that remains attached to the normal choroid plexus. In the lateral ventricle this stalk is usually attached to the choroid plexus in the inferior portion of the trigone. In the third ventricle it is attached to the tela choroidea of the ventricular roof, and in the fourth ventricle it is attached posteriorly and inferiorly to the ventricular roof [11]. This vascular pedicle allows these tumors to move within the ventricle, unless secondary adhesions from tumoral hemorrhage have occurred. The mobility and softness of these tumors allow them to occasionally extend into and through the ventricular outlets, and they may even appear in an extraventricular location.

The differential diagnosis of intraventricular tumors is long and includes, in addition to choroid plexus papilloma, choroid plexus carcinoma, papillary ependymoma, metastases, xanthogranuloma of the choroid plexus, medulloblastoma, degenerative changes of the choroid plexus, and intraventricular meningioma. Metastases to the choroid plexus are rare, and

when they do occur usually involve multiple intracerebral sites.

Xanthogranuloma or cholesteatoma of the choroid plexus consists of small (1–2 cm), usually bilateral, deposits of cholesterol that are found incidentally at autopsy [17]. These deposits do not cause hydrocephalus, and their small size does not allow them to extend through a ventricular outlet.

Choroid plexus with degenerative changes may be difficult to differentiate histologically from a choroid plexus papilloma [17]. However, the involved choroid is not enlarged and there is no associated hydrocephalus or interventricular extension.

Choroid plexus carcinomas and papillary ependymomas invade the local ependyma and glial tissue. Although associated with hydrocephalus, they are not freely movable and would not be expected to extend through a ventricular outlet. Supratentorial ependymomas tend to have a much smaller intraventricular component than does the adjacent parenchymal invasion [18]. In addition, ependymomas tend to have an irregular margin, and the majority are childhood tumors of the fourth ventricle. Childhood choroid plexus papillomas usually occur in the lateral ventricles and are lobulated.

Medulloblastomas are common childhood tumors that originate almost entirely from primitive glial cells in the roof of the fourth ventricle and lie in the inferior vermis [19]. The age of their occurrence in the fourth ventricle and their involvement of the vermis help differentiate them from a choroid plexus papilloma. Medulloblastomas originate from the vermis rather than from the mobile choroid plexus, making interventricular extension unlikely. Spread of these tumors is usually due to invasion into the cerebellar hemispheres and by CSF seeding.

Intraventricular meningiomas are smooth, usually calcified, densely enhancing neoplasms occurring mostly in the lateral ventricular atria of young to middle-aged adults [18]. The hydrocephalus associated with these tumors tends to be entrapment of the occipital and/or temporal horns. Adult choroid plexus papillomas are lobulated and are uncommon in the lateral ventricles. CT and sonography should differen-

tiate normal choroid plexus in patients with a meningioma. Extension of an intraventricular meningioma through a ventricular outlet is very unlikely.

To our knowledge, there are only two case reports of the preoperative demonstration by CT or sonography of a choroid plexus papilloma extending through the interventricular foramen of Monro. In one case [10], sonography demonstrated extension of a third ventricular choroid plexus papilloma through the foramen of Monro into the right lateral ventricle in a 4-month-old girl. In the other case [9], CT demonstrated extension of a third ventricular choroid plexus papilloma through the foramen of Monro into the left lateral ventricle.

CT, especially in the coronal plane, as well as sonography (in patients whose fontanelles are open) are useful adjuncts in depicting and diagnosing this interventricular extension of choroid plexus papillomas between the lateral and the third ventricles. In the future, MR in the coronal plane will also prove useful in demonstrating interventricular extension via the cerebral aqueduct and from the fourth ventricle via the foramen of Luschka or Magendie. In addition, MR promises to be useful in demonstrating the CSF circulatory dynamics in these patients [20].

As demonstrated by the two previously reported cases [9-10] and by the four described here, the interventricular extension of an intraventricular tumor through the foramen of Monro, cerebral aqueduct, or foramen of Luschka or Magendie is a helpful diagnostic sign of a choroid plexus papilloma.

REFERENCES

- Bohm E, Strong R. Choroid plexus papillomas. *J Neurosurg* 1961;18:493-500
- Raimondi A, Gutierrez F. Diagnosis and surgical treatment of choroid plexus papillomas. *Child's Brain* 1975;1:81-115
- Safdari H, Bourbotte G, Frerebeau P, Castan P. Possible influence of cerebrospinal fluid pressure on the growth of a third ventricular choroid plexus papilloma. *Surg Neurol* 1984;22:243-248
- Jooma R, Grant N. Third ventricle choroid plexus papillomas. *Child's Brain* 1983;10:242-250
- Herren R. Papilloma of the choroid plexus. *Arch Surg* 1941;42:758-774
- Fincher E. Choroid plexus papilloma. *South Med J* 1934;27:667
- Bleyer A, Siebert W. A papilloma of the choroid plexus in an infant. *J Pediatr* 1936;8:193-196
- Van Wagenen W. Papillomas of choroid plexus; report of two cases, one with removal of tumor at operation and one with "seeding" of tumor in ventricular system. *Arch Surg* 1930;20:199-231
- Pascual-Castroviejo I, Villarejo F, Perez-Higueras A, Morales C, Pascual-Pascual S. Childhood choroid plexus neoplasms: a study of 14 cases less than 2 years old. *Eur J Pediatr* 1983;140:51-56
- Reddy P, Wild S, Hendry G. Ultrasonic diagnosis of a choroid plexus neoplasm in a child. *Br J Radiol* 1984;57:342-344
- Rovit R, Schechter M, Chodroff P. Choroid plexus papillomas: observations on radiographic diagnosis. *AJR* 1970;110:608-617
- Spallone A, Guidetti G, Mercuri S, Russo A, Ierardi A, Silipo P. Choroid plexus papillomas: neuroradiological diagnosis. *Neurochirurgia (Stuttg)* 1982; 25:165-169
- Stanley P. Papillomas of the choroid plexus. *Br J Radiol* 1968;41:848-857
- Heiskanen D. Intracranial tumors in children. *Child's Brain* 1977;3:69-79
- Gradin W, Tylon C, Fruin A. Choroid plexus papilloma of the third ventricle: case report and review of the literature. *Neurosurgery* 1983;12:217-220
- Kendall B, Reider-Grosswasser I, Valentine A. Diagnosis of masses presenting within the ventricles on computed tomography. *Neuroradiology* 1983;25:11-22
- Rubinstein L. Tumors of the central nervous system. In: *Atlas of tumor pathology*. Bethesda, MD: Armed Forces Institute of Pathology, 1972:257-262
- Dubois P. Brain tumors. In: Rosenberg R, ed. *The clinical neurosciences: neuroradiology*. New York: Churchill Livingstone, 1984:361-455
- Weller R, Swash M, McLellan D, Scholtz C. *Clinical neuropathology*. Berlin: Springer-Verlag, 1983:123-124
- Sherman J, Citrin C. Magnetic resonance demonstration of normal CSF flow. *AJNR* 1986;7:3-6