AJNR

Erroneous sonographic identification of fetal lateral ventricles: relationship to the echogenic periventricular "blush".

R A Bowerman and M A DiPietro

AJNR Am J Neuroradiol 1987, 8 (4) 661-664
http://www.ajnr.org/content/8/4/661

Erroneous Sonographic Identification of Fetal Lateral Ventricles: Relationship to the Echogenic Periventricular "Blush"

Richard A. Bowerman[1]
Michael A. DiPietro

We show, through correlation of fetal, neonatal, and necropsy brain sonography, that the three-parallel-echogenic-line configuration classically thought to represent fetal lateral ventricular margins on high axial images are actually extraventricular, lying within cerebral white matter. Accurate sonographic identification of fetal hydrocephalus is essential for appropriate patient management. Both qualitative and quantitative methods of determining ventriculomegaly have been described. The latter require identification of lateral ventricular walls for subsequent ventricular mensuration and comparison with hemispheric width. The parallel-line configuration, thought to represent ventricular margins, has been used for such measurements. We have—through careful fetal, neonatal, and necropsy specimen scanning in several planes—determined that the presumed ventricular wall echoes are actually extraventricular, arising from fibers within the cerebral white matter aligned perpendicular to the sonographic beam. This is identical to the etiology of the normal echogenic periventricular "blush" described in the neonate. Since these parallel echogenic lines do not represent actual ventricular margins, they should not be relied upon for the diagnosis of ventriculomegaly.

Sonographic diagnosis of early or subtle fetal ventriculomegaly is dependent on either qualitative evaluation of choroid plexus relationships to ventricular margins [1] or quantitative measures of ventricular size to hemispheric width, the ratio of which has been shown to decline throughout gestation [2–5]. Two echogenic intracerebral lines parallel to the interhemispheric fissure on high axial images through the fetal calvarium are generally identified as the lateral walls of the bodies of the lateral ventricles [2, 3, 5–8], which are used to determine a lateral ventricular width/hemispheric width ratio. However, we felt that these axial sections were too cephalad to image ventricles. Using current high-resolution real-time equipment, we confirmed that the two parallel lines thought to represent fetal ventricles were actually extraventricular. Correlative proof was derived from scanning neonatal and necropsy material. This paper illustrates the actual intracranial location of the echogenic structures previously labeled lateral ventricular margins and postulates their true anatomic origin.

Materials and Methods

All imaging was performed with commercially available equipment. A 3.5- or 5.0-MHz sector or linear transducer, depending on maternal body habitus and fetal orientation, was used for fetal evaluation. Neonates were scanned with a 5.0- or 7.5-MHz transducer, and the necropsy brain specimen was evaluated with both linear and sector 5-MHz transducers.

The standard section for biparietal diameter determination was obtained on initial examination of the fetus. Axial scanning was then performed more rostrally until three parallel echogenic lines were seen. The transducer was then rotated 90° to a coronal plane originating from the lateral aspect of the fetal calvarium ("lateral coronal" scan). When fetal position permitted, the transducer was then advanced, while maintaining a coronal plane, as far as possible toward the vertex ("angled coronal" scans). At all times attention was directed to

Received November 18, 1986; accepted after revision February 9, 1987

[1] Both authors: Department of Radiology, University of Michigan Medical Center, B1D502/0030, 1500 E. Medical Center Dr., Ann Arbor, MI 48109-0030. Address reprint requests to R. A. Bowerman.

AJNR 8:661–664, July/August 1987
0195–6108/87/0804–0661

the correlative position of the three parallel lines in the various "coronal" images.

Standard neonatal transfontanelle coronal scans documented an echogenic projection extending at an approximately 45° angle superolaterally from the body of the lateral ventricle. The effects of varying the scanning angle on the position of this projection was observed while maintaining the transducer in a coronal plane and slowly sliding it off the fontanelle until the image was obscured by bone. The thickness of the overlying calvarium precluded adequate axial or "lateral coronal" imaging of the parallel lines under study.

Scanning of a term, fresh, necropsy whole brain specimen was performed in a phosphate buffer "water" bath via multiple planes, including axial, sagittal, and various coronal projections centered from the vertex (true coronal) to the lateral aspect of the brain. The sonographic appearance and location of the echogenic parallel lines as well as their anatomic relationships to ventricles and interhemispheric fissure were noted in all scanning planes.

Results

A typical example of the three-parallel-line configuration seen on high axial scans of a fetus is shown in Fig. 1A. The central echogenic line represents the interhemispheric fissure while the lateral lines have classically been labeled lateral ventricular margins. This type of image is obtainable from mid-second trimester until term, depending on fetal position and maternal body habitus. Significant refraction over the curved upper calvarium frequently precludes adequate visualization of the upper portions of fetal brain from which the three-parallel-line configuration is derived. A contrasting axial image through the actual lateral ventricles is shown in Fig. 1B. Note the nonparallel relationship of the true lateral ventricular walls to the midline echo. Imaging in the orthogonal "lateral coronal" plane clearly shows that the echogenic lines suspected of representing lateral ventricular margins are actually more planar in configuration and lie superior to the uppermost position of the ventricular body (Fig. 1C). In all instances where the three-parallel-line configuration has been seen, simple rotation to the "lateral coronal" plane has confirmed its extraventricular locus. An interesting phenomenon occurred when "angled coronal" images were obtained from different effective point sources over the fetal calvarium. The vertical orientation of the echogenic structures on "lateral coronal" scans gradually rotated toward or away from the midline, maintaining a constant perpendicular relationship to the axis of the sonographic beam. These findings indicate that no fixed, single anatomic structure is responsible for the parallel echogenic lines seen on fetal scanning.

Scans of the exposed necropsy brain were most revealing. All image patterns documented in the fetus were reproducible. The three-parallel-line configuration was easily seen (Fig. 2A), but the lateral echoes were not as compact and linear as represented on fetal studies. They no longer appeared to be the sharp linear structures that would be expected of ventricular margins. Rotation to the "lateral coronal" plane dramatically showed the echoes extending well past the ventricles into cerebral white matter (Fig. 2B). Without any intervening calvarium, unorthodox coronal scans were possible from multiple points over the convexities, confirming the shifting nature of the extraventricular echoes in a constant perpendicular relationship to beam axis (Fig. 2C). A true coronal image of the exposed brain showed a shift of the echoes to a 45° angle off vertical (Fig. 2D), identical in appearance to the normal periventricular blush seen in neonatal sonography (Fig.

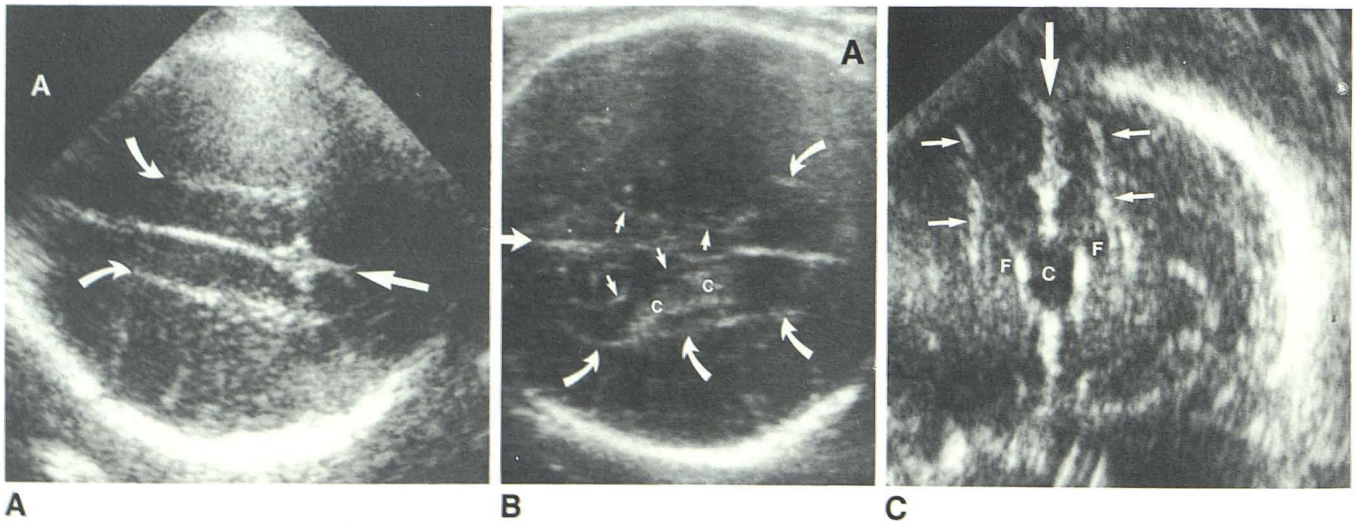

Fig. 1.—Fetus. Pseudoventricular three-parallel-line configuration.

A, High axial scan through calvarium delineates interhemispheric fissure (*straight arrow*) paralleled by two intracerebral echogenic linear structures (*curved arrows*). A = anterior.

B, Axial image through lateral ventricles. *Curved arrows* indicate lateral margins of lateral ventricles. *Short arrows* indicate visualized portions of medial ventricular walls. *Wide arrow* indicates midline echoes. Nondependent hemisphere is poorly imaged secondary to artifacts from calvarium. C = choroid plexus, A = anterior.

C, "Lateral coronal" image through frontal horns (F) and cavum septum pellucidum (C). *Large arrow* indicates echogenic midline interhemispheric fissure. The parallel, paramidline, echogenic linear structures shown in *A* are seen to extend from superolateral aspect of lateral ventricles well into brain substance beyond margins of ventricles (*small arrows*). These extraventricular echoes can also be seen to pass lateral to ventricles toward internal capsule. Refraction of beam from superior calvarium obscures some high cerebral detail. (Reproduced with permission from Bowerman RA, *Atlas of Normal Fetal Ultrasonographic Anatomy*. Copyright © 1986 by Year Book Medical Publishers, Inc., Chicago.)

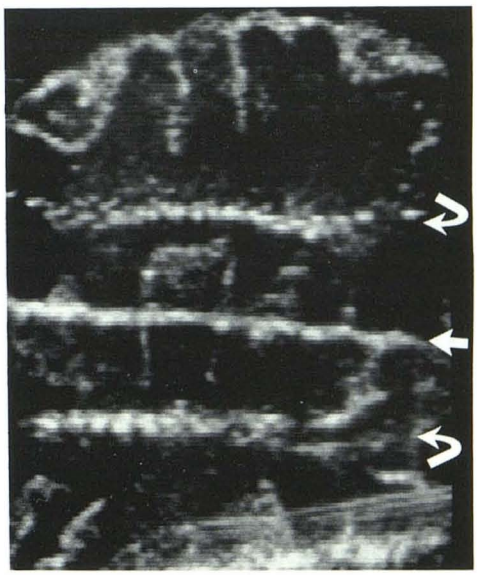

A

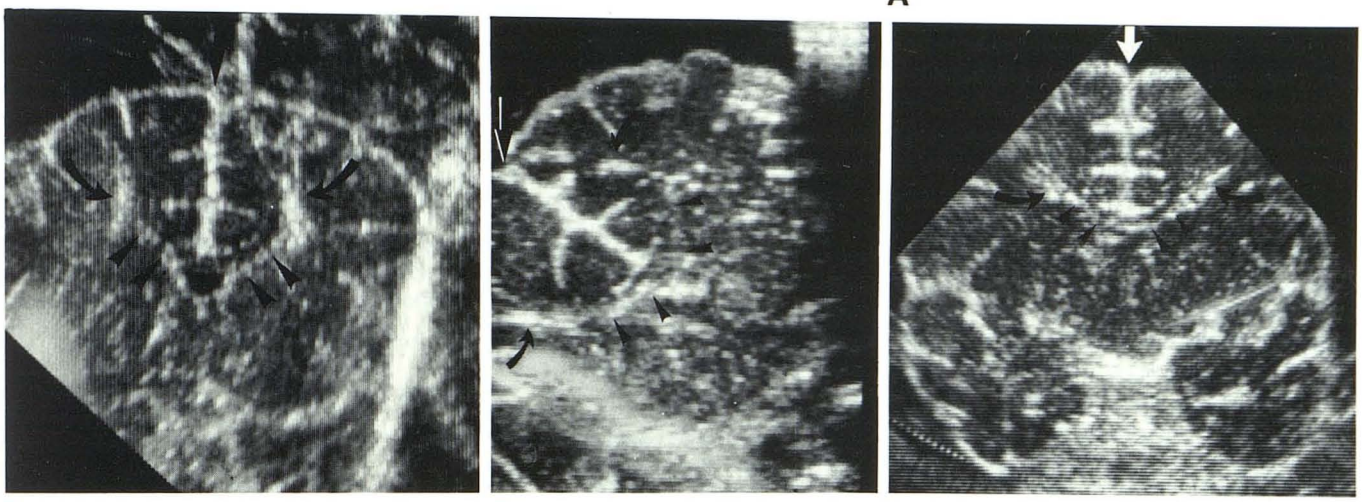

B C D

Fig. 2.—Necropsy correlates. *Straight arrows* mark interhemispheric fissure. *Arrowheads* indicate position of collapsed lateral ventricles below hypoechoic corpus callosum. *Curved arrows* delineate parallel echogenic lines representing white-matter fiber tracts.

A, High axial scan through brain reproduces the three-parallel-echogenic-line configuration. Echogenic sulci arising from interhemispheric fissure and cortical surface of brain are well seen.

B–D, "Lateral" (*B*), "angled" (C), and true (*D*) coronal images document extraventricular location of parallel echogenic lines and demonstrate their variable position dependent upon sonographic beam direction. With beam source perpendicular to interhemispheric fissure (*B*), the parallel lines are seen in a vertical orientation parallel to interhemispheric fissure. "Migrating" nature of echoes is apparent in *C*, where they are no longer vertical in orientation but point toward interhemispheric fissure on one side and away from fissure on the other, maintaining, however, a perpendicular relationship to the incident beam. With scan plane parallel to interhemispheric fissure (*D*), periventricular echoes have shifted to extend at 45° angles from superolateral aspect of lateral ventricles symmetrically into cerebral white matter. Note similarity to periventricular "blush" seen on normal coronal scan of neonate (Fig. 3).

3). This "blush" in the neonate is definitely periventricular and can be seen to pass lateral to the ventricle toward the internal capsule. "Angled coronal" imaging of the neonate also confirmed the shifting nature of these echoes, although not so clearly as in the necropsy specimen.

The planar and "migratory" nature of the periventricular echoes was readily demonstrated by sagittal scanning of the necropsy specimen. With the transducer positioned over the frontal lobe, a wide region of increased echoes corresponding to one of the parallel intracerebral "lines" was noted superior to the level of the lateral ventricular body. When the scanning plane originated from the vertex, the planar echoes superior to the ventricle could not be reproduced; however, similar regions were now noted anteriorly and posteriorly around the ventricular margins. These findings again suggest that the orientation of the sonographic beam to the target tissues is critical to imaging the echogenic structures seen within the cerebral white matter. No significant imaging differences were noted between sector and linear probes in any of the major findings described here.

Discussion

Hydrocephalus is the most common sonographically identified fetal CNS abnormality. While moderate-to-marked ventriculomegaly is not a difficult sonographic diagnosis, early or subtle changes may lead to great diagnostic consternation. Recognition of early ventriculomegaly can greatly effect subsequent patient management, such as the need for follow-up studies, potential termination procedures, or even fetal interventional surgery. Clearly, accurate diagnosis of ventricular enlargement is dependent upon identification of the true ventricular margins. Currently available high-resolution equipment can often define specific ventricular anatomy, which can be examined for signs of enlargement. The three-echogenic-parallel-line configuration said to represent ventricular walls can be seen in most obstetrical patients if the fetal orientation is appropriate and there is no obscuration of intracranial anatomy secondary to refraction from the calvarium as it curves superiorly. Since this pattern can be readily produced, a mistaken impression that the lateral parallel lines represent

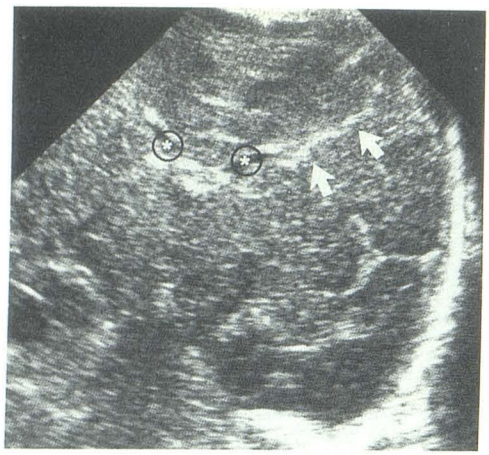

Fig. 3.—Neonate. Periventricular "blush." Angled coronal scan through anterior fontanelle shows normal echogenic periventricular "blush" (*arrows*) within cerebrum adjacent to ventricle (*asterisks*). Note inferior extension lateral to ventricle toward internal capsule. Echogenic "blush" could be shifted by changing transducer position over fontanelle as with fetus and necropsy specimen.

ventricular margins could lead to both false positive and false negative errors in the diagnosis of hydrocephalus. We have demonstrated that these echogenic structures are not of ventricular origin, and hence, it is inappropriate to apply a measurement based on them to the diagnosis of hydrocephalus. Possibly, the position of these structures superior to the ventricles reflects changes in ventricular size, although the sensitivity and reliability of such change would be suspect. Their clear positional variations with beam orientation may also reflect nonuniformly upon ventricular enlargement.

There is no apparent structure or interface on evaluation of gross anatomic sections that corresponds to the supraventricular echogenic lines. The "mobility" of the echoes in different scan planes also suggests an origin other than a large fixed structure such as a ventricle. However, fiber tracts within the white matter course in a fan-shaped distribution from the internal capsule through the corona radiata to gray matter distributed over the entire convexity. Bundles of these fibers, when oriented in a plane perpendicular to the sonographic beam, probably cause the observed echoes. Moving the transducer causes specular reflections from other fiber groups in the "fan," causing the "migration" of the echogenic lines.

DiPietro et al. [9] have shown through extensive evaluation of neonatal sonograms and correlative necropsy specimens that increased echoes in the peritrigonal region (peritrigonal "blush") are due to parallel fibers within the white matter imaged perpendicular to the sonographic beam. This phenomenon is confirmed by our scanning of the fresh brain specimen. The periventricular "blush" shifted away from the peritrigonal region on sagittal images as the transducer was moved posteriorly off the "anterior fontanelle." the "blush" continued to be greatest where the white-matter tracts were perpendicular to the scan plane. We postulate that the lateral components of the three-parallel-line configuration are due to the same phenomenon, since considerable variation in the position of the echoes can be defined in the coronal plane, corresponding not to a fixed structure but rather to the variable position of fiber tracts arising from the cortex and converging as the corona radiata toward the internal capsule. In both neonates and the necropsy specimen, the echoes course lateral to the body of the ventricle as one would expect of fibers passing to the internal capsule. An exquisite anatomic study by Naidich et al. [10] documented the echogenic nature of cerebral white matter as compared with gray matter and showed echogenic fibers coursing through the corona radiata/pes corona radiata toward the internal capsule similar in appearance to our coronal images. They also speculated that a demonstrated variability in the echogenicity of white matter within a homogeneous structure is probably due to the angle of incidence of the sonographic beam relative to the orientation of the fiber tracts.

Artifacts are considered unlikely causes of the fetal pseudoventricular echoes. The majority of fetal intracranial artifactual echoes are curvilinear, related to reverberation from the overlying calvarium [11]. Examination of our specimen without a calvarium demonstrated findings identical to those through an intact fetal/neonatal skull, excluding bone as a source of the echoes. Linear artifacts are generally noted in only one hemisphere as opposed to the bilaterality of the three-parallel-line configuration.

In conclusion, our findings show that the apparent lateral "ventricular" margin in the fetus and the normal periventricular echogenic "blush" in the neonate are in fact due to the same phenomenon. Both are created by the interface of the sonographic beam with fiber tracts radiating through cerebral white matter when they are at right angles to each other. Since the white-matter tracts are oriented in a radial fashion, the angle of scanning determines where the beam and fibers intersect at right angles, and hence where the periventricular echogenic line or "blush" will appear. Limited sonographic access to the brain in vivo usually results in these echoes being apparent only in certain locations, hence appearing to represent particular fixed structures such as ventricular margins.

REFERENCES

1. Chinn DH, Callen PW, Filly RA. The lateral cerebral ventricle in early second trimester. *Radiology* **1983**;148:529–531
2. Denkhaus H, Winsberg F. Ultrasonic measurement of the fetal ventricular system. *Radiology* **1979**;131:781–787
3. Johnson ML, Dunne MG, Mack LA, Rashbaum CL. Evaluation of fetal intracranial anatomy by static and real-time ultrasound. *J Clin Ultrasound* **1980**;8:311–318
4. Hadlock FP, Deter RL, Park SK. Real-time sonography: ventricular and vascular anatomy of the fetal brain in utero. *AJR* **1981**;136:133–137
5. Pretorius DH, Johnson ML, Rumack CM. Fetal intracranial diagnosis. In: Rumack CM, Johnson ML. *Perinatal & infant brain imaging*. Chicago: Year Book Medical, **1984**:61–90
6. Hidalgo H, Bowie J, Rosenberg ER, Ram PC, Ford KL, Lipsit E. In utero sonographic diagnosis of fetal cerebral anomalies. *AJR* **1982**;139 143–148
7. Pasto ME, Kurtz AB. The prenatal examination of the fetal cranium, spine, and central nervous system. *Semin Ultrasound, CT, MR* **1984**;5:170–193
8. Jeanty P, Romero R. *Obstetrical Ultrasound*. New York: McGraw-Hill, **1984**:99–104
9. DiPietro MA, Brody BA, Teele RL. Peritrigonal echogenic "blush" on cranial sonography: Pathologic correlates. *AJNR* **1986**;7:305–310, *AJR* **1986**;146:1067–1072
10. Naidich TP, Gusnard DA, Yousezadeh DK. Sonography of the internal capsule and basal ganglia in infants: 1. Coronal sections. *AJNR* **1985**;6:909–917
11. Stanley JH, Harrell B, Horger EO III. Pseudoepidural reverberation artifact: a common ultrasound artifact in fetal cranium. *J Clin Ultrasound* **1986**;14:251–254