

Are your **MRI contrast agents** cost-effective?

Learn more about generic **Gadolinium-Based Contrast Agents**.



FRESENIUS
KABI

caring for life

AJNR

Duplication of cord laminae resulting in cord compression.

J D Cushman

AJNR Am J Neuroradiol 1988, 9 (2) 408-409

<http://www.ajnr.org/content/9/2/408.citation>

This information is current as
of April 18, 2024.

Duplication of Cord Laminae Resulting in Cord Compression

Congenital anomalies of the spine are not uncommon and are related to embryologic factors. This report presents a case of duplication of the laminae of a single thoracic vertebral segment that resulted in compression of the spinal cord. This is a rare anomaly. The literature contains only one similar case, which involved a cervical vertebra [1]. Other congenital duplications have been reported, but they involved either attempted duplication of all the spinal elements or of multiple vertebral levels [2, 3]. Defects of the posterior neural arch are more common than duplication, although both probably reflect an abnormality in the normal sequence of ossification.

Case Report

A 23-year-old man came to the outpatient clinic with a complaint of bilateral weakness of the lower extremities, paresthesias, and tremors of about 2 months' duration. He had had increasing difficulty in ambulation to the point of requiring a wheelchair. He also reported recent onset of urinary frequency and difficulty initiating micturition and defecation.

Physical examination revealed decreased motor strength of the muscles of the extremities bilaterally, with increased tone of the gastrocnemius muscles and a resting tremor. He had bilateral hyperreflexia, ankle clonus, and upgoing toes. Sensory changes ("feels like hot ice") were also present.

Myelography was performed immediately. A complete block was encountered at T10-T11 (Figs. 1A-1C). No conventional films were

available, but spot views were obtained during myelography. A sharply marginated osseous density was present inside the posterior elements (Figs. 1A-1C, *arrows*). CT showed severe spinal stenosis with cord compression due to a posterior, well-marginated osseous density representing the duplicated laminae (Fig. 1D). A bone scan confirmed its osseous nature.

At surgery, these findings were confirmed. After removal of the posterior elements, the duplicated laminae were found beneath them, and these were also removed to allow decompression. The patient regained some of his neurologic function postoperatively but is still undergoing rehabilitation therapy.

Embryology

In the sixth week of development, six centers of chondrification appear in the mesenchyme of the membranous vertebral column [4]. Two centers form the vertebral body, two centers arise lateral to the neural tube and form the neural arch and spinous process, and at the junction of the arch and body, extensions from two centers provide transverse processes.

Ossification of the neural arch occurs around weeks 8-10. Two primary ossification centers develop from the four chondrification centers of the posterior arch. Each center forms half of the neural arch, which includes a pedicle, lateral mass, and lamina. Posterior fusion of the arch occurs at 2 years of age. An error occurring in approximately the sixth to eighth week of development, during the

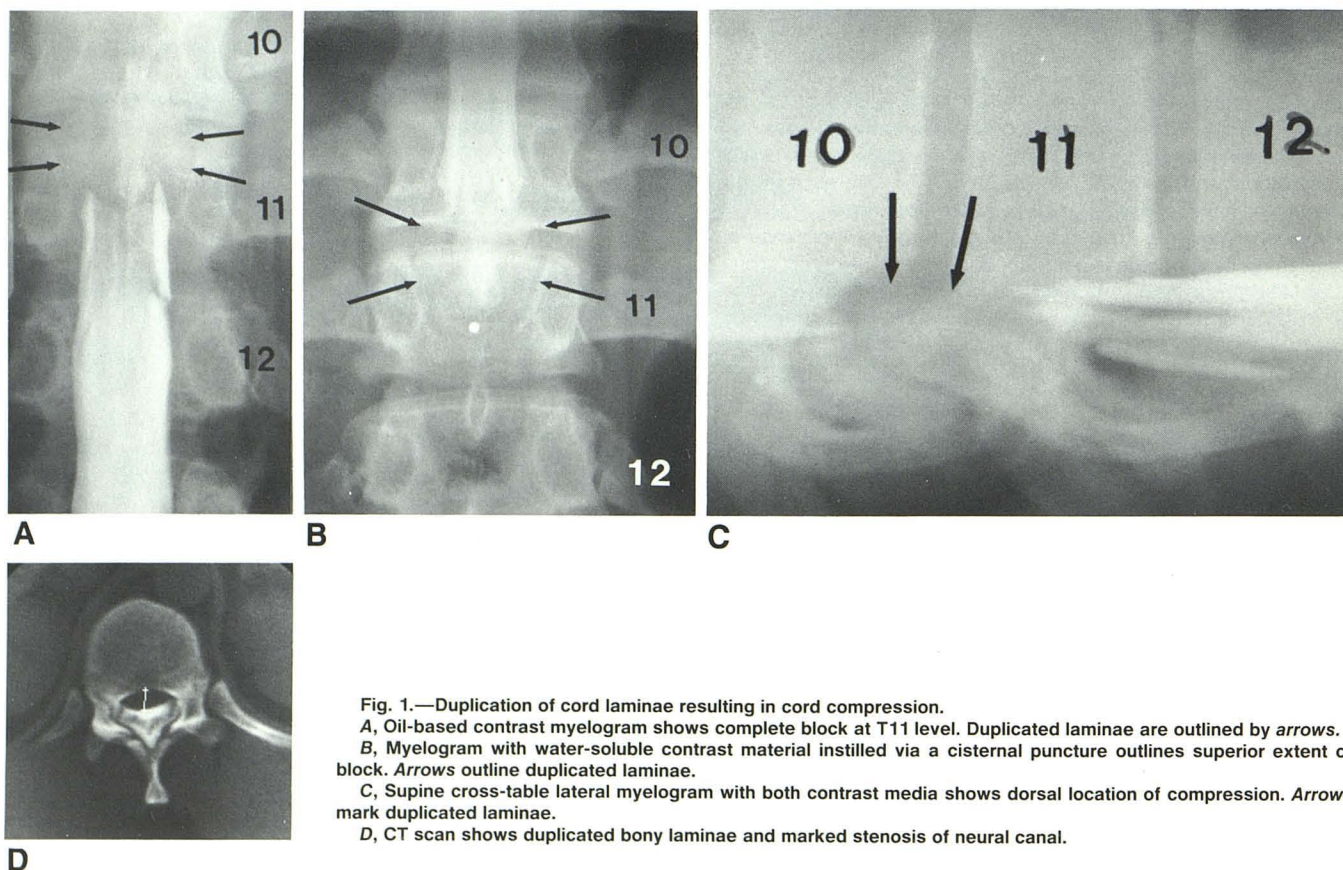


Fig. 1.—Duplication of cord laminae resulting in cord compression.
 A, Oil-based contrast myelogram shows complete block at T11 level. Duplicated laminae are outlined by *arrows*.
 B, Myelogram with water-soluble contrast material instilled via a cisternal puncture outlines superior extent of block. *Arrows* outline duplicated laminae.
 C, Supine cross-table lateral myelogram with both contrast media shows dorsal location of compression. *Arrows* mark duplicated laminae.
 D, CT scan shows duplicated bony laminae and marked stenosis of neural canal.

appearance of the chondrification and ossification centers, would seem to account for the unusual appearance in this case.

Differential Diagnosis

Calcific or ossific densities resulting in cord compression and myelopathy have been reported. Calcification of the posterior longitudinal ligament, either alone [5] or associated with diffuse idiopathic skeletal hyperostosis [6] can occur, but this is located anteriorly in the spinal cord, dorsal to the vertebral body. Calcification of the ligamenta flava may be extensive and may result in cord compression [7, 8]. This occurs posteriorly; however, it often has a beaklike or moundlike bony excrescence from the lamina [8] and is not so perfectly formed as in this case. Osteochondromas arising from the neural arch are asymmetric and masslike [9].

Discussion

The duplication of the laminae in this case is thought to be congenital, resulting in stenosis of the spinal canal. The patient had apparently compensated for it until a few months before admission. He related no history of significant trauma, although the severity of the stenosis suggests that a minor injury may have started the process.

Jeffrey D. Cushman
Grandview Hospital
Dayton, OH 45405

REFERENCES

1. Shapiro R. *Myelography*, 4th ed. Chicago: Year Book Medical, 1984:239
2. McKay DW, Nason SS. Congenital duplication of the spinal canal. *Spine* 1980;5(4):390-391
3. Kelly A, Towbin R, Kaufman R, Crawford A. Spine duplication. *Spine* 1985;10(1):15-18
4. Parke WW. Development of the spine. In: Rothman RH, Simeone FA, eds. *The spine*, 2nd ed. Philadelphia: Saunders, 1982:1-17
5. Ono M, Russell WJ, Sho K, et al. Ossification of the thoracic posterior longitudinal ligament in a fixed population. *Radiology* 1982;143:469-474
6. Cholankeril JV, Cenizal J, Ketyer S, Kessler M. Diffuse posterior hyperostosis of the cervical spine with cord compression: a Forestier (DISH) variant. *J Comput Assist Tomogr* 1983;7:171-174
7. Miyasaka K, Kaneda K, Ito, T, Tokei H, Sugimoto S, Tsuru M. Ossification of spinal ligaments causing thoracic radiculomyelopathy. *Radiology* 1982;143:463-468
8. Miyasaka K, Kaneda K, Soto S, et al. Myelopathy due to ossification or calcification of the ligamentum flavum: radiologic and histologic evaluations. *AJNR* 1983;4:629-632
9. Palmer FJ, Blum PW. Osteochondroma with spinal cord compression. *J Neurosurg* 1980;52:842-845