

Are your **MRI contrast agents** cost-effective?

Learn more about generic **Gadolinium-Based Contrast Agents**.



FRESENIUS
KABI

caring for life

AJNR

The CT and MR evaluation of lissencephaly.

S E Byrd, T P Bohan, R E Osborn and T P Naidich

AJNR Am J Neuroradiol 1988, 9 (5) 923-927

<http://www.ajnr.org/content/9/5/923>

This information is current as
of April 18, 2024.

The CT and MR Evaluation of Lissencephaly

Sharon E. Byrd¹
 Timothy P. Bohan²
 Robin E. Osborn^{1,3}
 Thomas P. Naidich^{1,4}

Lissencephaly is a rare congenital malformation of the brain that has characteristic radiographic and clinical findings. Fifteen cases of lissencephaly were studied with CT and/or MR, and a classification was developed based on these cases and the description of this abnormality found in the literature. These findings can be divided into two groups, primary and secondary. The primary findings consist of (1) a cerebral surface that is agyric or agyric with pachygyric areas, (2) a cerebral contour that is oval or "hourglass" due to lack of or incomplete opercularization of the brain, and (3) an abnormal gray-white-matter distribution in the cerebral hemispheres. The primary findings are necessary to make the diagnosis, which can be made with either CT or MR; however, MR provided better delineation than CT of the cerebral surface and contour as well as better gray-white-matter differentiation in the lissencephalic brains.

We believe MR is the technique of choice for evaluating patients with lissencephaly because it is safer and more versatile than CT and provides better delineation of the brains of children.

Lissencephaly is a rare congenital malformation of the brain that is seen in children. It is one of the entities of the migrational disorders, which are abnormalities of sulcation and neuroblast migration that occur in the developing brain during the stage of migration [1]. With high-resolution CT and MR imaging the radiologic spectrum of lissencephaly can be demonstrated. Our objective was to define and delineate the specific CT and MR findings in lissencephaly to correctly diagnose this abnormality.

Received September 11, 1987; accepted after revision February 4, 1988.

Presented in part at the annual meeting of the American Society of Neuroradiology, New York City, May 1987.

¹ Department of Radiology, Division of Neuroimaging, Northwestern University Medical School, Children's Memorial Hospital, 2300 Children's Plaza, Chicago, IL 60614. Address reprint requests to S. E. Byrd.

² Departments of Pediatrics and Neurology, Division of Pediatric Neurology, Northwestern University Medical School, Children's Memorial Hospital, Chicago, IL 60614. Present address: Departments of Pharmacology and Neurology, The University of Texas Health Science Center at Houston, 6431 Fannin, P.O. Box 20708, Houston, TX 77225.

³ Present address: Department of Radiology, Neuroimaging Division, Naval Hospital, San Diego, CA 92134.

⁴ Present address: Department of Radiology, Baptist Hospital of Miami, 8900 N. Kendall Ave., Miami, FL 33176.

Materials and Methods

Over a 1-year period at the Children's Memorial Hospital of Chicago, we evaluated 15 children with lissencephaly (Table 1). All of these children had CT studies of the brain on the GE 9800 CT scanner using a high-resolution technique and 3- or 5-mm slice thicknesses with contiguous table movements. Nonenhanced axial CT scans were obtained in all our patients; half of them also had a contrast-enhanced CT study with Omnipaque 300 (iohexol) given IV 3 ml/kg (maximum, 100 ml).

Seven of our patients also had MR scans of the brain. The scans were obtained with a Philips and/or Elscint MR scanner operating at 0.5 T with 5- or 8-mm slice thicknesses. Spin-echo pulse sequences, 500–750/30 (TR/TE), were performed. T2-weighted MR images were not obtained because we were only evaluating anatomic structures in these brains. The images were obtained in the axial, coronal, and sagittal planes in all of the patients.

Sedation was necessary in all cases for CT and MR. Chloral hydrate 50–100 mg/kg was given, with a maximum of 2 g. The patients were monitored with a pulse oximeter or cardiac/respiratory monitor during the CT study and with manual monitoring by a nurse in the magnet room during MR imaging.

The diagnosis of lissencephaly was made on the basis of the CT and/or MR studies in conjunction with the classic findings as described in the pathologic and radiologic literature and confirmed from autopsy findings in 30% of our cases [2–8].

TABLE 1: Profile of Patients with Lissencephaly

Lissencephaly Type: Subtype	No. of Cases	Age at Diagnosis	Gender	Presenting Signs	Radiographic Findings	Karyotype	Additional Information
I: Miller-Dieker	1	1 mo	M	Miller-Dieker facial features; opisthotonic posturing; omphalocele; microcephaly	CT positive for lissencephaly	Deletion of part of the 17th chromosome	Died at 6 months old from combination of cardiac/respiratory and neurologic problems; autopsy confirmed CT findings
II: Walker-Warburg	3	2 mo 5 mo 1 mo	M M F	Macrocephaly with hydrocephalus & delayed development	CT positive for lissencephaly in all cases; hydrocephalus in all; Dandy-Walker cyst with absence of corpus callosum in one and Dandy-Walker variant in one; MR of patient with Dandy-Walker variant confirmed CT findings	Normal in all	(1) 2-month-old patient died from combination of heart, renal, respiratory, & neurologic problems; autopsy confirmed MR & CT findings (2) 5-month-old patient died from failure to thrive & neurologic complications (3) 1-month-old patient alive at 4 months Hydrocephalus was shunted in all patients
III: Isolated lissencephaly	11	10: 6-20 mo; one: 6 yr	5 M 6 F	Hypotonia, failure to thrive, delayed development, hypertonia, seizures, microcephaly, mental retardation	CT positive for lissencephaly in all patients; MR in six patients also positive for lissencephaly; one patient had absence of corpus callosum; posterior fossa normal in all cases	Normal in all	Three patients lost to follow-up; other five patients alive & being followed, & symptoms are being treated medically; three patients died from failure to thrive and respiratory and neurologic complications

Results

The CT and MR findings in lissencephaly can be categorized into two types, primary and secondary (Table 2). Because lissencephaly is an abnormality of the cortex of the brain and primary sulci, the major findings are related to the cerebral surface, contour, and gray-white-matter distribution.

The cerebral surface consists of a completely smooth brain that is agyric or has areas of agyria with pachygyria (Figs. 1-3). The cerebral contour is oval or "hourglass" in configuration with shallow sylvian grooves (Figs. 1 and 2). The cortical/white-matter interdigitations are absent with increased gray matter of the cortex and sparse distribution of white matter throughout the brain (Figs. 1 and 2).

Secondary findings are seen in some cases of lissencephaly. The lateral ventricles usually are mildly dilated and may have a colpocephalic (localized dilatation of the posterior

aspect of the lateral ventricles) appearance (Fig. 2); or, rarely, hydrocephalus may be present. The corpus callosum usually is hypoplastic, but it may also be partially or, rarely, completely absent (Fig. 3). The posterior fossa may be normal or severely atrophic, or Dandy-Walker abnormalities may be present (Fig. 3).

Discussion

Of all the migrational disorders, lissencephaly carries the worse prognosis. *Lissencephaly* in strict terminology means agyria—complete absence of gyri of the brain. In fact, it is a spectrum of brain disease ranging from completely agyric brains to brains with a combination of agyric and pachygyric areas. *Pachygyria* means too few gyri, and the gyri that are present are broad-based, flat, thickened, and coarse [2, 3, 5, 8].

Lissencephaly is caused by a derangement, which may be genetic or chromosomal, that occurs during the later phase of the stage of migration in the developing brain of the fetus. The normal brain consists of a six-layer cortex with primary and secondary sulci and gyri. Children with lissencephaly have an abnormal four-layered cortex with total or near-total absence of both sulci and gyri (Fig. 4) [2, 3, 9–11].

For simplification, lissencephaly can be divided into three types. Patients with type I lissencephaly have one of several syndromes (Miller-Dieker, Norman-Roberts, or Neu-Laxova) with characteristic dysmorphic facial features and microcephaly. The patients are first diagnosed by the pediatrician

TABLE 2: Radiographic Classification of the Manifestations of Lissencephaly

Primary findings:	
Cerebral surface:	Agyria or agyria and pachygyria
Cerebral contours:	Oval or hourglass
	Shallow sylvian grooves
Gray- white-matter distribution:	Thickened cortex
	Loss of gray- white-matter interdigitation
	Abnormal gray- white-matter distribution with increased gray matter and decreased white matter
Secondary findings:	
Ventricle:	
Size:	Mild to severe dilatation
	Hydrocephalus
	Colpocephaly
Corpus callosum:	
	Hypoplastic
	Partially or completely absent
	Normal
Posterior fossa:	
	Varying degrees of atrophy of brainstem and cerebellum (mild to severe)
	Dandy-Walker anomalies
	Normal

or neurologist on the basis of their facial features. The prognosis is poor and most infants die at birth or within a year after birth. The symptomatology of these patients begins at birth and consists of hypotonia, which may progress to hypertonia and intractable seizures. The patients die from associated cardiac and/or respiratory problems or from a failure to thrive. Norman-Roberts and Neu-Laxova are autosomal-recessive disorders. Miller-Dieker, which is the most common of this group, results from deletion of part of the 17th chromosome (Fig. 5) [12–14].

The patients with type II lissencephaly (Walker-Warburg or cerebroocular muscular syndrome) have macrocephaly because of the associated hydrocephalus. They do not have any characteristic facial features but they have associated eye findings (retinal dysplasia) and congenital muscular dystrophy (patients with cerebroocular muscular syndrome). They may have posterior fossa abnormalities such as a Dandy-Walker cyst or posterior cephalocele. Their life expectancy is shorter than that of patients with type I because of the complexity of brain abnormalities. Death in these patients is from a failure to thrive due to the severe hypotonia, inability to suck or move, and intractable seizures [15–18].

Patients with type III lissencephaly (isolated lissencephaly and cerebrocerebellar lissencephaly) have hypotonia and microcephaly without any characteristic dysmorphic facial features. They develop hypertonia, seizures, and mental retardation. They apparently have autosomal-recessive disorders. Patients with the cerebrocerebellar subtype die almost immediately after birth, probably due to severe atrophy of the posterior fossa, which nullifies any brainstem reflexes. In contrast, patients with isolated lissencephaly have a normal posterior fossa and have the longest survival (to 6 years old) of all the lissencephalic patients [6].

The underlying problem in all these types is the lissencephalic brain, and the diagnosis can be made antemortem by CT and/or MR if the three primary findings of abnormal cerebral surface, contour, and gray- white-matter distribution are demonstrated. The brain should be totally smooth—

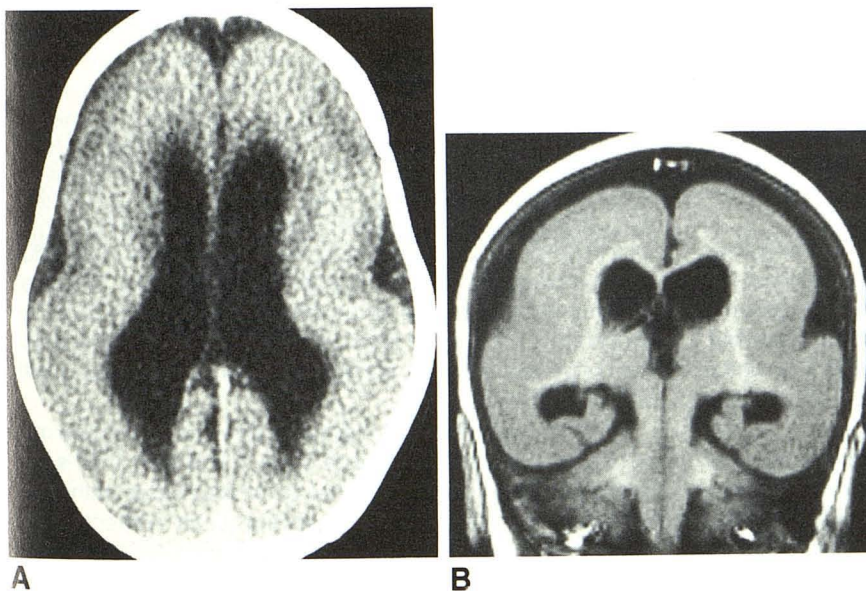


Fig. 1.—Axial enhanced CT scan (A) and coronal MR image, 500/30 (B). Completely agyric brain with oval configuration, shallow sylvian grooves, increased cortical gray matter and relatively small amount of white matter, and absence of normal cortical white-matter interdigitations.

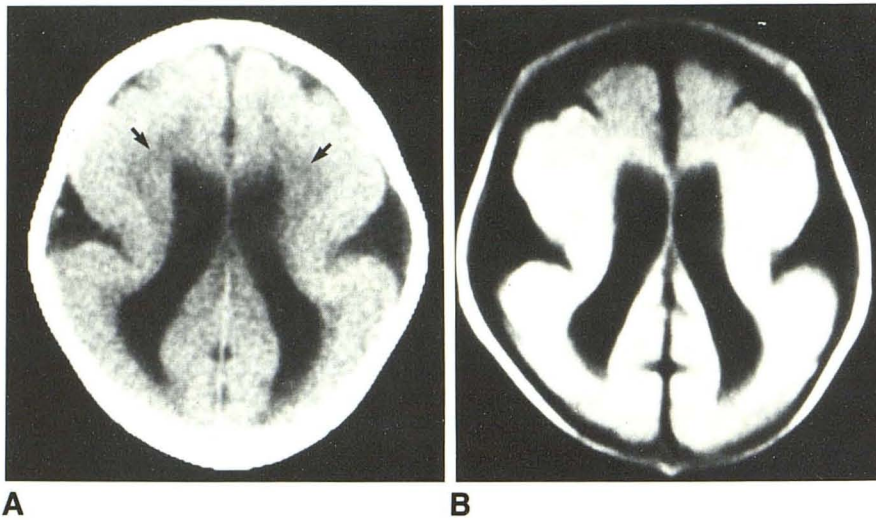


Fig. 2.—Axial CT scan (A) and MR image, 500/30 (B). Almost completely agyric brain with pachygyric areas involving frontal lobes, hourglass configuration with abnormal sylvian areas, increased cortical gray matter and decreased white matter (arrows), lack of cortical white matter interdigitations, and colpocephaly.

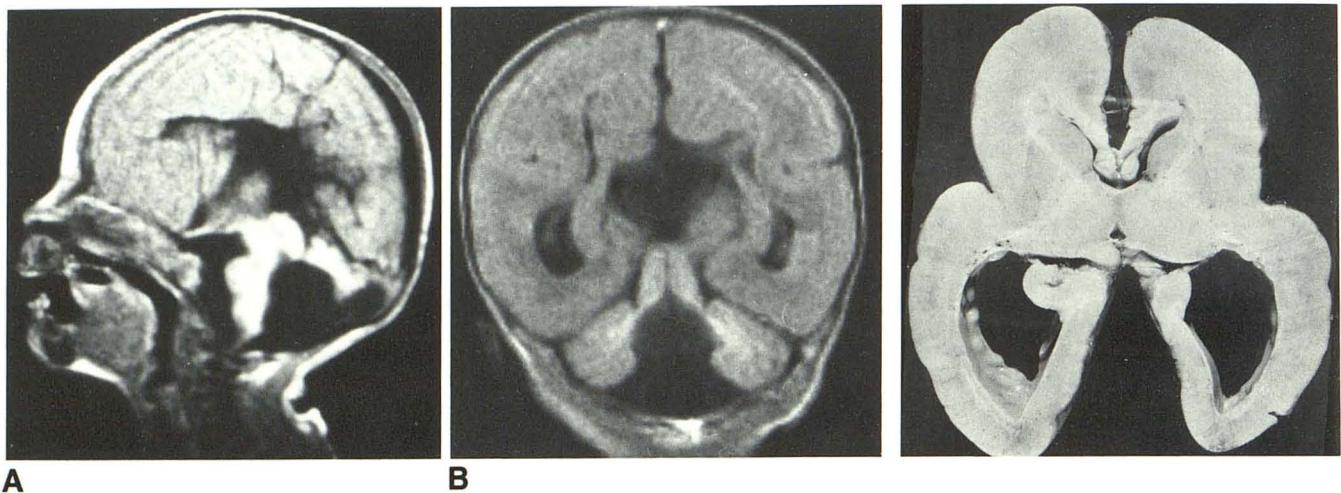


Fig. 3.—Sagittal (A) and coronal (B) MR images, 500/30, show almost completely agyric brain with absence of corpus callosum and Dandy-Walker cyst.

Fig. 4.—Autopsy specimen of brain section of lissencephalic patient. Agyric brain with hourglass configuration, colpocephalic ventricles, increased cortical gray matter with loss of cortical white-matter interdigitations, and decreased white matter (heterotopia seen along walls of lateral ventricles).

agyric, or agyric with pachygyric areas—to classify a patient as lissencephalic. If a brain consists of areas of pachygyria without areas of agyria, it is classified under a different syndrome of pachygyria [19].

The oval or hourglass configuration of the lissencephalic brain is due to lack of or incomplete opercularization of the brain with absent sylvian fissures or shallow sylvian grooves bilaterally. The gray-white-matter distribution is abnormal. There is loss of the normal cortical white-matter interdigitations with increased cortical gray matter and decreased white matter within the cerebral hemispheres.

The abnormality in the distribution and amount of gray and white matter in the cerebral hemispheres is an actual histologic increase in the number of gray-matter cells. The derangement is in the mechanism of the brain that controls the number of proliferating neuroblasts and the time at which they migrate

in groups of successive waves to form the normal six-layered cortex. In the lissencephalic brain, too many neuroblasts are produced and they migrate independently instead of in groups of successive waves. A four-layered cortical cerebrum is produced in which there is hypoplasia of the white matter due to hyperplasia of the gray-matter cells occupying the areas that normally would be occupied by white matter [5]. The secondary radiographic findings in lissencephaly do not make the diagnosis, but they commonly occur in association with the major findings.

In very young infants, the gray-white-matter interface may not be optimally evaluated with either CT or MR. This is due to the relatively sparse amount of white matter within the lissencephalic brain and the changing water content of the white matter in the maturing infant brain [20, 21]. In the majority of our cases the gray and white matter were deline-

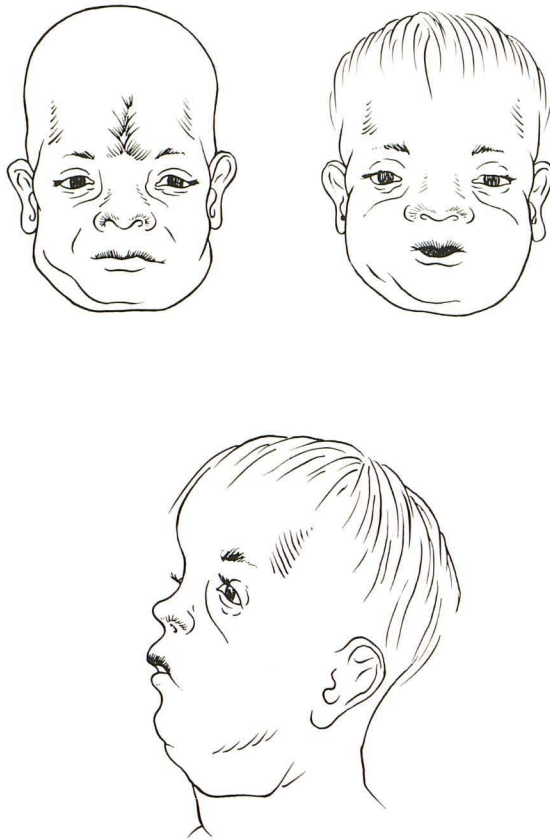


Fig. 5.—Classic dysmorphic facies of Miller-Dieker patient: microcephaly with bitemporal grooving, verticle midline wrinkling of forehead, anteverted nares, ear anomalies with low-set ears, and micrognathia.

ated, and MR was superior to CT. MR allowed for evaluation of our patients in all three projections without having to reposition the patient as in CT. The additional scan planes provided better evaluation of the cerebrum, midline structures (corpus callosal anomalies), and posterior fossa (Dandy-Walker cyst, atrophy).

We believe that MR is the technique of choice for evaluating patients with lissencephaly because it is not associated with ionizing radiation (as is CT), and it provides ease of acquisition of various projections and better delineation than CT of the brain in children. It is important to emphasize that the characteristic findings of lissencephaly can be seen on both CT and MR studies. Because some types of lissencephaly have a genetic or chromosomal basis, correct and timely diagnosis

is important to allow for accurate parental counseling with regard to both prognosis and risk for recurrence.

REFERENCES

1. DeMeyer W. Classification of cerebral malformations. *Birth Defects* 1971;81:78-93
2. Stewart RM, Richman DP, Caviness VS Jr. Lissencephaly and pachygyria. *Acta Neuropathol (Berl)* 1975;31:1-12
3. Sellinger K, Rett S. Agyria-pachygyria. *Neuropediatrics* 1976;7:1:66-91
4. Schenk VWD. Quantitative analysis in a case of lissencephalia. *Psychiatr Neurol Neurochir* 1966;69:297-303
5. Barth PG. Disorders of neuronal migration. *Can J Neurol Sci* 1987;14:1-16
6. Dobyns WB, Gilbert EF, Opitz JM. Further comments on the lissencephaly syndrome. *Am J Med Genet* 1985;22:197-211
7. Dobyns WB, McCluggage SW. Computed tomographic appearance of lissencephaly syndrome. *AJNR* 1985;6:545-550
8. Zimmerman RA, Bilaniuk LT, Grossman RS. Computed tomography in migratory disorders of human brain development. *Neuroradiology* 1983;25:257-263
9. Sidman RL, Rakic P. Neuronal migration with special reference to developing human brain. A Review. *Brain Res* 1973;62:1-35
10. Berry M, Rogers AW. The migration of neuroblasts in the developing cerebral cortex. *J Anat* 1965;99:691-709
11. Chi JG, Dooling EC, Gilles FH. Gyral development of the human brain. *Ann Neurol* 1977;1:86-93
12. Dobyns WB, Stratton RF, Parke JT, Greenberg F, Nussbaum RL, Ledbetter DH. Miller-Dieker syndrome: lissencephaly and monosomy y17p. *J Pediatr* 1983;April (102):552-558
13. Dobyns WB, Stratton RF, Greenberg F. Syndromes with lissencephaly: 1. Miller-Dieker and Norman-Roberts syndrome and isolated lissencephaly. *Am J Med Genet* 1984;48:509-526
14. Stratton RF, Dobyns WB, Airhart SD, Ledbetter DH. New chromosomal syndrome: Miller-Dieker syndrome and monosomy 17p13. *Hum Genet* 1984;67:193-200
15. Dobyns WB, Kirkpatrick JB, Hittner HM, Roberts RM, Kretzer FL. Syndrome with lissencephaly: Walker-Warburg and cerebro-ocular muscular dystrophy with a new syndrome with type II lissencephaly. *Am J Med Genet* 1985;22:157-195
16. Ragon RA, Chandler JW, Collie WR, Clarren SK, Moon J, Minkin SA. Hydrocephalus, agyria, retinal dysplasia, encephalocele (Hard ± E) syndrome: an autosomal recessive condition. *Birth Defects* 1978;14:68:223-241
17. Whitley CB, Thompson TR, Matri AR, Gorlin RJ. Warburg syndrome: lethal neurodysplasia with autosomal recessive inheritance. *J Pediatr* 1983;April (102):547-551
18. Towfighi J, Sassani JW, Suzuki K, Ladda RL. Cerebro-ocular dysplasia-muscular dystrophy (COD-MD) syndrome. *Acta Neuropathol (Berl)* 1984;65:110-123
19. Hanaway J, Lee SS, Netsky MG. Pachygyria: relation of findings to modern embryologic concepts. *Neurology* 1968;18:791-799
20. Holland BA, Haas DK, Norman D, Brant-Zawadzki M, Newton TH. MRI of normal brain maturation. *AJNR* 1986;7:201-208
21. McArdle CB, Richardson CJ, Nicholas DA, Mirfakhrae M, Hayden CK, Amparo EG. Development features of the neonatal brain. Part I. MR imaging. *Radiology* 1987;162:223-229