AJNR

MR imaging of spinal cord avulsion.

J M Mathis, J T Wilson, J W Barnard and M E Zelenik

AJNR Am J Neuroradiol 1988, 9 (6) 1232-1233
http://www.ajnr.org/content/9/6/1232.citation

MR Imaging of Spinal Cord Avulsion

John M. Mathis,[1] James T. Wilson,[2] John W. Barnard,[3] and Mary Ella Zelenik[1]

Spinal cord injury is a well recognized obstetrical complication of fetal hyperextension. It is most often seen in breech deliveries but is also found approximately 25% of the time in cephalic presentations. Myelography and CT have been the primary imaging methods used to demonstrate the cord defect. This case report describes the use of MR imaging in the evaluation of suspected avulsion of the spinal cord.

Case Report

The patient is a 5-year-old girl who was the product of a breech delivery complicated by assumed fetal hyperextension. Birth weight was 3.08 kg and apgar scores were normal. The infant demonstrated decreased movements of the lower extremities. Paraparesis was confirmed at 3 days of age. The subsequent medical course has included urinary incontinence and multiple bouts of pneumonia.

Physical examination revealed hypotonic upper extremities and flaccid paralysis of the legs. Sensory examination showed a consistent response above the C8–T1 region but no response below this level.

Plain radiographs were normal. MR was performed with a 1.5-T GE superconductive magnet. Sagittal images of 5-mm thickness were obtained. Strong T1 weighting was achieved with 300/25 (TR/TE). Spin-echo images were also obtained with 2000/30, 90 for mixed T1/T2 and T2 weighting. No contrast material or sedation was used. MR demonstrated total cord avulsion at C7–T1.

Discussion

Avulsion of the spinal cord during vaginal delivery is a well documented, although uncommon, obstetrical complication. Over 75% of these cases occur with breech presentation. There is a high association of fetal hyperextension in cases of cord injury. With fetal hyperextension and breech presentation, the incidence of avulsion of the cord is greater than 20% [1–3]. The cord injury usually occurs in the lower cervical or upper thoracic regions. The prevalence of injury to the lower cervical and upper thoracic area is believed to be related to the relative resistance to stretching of the cervical enlargement, leaving most of the stretch to be taken up by the more attenuated thoracic region [4]. The mechanism of injury with breech presentation is cord traction. The occurrence of transection of the cord during cephalic delivery involves torsion of the fetus in addition to traction, and the resulting injury is primarily in the upper cervical segments of the cord [5]. Recommendations as to how to avoid this injury generally include ascertaining the fetal attitude in all breech presentations radiographically or via sonography [1, 3], performing a cesarean section when a hyperextended fetus is found [1–3], and taking care when initiating rotational maneuvers when traction is being employed [5].

Until recently, imaging of the spinal cord has been limited to either CT or myelography [3, 6, 7]. The obvious disadvantages of these methods include the use of ionizing radiation and their invasive nature. Both examinations require the intrathecal administration of contrast material to visualize the cervicothoracic junction. Appropriate imaging sequence can be chosen with MR to examine directly the cord and surrounding structures without contrast or the associated radiation burden of conventional studies. Additionally, MR can provide better soft-tissue detail of surrounding structures as well as direct detection of primary cord abnormalities such as syrinx, atrophy, or abnormalities that change the water content of the cord.

This patient was imaged in the sagittal projection with sequences that develop heavily T1- or T2-weighted images. T1-weighted images are ideal for demonstrating the cord within the spinal canal as there is relatively little signal from the surrounding CSF (Fig. 1). The cord was clearly transected near the T1 vertebral body with the normal cervical enlargement of the cord well defined cephalad to the transection. There was no detected injury or residual deformity to adjacent vertebral elements. With the heavily T2-weighted images there was high signal from CSF, which allowed easy visualization of the dural margins and thecal sac (Fig. 2). As is characteristic of cord avulsion, there was also associated dural interruption. There was an approximately 1-cm separation of the attenuated adjacent ends of the thecal sac. Fibrous bands (scarring) could be seen bridging the defect on T2-weighted images. Myelography would show a complete block at this level.

Received April 7, 1987; accepted after revision July 29, 1987.

[1] Department of Radiology, Lewis-Gale Clinic, Inc., 1802 Braeburn Dr., Salem, VA 24153. Address reprint requests to J. M. Mathis.
[2] Roanoke Neurologic Associates, Roanoke, VA 24018.
[3] Medical College of Virginia, Richmond, VA 23298.

 0195–6108/88/0906–1232

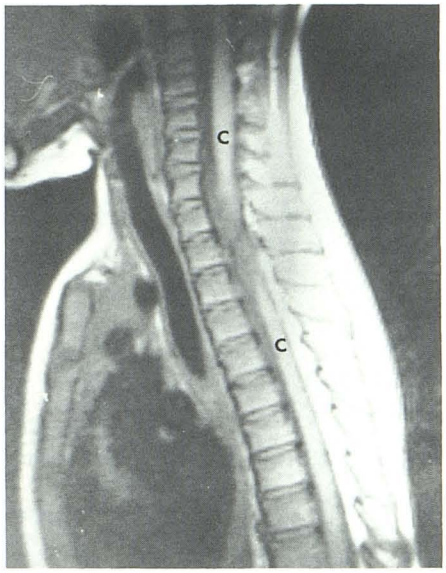

1

Fig. 1.—Strongly T1-weighted MR image (300/25) of lower cervical–upper thoracic region clearly shows spinal cord transection near T1 vertebral level. The cord (C) is well seen, as CSF has low signal with this echo sequence.

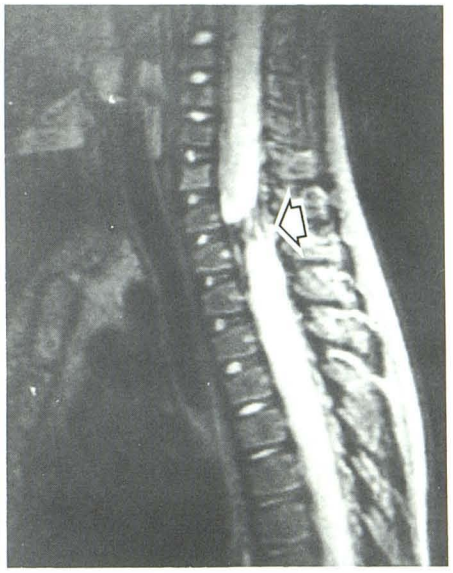

2

Fig. 2.—The *arrow* indicates site of dural interruption on this strongly T2-weighted MR image (2000/90). CSF is bright in this sequence and obscures the spinal cord.

This case demonstrates the remarkable ability of MR to image the spinal cord and surrounding structures without contrast material. This procedure should make future evaluation of the spinal cord simple in similar cases in which there is suspected perinatal trauma.

REFERENCES

1. Caterine H, Langer A, Sama JC, Devansan M, Pelosi MA. Fetal risk in hyperextension of the fetal head in breech presentation. *Am J Obstet Gynecol* **1975**;123:632–636
2. Daw E. Hyperextension of the head in breech presentation. *Br J Clin Pract* **1970**;24:485
3. Bresnan MJ, Abroms IF. Neonatal spinal cord transection secondary to intrauterine hyperextension of the neck in breech presentation. *Fetal Neonatal Med* **1974**;84:734–737
4. Crothers B. The effect of breech extraction upon the central nervous system of the fetus. *Med Clin North Am* **1922**;5:1287–1304
5. Shulman ST, Madden JD, Esterly JR, Shanklin DR. Transection of the spinal cord. *Arch Dis Child* **1971**;46:291–294
6. Hellstrom B, Sallmander U. Prevention of spinal cord injury in hyperextension of the fetal head. *JAMA* **1968**;204:107–110
7. Allen JP, Myers GC, Condon VR. Laceration of the spinal cord related to breech delivery. *JAMA* **1969**;208:1019–1922