

Are your **MRI contrast agents** cost-effective?

Learn more about generic **Gadolinium-Based Contrast Agents**.



**AJNR**

**Neuroimaging Clinics: 3.0T versus 1.5T  
Imaging, Vol. 16, No. 2**

*AJNR Am J Neuroradiol* published online 26 September  
2007

<http://www.ajnr.org/content/early/2007/09/26/ajnr.A0723.citation>

This information is current as  
of April 19, 2024.

## BOOK REVIEW

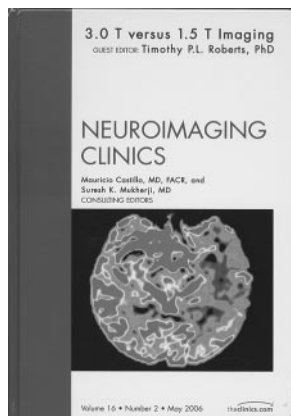
**Neuroimaging Clinics: 3.0T versus 1.5T Imaging, Vol. 16, No. 2**

T.P.L. Roberts, guest ed. Philadelphia: W.B. Saunders; 2006.

Since the Food and Drug Administration approved 3T MR imaging for clinical use in 2000, there has been a proliferation of 3T MR imaging systems throughout the economically developed world. The major, initial driving force behind this trend was, and still is, an attempt to better understand and scientifically map the workings of the normal human brain with functional imaging (FI). Another compelling force was to improve the detection of neurologic disorders with all available MR techniques, including conventional MR imaging, MR angiography (MRA), diffusion imaging including tensor imaging (DTI), perfusion imaging, MR spectroscopy, and FI. The purpose of this edition of *Neuroimaging Clinics* was primarily 2-fold: 1) to compare 3T with what has been the accepted criterion standard at 1.5T and 2) to inform readers of the current status and future potential of 3T MR imaging. Guest editor Timothy P.L. Roberts' stated intent also includes a discussion of "technologic considerations in hardware and methodology" in the development and use of the higher-field strength systems.

The book's overall organization is sound. The first chapter is entitled "3T Neuroimaging: Technical Considerations and Clinical Applications." It is designed as an introduction to the advantages and disadvantages associated with increasing B<sub>0</sub> to 3T. It also provides a helpful, succinct synopsis of the "guts" of evaluation of the central nervous system at 3T that is subsequently provided in much greater detail in the chapters that follow. An example of the value of the first chapter is its use of same-patient comparison images to illustrate that a half dose of gadolinium (0.05 mmol/kg) at 3T produces the same conspicuity of enhancement in a tumor as a full dose at 1.5T because of a combination of increased signal-to-noise (SNR) and prolonged T<sub>1</sub> relaxation time (suppression) of background tissue at the higher-field strength.

The second and third chapters are devoted to direct clinical comparisons of 3T versus 1.5T for pediatric brain imaging and for the spine. Both chapters provide salient facts on the differences between 3T and 1.5T while discussing their individual experiences with 3T imaging in their respective areas. The chapter on the pediatric brain contains numerous excellent same-patient comparison images displaying the improved clarity of pathologic processes at 3T compared with 1.5T. In some patients, the comparison has provided additional valuable clinical information such as demonstrated tumoral extension into the Meckel cave in 1 patient. The authors appropriately note



that metallic devices still have not been safety-tested at the higher-field strength. The chapter, perhaps inadvertently, implies that patients with metal (eg, dental braces) should not be imaged at 3T because of exacerbated degradation of images related to increased susceptibility artifacts at higher-field strength when, in fact, multiple imaging parameters can be altered. For example, the bandwidth and echo-train length can be increased, and section thickness, echo time, and parallel imaging (PI) can be decreased, to mitigate both loss of signal intensity and geometric distortion-increased susceptibility at higher-field strength. The chapter on the spine includes some excellent examples of the relative strength of T<sub>2</sub> turbo spin-echo pulse sequences at 3T relative to 1.5T. Unfortunately, its authors detail their experiences and preferences with various T<sub>1</sub>-weighted pulse sequences for spinal cord definition at 3T and for relative conspicuity of enhancement in the spine at 3T versus 1.5T without showing examples supporting either of their conclusions.

The overall flow of the book could have been slightly improved if the next chapter were the comparison of "3T versus 1.5T: MR Angiography of the Head and Neck" rather than "3T versus 1.5T: Coil Design. Similarities and Differences." The chapter on MRA is superbly written with excellent discussions of the various techniques for time of flight, phase contrast, and contrast-enhanced and plaque imaging, with clearly illustrated images pointing out clinically important differences in the quality between the 2 field strengths for MRAs of the head and neck. The chapter on coil design is extremely relevant to this edition, particularly because a significant issue regarding the acceptance of 3T as a whole-body imaging tool has been the inability of the manufacturers of 3T MR imaging systems to deliver the full complement of requisite surface coils. The authors provide insight into this problem by discussing the added difficulties for coil performance at 3T, such as greater coupling between coil elements and the use of low-impedance preamplifiers to remedy this problem. There is also an added safety concern for patients at 3T because of the significant increase in the amplitude of voltage in the additional cables necessary for successfully making coils for 3T. The chapter also discusses the benefits associated with multichannel, phased-array, transmit-receive coils at 3T to both maximize the benefit from the increased SNR at the higher-field strength and to address one of the major challenges associated with moving from 1.5T to 3T—increased energy deposition (specific absorption rate, or SAR) in body tissues. The chapter on PI 3T appropriately promulgates the synergistic relationship between the higher-field strength MR imaging systems and PI. It is concise and thorough in explaining just how important PI is for 3T in ameliorating many negatives associated with imaging at higher-field strength. These techniques include decreasing SAR and susceptibility while allowing the imager to maintain realistic scan times, and benefiting from the added SNR with increased matrices and thinner sections.

The chapter on FI is particularly important for this issue because the increased SNR at 3T has a major impact on improving the BOLD (blood oxygen level-dependent) signal intensity resulting in increased contrast-to-noise (CNR) between activated brain tissue and background. This has resulted in the detection of supplementary areas of activation not seen at 1.5T, which thus provides a major impetus to go to 7T and

higher for brain evaluation at multiple research facilities. The chapter on MR spectroscopy and spectroscopic imaging is excellent in discussing  $^1\text{H}$  spectroscopy and points out the benefits of 3T with both better peak quantification because of improved SNR and improved peak separation because of the doubling of chemical shift by increasing from 1.5 to 3T. By adding more about multinuclear spectroscopy at 3T such as sodium imaging for differentiating live and dead tissue and  $^{31}\text{P}$  for psychiatric disorders, the authors would have made their chapter much more effective. The chapters on arterial spin-labeling (ASL) and diffusion tensor imaging are both well written, well illustrated, and are important topics for this book. In particular, ASL benefits dramatically because it is basically a signal intensity-deprived technique. By going to higher-field strength, this technique may obtain wider clinical use for perfusion studies. The chapter on stroke imaging at 3T provides a thorough and detailed discussion of stroke imaging and treatment and the value of MR imaging in the assessment

of stroke, but it is somewhat sparse in clinical data when comparing the 2 field strengths. Chapters on the adult brain, advanced spine imaging, and the economics of 3T versus 1.5 would have added to the value of this book.

This edition of *Neuroimaging Clinics: 3.0T versus 1.5T Imaging* provides a useful base of knowledge and is an excellent source of reference for all radiologists who are (or will be) using 3T MR imaging for evaluating patients with neurologic disorders. For this reason alone, I strongly recommend this work. It will help residents, fellows, and practicing radiologists and neuroradiologists gain an overall understanding of the benefits and challenges that occur when increasing the B0 from 1.5 to 3T. A revisit of this topic is strongly recommended after sufficient time elapses when a larger clinical data base is available that will compare same-patient scans at both field strengths to adequately determine whether the differences will affect patient treatment and outcomes.

DOI 10.3174/ajnr.A0723