

Are your MRI contrast agents cost-effective?

Learn more about generic Gadolinium-Based Contrast Agents.



FRESENIUS
KABI

caring for life

AJNR

**Diffusion Tensor MR Imaging Reveals
Persistent White Matter Alteration after
Traumatic Brain Injury Experienced during
Early Childhood**

W. Yuan, S.K. Holland, V.J. Schmithorst, N.C. Walz, K.M. Cecil, B.V. Jones, P. Karunanayaka, L. Michaud and S.L. Wade

This information is current as of April 16, 2024.

AJNR Am J Neuroradiol published online 28 September 2007

<http://www.ajnr.org/content/early/2007/09/28/ajnr.A0698.citation>

ORIGINAL
RESEARCH

W. Yuan
S.K. Holland
V.J. Schmithorst
N.C. Walz
K.M. Cecil
B.V. Jones
P. Karunanayaka
L. Michaud
S.L. Wade



Diffusion Tensor MR Imaging Reveals Persistent White Matter Alteration after Traumatic Brain Injury Experienced during Early Childhood

BACKGROUND AND PURPOSE: Diffusion tensor imaging (DTI) can noninvasively quantify white matter (WM) integrity. Although its application in adult traumatic brain injury (TBI) is common, few studies in children have been reported. The purposes of this study were to examine the alteration of fractional anisotropy (FA) in children with TBI experienced during early childhood and to quantify the association between FA and injury severity.

MATERIALS AND METHODS: FA was assessed in 9 children with TBI (age = 7.89 ± 1.00 years; Glasgow Coma Scale [GCS] = 10.11 ± 4.68) and a control group of 12 children with orthopedic injuries without central nervous system involvement (age = 7.51 ± 0.95 years). All of the subjects were at minimum 12 months after injury. We examined group differences in a series of predetermined WM regions of interest with *t* test analysis. We subsequently conducted a voxel-wise comparison with Spearman partial correlation analysis. Correlations between FA and injury severity were also calculated on a voxel-wise basis.

RESULTS: FA values were significantly reduced in the TBI group in genu of corpus callosum (CC), posterior limb of internal capsule (PLIC), superior longitudinal fasciculus (SLF), superior fronto-occipital fasciculus (SFO), and centrum semiovale (CS). GCS scores were positively correlated with FA in several WM areas including CC, PLIC, SLF, CS, SFO, and inferior fronto-occipital fasciculus (IFO).

CONCLUSION: This DTI study provides evidence that WM integrity remains abnormal in children with moderate-to-severe TBI experienced during early childhood and that injury severity correlated strongly with FA.

Traumatic brain injury (TBI) is the leading cause of acquired disability in children resulting in significant deficits in cognition, behavior, and social development, as well as impairments in school performance and academic achievement.¹⁻³ Little is known about the changes in brain structure, chemistry, and organization resulting from TBI in children, particularly for those injured at an early age who may be more vulnerable to alterations in the course of brain maturation. After TBI, damage to the brain is often found in gray and white matter (WM) at the site of impact and also on the contralateral side. WM tracts are vulnerable to the axonal stretching and shearing associated with diffuse axonal injury occurring particularly in the corpus callosum (CC), brain stem, and subcortical WM regions. Neuropathologic studies of TBI in adults⁴⁻⁶ support the idea that wallerian degeneration leads to axonal collapse, myelin breakdown, and disconnection effects. A growing body of data suggests that TBI in young children results in different and potentially more severe sequelae than is

the case for adults or older children.⁷⁻¹⁰ Unfortunately, standard approaches for assessing injury severity at the time of injury (CT scans and Glasgow Coma Scale [GCS] scores) lack sensitivity to subtle WM changes, thus making it difficult to identify those children who are likely to have longer-term deficits. Quantitative MR imaging studies in both children and adults have documented reduced CC volume and increased ventricle-to-brain-volume ratios after moderate-to-severe TBI.¹¹⁻¹³ However, for less severe injuries in which conventional MR imaging underestimates, newer imaging techniques, such as diffusion tensor imaging (DTI), may provide more sensitive and predictive indices of long-term WM alteration after TBI in children.

DTI is an advanced MR imaging technique that can detect in vivo anisotropic diffusion properties in WM. Fractional anisotropy (FA) is a diffusion parameter that quantifies the degree of directionality of diffusion. FA in normal WM falls within an established range¹⁴⁻¹⁹ determined by factors such as axonal attenuation and packing, the thickness of the axon and axonal membrane, the thickness of the myelin sheath, and the relative membrane permeability to water. In recent years, DTI has been used to characterize the extent of diffuse axonal injury after TBI in adults.²⁰⁻²⁴ These studies documented reductions in FA both acutely²⁰ and over time, particularly in the CC, internal capsule (IC), and centrum semiovale (CS),^{22,23} sometimes with significant correlation to injury severity.²¹


Here we describe a preliminary study using DTI to examine alterations to WM that persist at least 1 year after TBI experienced in early childhood, specifically before age 7 years. A group of age- and sex-matched children with orthopedic injuries (OIs) were identified as our control group. We hypothesized that the WM tracts in children with TBI would show

Received February 5, 2007; accepted after revision April 23.

From the Departments of Radiology (W.Y., S.K.H., V.J.S., K.M.C., B.V.J., P.K.), and Pediatrics (S.K.H., V.J.S., N.C.W., K.M.C., B.V.J., L.M., S.L.W.), Cincinnati Children's Hospital Medical Center and University of Cincinnati College of Medicine, Cincinnati, Ohio.

This research was supported by National Institutes of Health grant HD044279 from the National Council on Medical Rehabilitation Research in the National Institute of Child Health and Human Development and US Public Health Service General Clinical Research Centers grant M01 RR 08084 from the National Center for Research Resources, National Institutes of Health.

Please address correspondence to Shari L. Wade, Division of Physical Medicine and Rehabilitation/MLC 4009, Cincinnati Children's Hospital Medical Center and University of Cincinnati College of Medicine, 3333 Burnet Ave, Cincinnati, OH 45229; e-mail: shari.wade@cchmc.org

 Indicates article with supplemental on-line table.

DOI 10.3174/ajnr.A0698

significant degeneration as reflected by reduced FA values in various regions in the brain, and the severity of TBI was highly correlated with the changes in FA value in WM.

Materials and Methods

This project was part of a larger research project (National Institutes of Health RO1 HD044279) that studied the familial and social environment of young children with TBI and their influence on cognitive and behavioral recovery. The parent project used a concurrent cohort/prospective research design involving repeated assessments of young children with TBI and young children with OI and their families. Inclusion of a comparison group with OI injuries allowed us to examine the consequences of TBI relative to the functioning of a group of children likely to be similar in family characteristics, preinjury behavior, and the stresses associated with acute hospitalization. The institutional review boards at the participating hospitals approved both the parent project and the imaging study reported here.

Recruitment Criteria

In the parent project, consecutive admissions of children with mild, moderate, and severe TBI or with OI not involving the central nervous system were recruited at ages 36–84 months (at the time of injury). Severity of TBI was defined as follows: severe TBI, GCS score of 8 or less; moderate TBI, a GCS score of 9–12 or a score of 13–15 accompanied by evidence of brain insult at the time of injury (on CT or MR imaging or neurologic examination); and mild TBI, a GCS score of 13–15 with no imaging abnormalities. Inclusion in the orthopedic group required a documented bone fracture (other than the skull) requiring an overnight hospital stay and the absence of any findings suggestive of brain injury (eg, loss of consciousness or symptoms of concussion). We contacted all of the children in the parent project who had sustained a TBI and were older than 6 years of age and at least 12 months postinjury regarding participation in the neuroimaging study. Potentially eligible children with OI were matched on time since injury, age, sex, ethnicity, and handedness with the TBI group.

Participants

Nine children with TBI (6 boys, age = 7.89 ± 1.00 years; range, 6.72–9.10 years) and 12 children with OIs (7 boys, age = 7.51 ± 0.95 years; range, 6.46–9.10 years) from the parent project consented to participate and completed the imaging study successfully. The average GCS score was 10.22 (SD = 4.68). Two children in the TBI group had severe TBI, and 7 had moderate TBI (3 with GCS score <13; 4 with GCS ≥ 13 but with abnormalities on imaging at the time of injury). Two of the TBI group and one of the OI group were left-handers; 1 OI child was ambidexterous. The TBI group and OI group did not differ significantly in age ($t = 0.88$; $P = .39$), sex ratio ($\chi^2 = 0.017$; P not significant), verbal intelligence quotient ($t = 0.07$; $P = .95$), or maternal education ($t = 0.55$; $P = .57$; on-line Table 1).

Structural MR Imaging Evaluations

All of the MR images in this neuroimaging study were acquired at least 1 year after injury. The structural MR imaging was evaluated quantitatively by a board-certified pediatric neuroradiologist for structural abnormalities in the brain with evidence of volume loss, abnormal signal intensity, or evidence of hemorrhage. These imaging features were evaluated in 11 regions and substructures with a scale of 0 reflecting no injury, 1 for mild, 2 for moderate, and 3 for severe injury. The sum of the individual regional scores for each feature was com-

puted for a global rating of chronic brain injury. Eight of the regions considered were classified by hemisphere (right and left) and lobe (frontal, temporal, parietal, and occipital). The remaining 3 regions included the brain stem, cerebellum (vermis and hemispheres), and deep nuclei. Four TBI participants demonstrated abnormalities, 3 of whom had global scores less than 5. However, 1 TBI participant who was previously severely injured (acute GCS of 3) scored a value of 45 due to multiple regions with multiple imaging features and severity scores of 3. Three of the orthopedic control participants had imaging findings. One demonstrated a Chiari I malformation, one a supravermian cyst scaled as a 1, and one a focal region of heterotopic gray matter scaled as a 2.

Image Acquisition

All of the images were acquired on a 3T Trio MR imaging scanner (Siemens, Erlangen, Germany). A 46-section, diffusion-weighted, spin-echo echo-planar imaging scan was acquired in the axial plane with the following parameters: TR/TE = 6000/87 ms; FOV = 25.6×25.6 cm; matrix = 128×128 ; section thickness = 2 mm; b-value = 1000 s/mm^2 ; and 4 repetitions. Diffusion-weighted scans were acquired in 12 optimized directions. Reference T2-weighted images (b = 0) were also acquired. The duration of the DTI sequence was 5 minutes 48 seconds. In addition to the DTI sequence, we acquired a whole-brain 3D magnetization-prepared rapid acquisition of gradient echo (MPRAGE) high-resolution T1-weighted anatomic image with the following parameters: TR/TE = 2000/2.93 ms; FOV = 21.9×21.9 cm; matrix = 256×205 ; section thickness = 1 mm; number of averages = 1; and scan time = 3 minutes 50 seconds. Two subjects had excessive motion, and, thus, another 3D MPRAGE sequence (with same TR/TE) was acquired at a lower resolution and shorter scan time: FOV = 21.9×21.9 cm; matrix = 256×128 ; section thickness = 2 mm; number of averages = 1; and scan time = 2 minutes 30 seconds to ensure acquisition of the anatomic reference data without artifacts.

Data Processing

Image reconstruction, postprocessing, and group statistical analysis were performed either with DTIStudio 2.40 from Johns Hopkins University²⁵ in region of interest (ROI)-based analysis or with routines (Cincinnati Children's Hospital Imaging Processing Software [CCHIPS])^{26,27} written in IDL (Research Systems, Boulder, Colo) for voxel-wise comparison. CCHIPS is available for free downloading at http://irc.cchmc.org/cchips_main.htm.

For DTI data, the 3 eigenvectors and the 3 corresponding eigenvalues (λ_1 , λ_2 , and λ_3) were calculated based on the diffusion tensors, and then the FA map was calculated with the following formula:

$$1) \quad FA = \frac{\sqrt{(\lambda_1 - \lambda_2)^2 + (\lambda_2 - \lambda_3)^2 + (\lambda_1 - \lambda_3)^2}}{\sqrt{2} \sqrt{\lambda_1^2 + \lambda_2^2 + \lambda_3^2}}$$

The Statistical Parametric Mapping analysis package (SPM5; Wellcome Department of Cognitive Neurology, London, United Kingdom) was used for spatial normalization and gray-WM segmentation for all of the subjects. T1-weighted MPRAGE anatomic images were used in this procedure. The WM probability maps were calculated and then transformed into the Montreal Neurologic Institute (MNI) space. Estimation of the corresponding Talairach coordinate²⁸ was conducted according to a nonlinear transformation as described at <http://imaging.mrc-cbu.cam.ac.uk/imaging/MniTalairach>.

To minimize the partial volume effects from gray matter contamination and the "bleeding" effect, we applied stringent criteria to as-

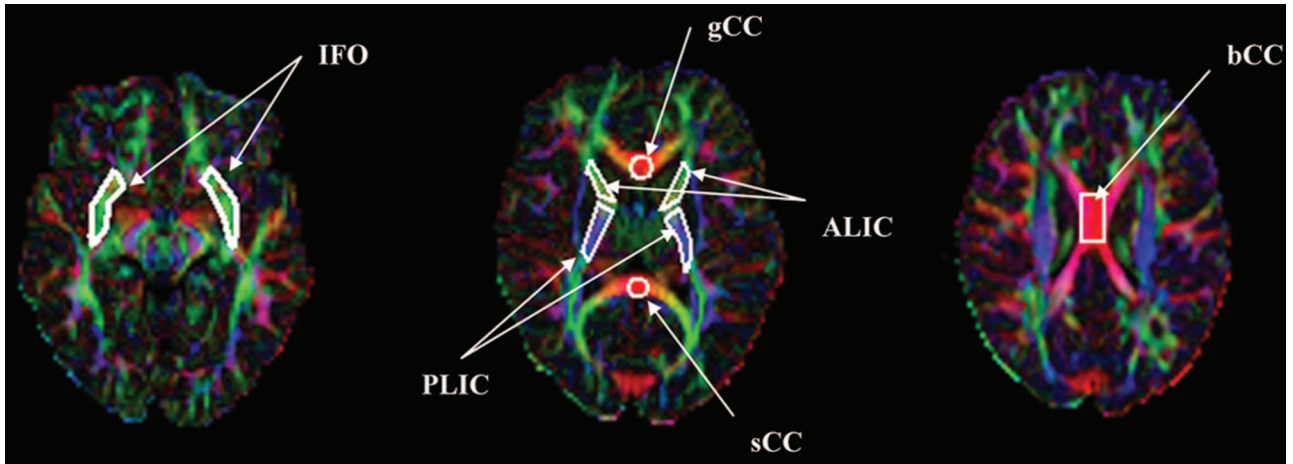


Fig 1. Color-coded FA map from a control participant. ROI include gCC, sCC, bCC, ALIC, PLIC, and IFO.

sure that only the WM was included in the subsequent group analysis. After calculating the FA maps from diffusion tensor and registering them to the MNI space, it was determined that regions retained for further analysis must meet the following criteria: 1) FA >0.25 for all of the individual subjects; 2) a *P* of over 0.9 for assignment as WM in every subject based on the previous SPM5 segmentation results; and 3) the voxels that met criteria 1 and 2 and are common to at least half of the participants (*n* = 11 in the present study).

Statistical Analysis

ROI-Based FA Intergroup Comparison. WM previously reported susceptible to damage after TBI is located at many regions, including interhemispheric fibers (anterior commissure and CC), intrahemispheric (association) fibers (superior longitudinal fasciculus [SLF]), inferior fronto-occipital fasciculus (IFO), inferior longitudinal fasciculus (ILF), IC, projection fibers (pyramidal tract), and other cortical connections.^{21,29} In our ROI-based group comparison, a series of WM regions was selected for each participant: genu, splenium, body of CC (genu of corpus callosum [gCC], splenium of corpus callosum [sCC], and body of corpus callosum [bCC], respectively), anterior and posterior limb of interior capsule (ALIC, PLIC, respectively), SLF, and IFO. As shown in Fig 1, ROIs were outlined on color-coded FA maps following the approach described by Hermoye et al.¹⁹ We first used 1 OI control subject and manually drew all of the ROIs as demonstrated in Fig 1. Then, the ROIs identified in this subject were used as a guide to manually define ROIs for other subjects as reproducibly as possible. All of the ROIs were outlined manually by 1 operator (W.Y.). Each ROI was sampled twice, and the intrarater reliability was evaluated by comparing these 2 sets of samples with a paired *t* test. No significant difference was found (*P* = .52). A 2-tailed Mann-Whitney *U* test was used to test the statistical significance of the FA difference between the TBI and OI groups with a *P* of 0.05 as the threshold.

Voxel-Wise FA Intergroup Comparison. The difference of FA values between the TBI group and the OI group was tested for statistical significance on a voxel-by-voxel basis using Spearman partial correlation analysis (with TBI and OI groups assigned the group values of 1 and 0, respectively). A cluster of 20 (ie, 20 contiguous voxels in 3D space) and nominal *z* > 6 (corresponding with corrected *P* < .001 based on Monte Carlo simulation) were used to improve specificity and adjust for the inflated α from multiple comparisons. Because WM has been found to have different diffusion characteristics

Mann-Whitney *U* test results of ROI-based group comparison

ROIs	FA in TBI (<i>n</i> = 9)	FA in Control (<i>n</i> = 12)	<i>P</i>
sCC	0.69 ± 0.11	0.77 ± 0.06	.06
gCC	0.73 ± 0.04	0.77 ± 0.04	<.05*
bCC	0.69 ± 0.12	0.75 ± 0.05	.22
ALIC	0.53 ± 0.03	0.58 ± 0.04	<.05*
PLIC	0.58 ± 0.02	0.63 ± 0.04	<.01*
SLF	0.49 ± 0.05	0.50 ± 0.05	.42
IFO	0.45 ± 0.06	0.45 ± 0.05	.75

Note:—ROI indicates regions of interest; FA, fractional anisotropy; TBI, traumatic brain injury; sCC, splenium of corpus callosum; gCC, genu of corpus callosum; bCC, body of corpus callosum; ALIC, anterior limb of interior capsule; PLIC, posterior limb of interior capsule; SLF, superior longitudinal fasciculus; IFO, inferior fronto-occipital fasciculus.
* Statistically significant at *P* < 0.05.

in boys and girls,³⁰ we examined the potential confounding influence of the child's sex on group differences. Because including the child's sex as a putative confounder caused more than 20% of the voxels within the ROIs (as determined by the otherwise simple linear regression analysis) to have a greater than 10% change of beta (regression coefficient) value, this variable met the predetermined criterion (over 20% of voxels have over 10% change in beta) and was included as a covariate in the final multivariate analysis.

Voxel-Wise TBI Within-Group Analysis. To analyze the association between TBI severity and WM integrity, a linear regression was performed within the group. This analysis was also performed on a voxel-by-voxel basis to test the significance of the correlation between FA value and GCS score. As before, sex was tested and included as a confounder in the final multivariate linear regression analysis.

Results

ROI-Based FA Intergroup Comparison

The Table shows the results of the comparison of FA values between TBI and OI groups in the selected ROIs. The FA values for the OI group are in close agreement with normal values reported in the literature.^{16,18,19} For children with TBI, there was a small but statistically significant decrease of FA value in the gCC, ALIC, and PLIC (*P* < .05, *P* < .01, and *P* < .05, respectively). There was also a trend for a lower FA value in the sCC (*P* = .06), though the difference did not reach statistical significance.

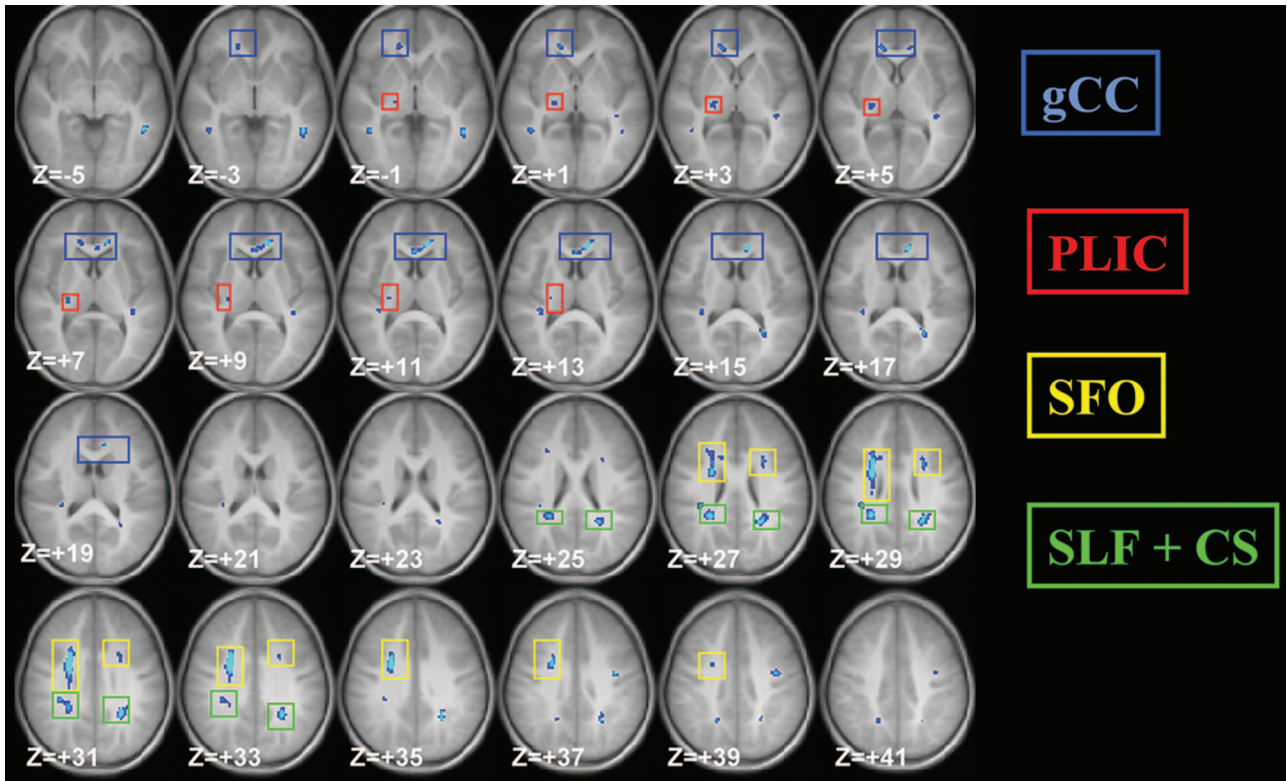


Fig 2. Z-score map for voxel-based FA group comparison. TBI versus control, nominal $z = 6$, cluster size = 20, corrected $P < .001$. Voxels in light blue color represent higher statistical significance than those in dark blue color. The position in z direction is also provided at the lower left corner in each section (in MNI space).

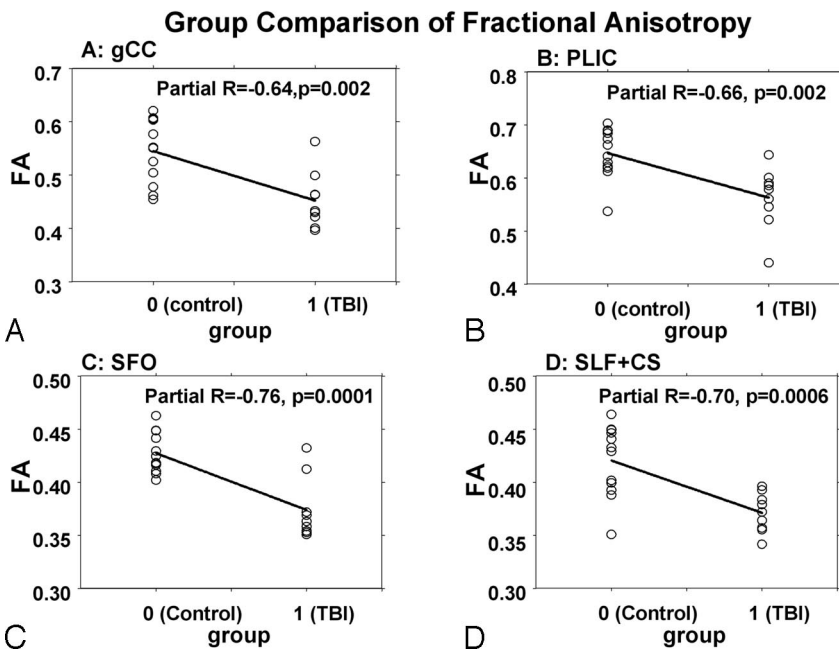


Fig 3. Group comparison of FA values between TBI and control participant, with sex difference controlled for, in (A) gCC; (B) right posterior limb of IC; (C) Fronto-occipital fasciculus; and (D) superior longitudinal fasciculus and other CS regions.

(SFO), SLF, WM in ILF/IFO and nearby regions, WM between SFO and SLF, and WM located further superiorly in CS.

In Fig 2, 4 of these major areas (1, gCC; 2, PLIC; 3, SFO; and 4, SLF and other CS regions) are delineated with rectangles in different colors (blue, red, yellow, and green for the 4 areas, respectively). It should be noted that the name used for an area represents only the major WM tract passing through the region, whereas it may contain WM from other tracts. For each of these areas, mean FA was calculated for all of the pixels for each participant. The linear regression map shows a strong inverse correlation between the mean FA and group (0 for OI group and 1 for TBI group), as illustrated in Fig 3A ($P = .002$, gCC), Fig 3B ($P = .002$, PLIC), Fig 3C ($P = .0001$, SFO), and Fig 3D ($P = .0006$, SLF and other CS regions).

Voxel-Wise FA Intergroup Comparison

As demonstrated in Fig 2, many areas in the WM of the TBI group have significantly lower FA than the control group (nominal $z = 6$; cluster size = 20; corrected $P < .001$). Despite the scattered appearance, many of these areas are contiguous in space and represent important WM structures. The areas found to have significantly lower FA values in the TBI group include the IC, gCC, superior fronto-occipital fasciculus

Correlation between FA and GCS: Voxel-Wise TBI Within-Group Analysis

A multivariable regression analysis was conducted to test the significance of the correlation between WM integrity and TBI severity. As shown in Fig 4, after controlling for sex differ-

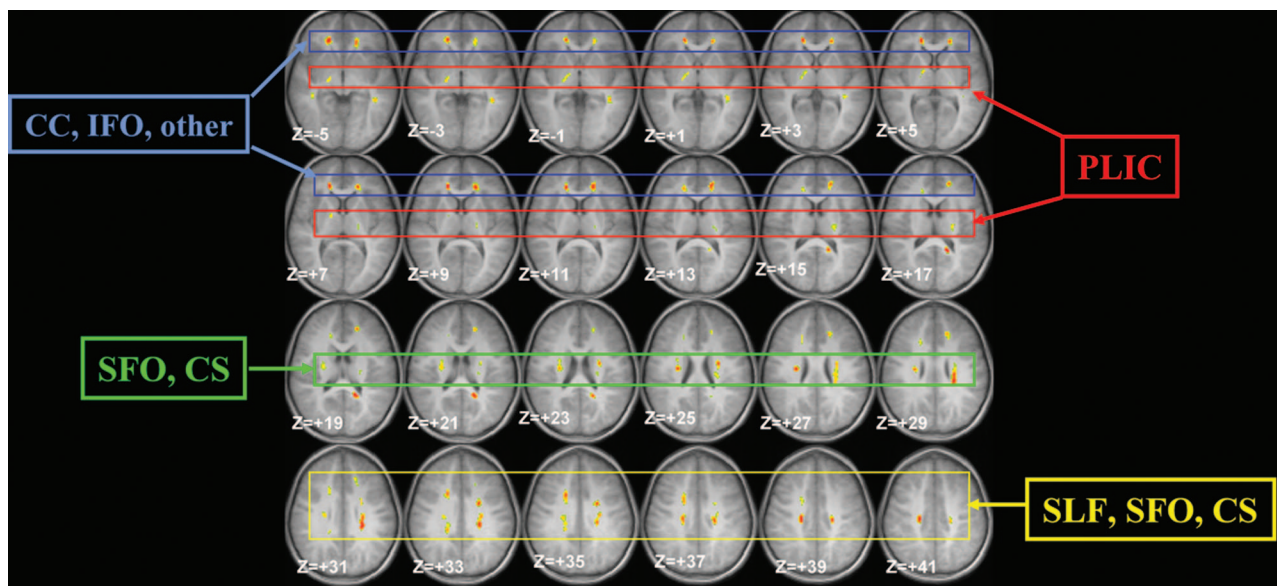


Fig 4. Composite z-score map demonstrating correlation between FA values and GCS scores in TBI group. The z value is calculated based on the R value from the corresponding pixel. Nominal $z = 6$, cluster size = 20, corrected $P < .01$. The voxels with significant correlation are coded with color and overlaid on an anatomic image. Some of these voxels are contiguous in space and represent specific WM structures. Four such groups of voxels are marked with rectangles in different colors. These 4 groups (clusters) are (blue) CC and IFO; (red) PLIC; (green) SFO and CS; and (yellow) SLF, SFO, and CS.

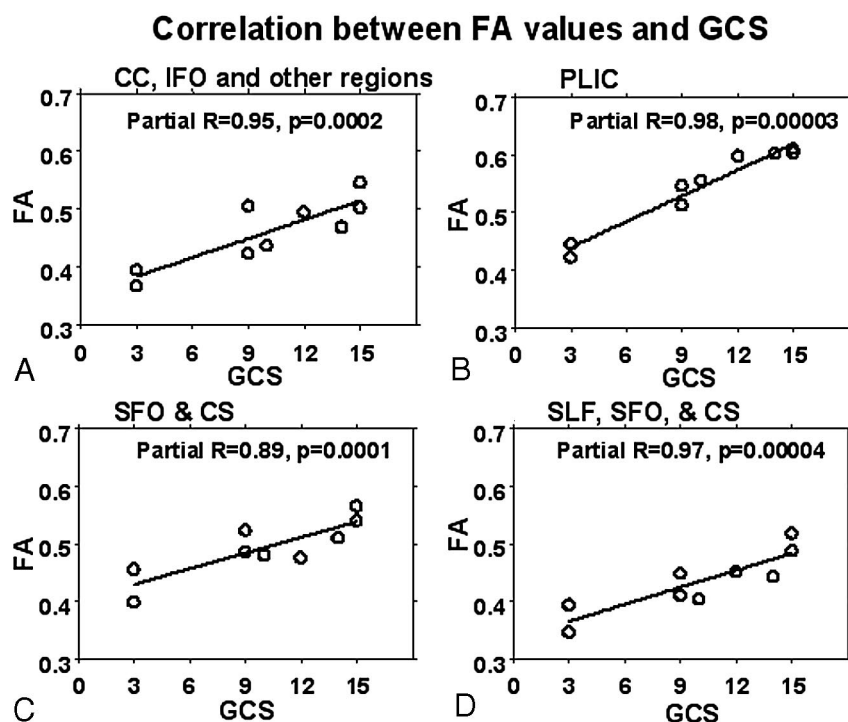


Fig 5. Linear regression of mean FA values adjusted for sex in various focal WM areas vs GCS score. Sex factor is used as covariate. Four subplots A through D correspond with 4 contiguous brain regions as marked with different colored rectangles in Fig 4.

Group 3 (green rectangle) is located at approximately 20–30 mm above anterior/posterior commissure (AC/PC) plane and includes some SFO regions adjacent to ventricle, some regions between SFO and SLF, and, most clearly, in significant areas of corona radiata lateral to the ventricle. Group 4 (yellow rectangle) is located more superiorly at approximately 30–40 mm above the AC/PC plane and includes some WM between SFO and SLF, various portions of SFO at multiple locations, and other WM regions located more superiorly in CS.

As shown in Fig 5, these 4 groups of voxels all demonstrate significant positive correlation between FA and GCS scores ($P < .001$, $P < .0001$, $P < .005$, $P < .0001$ for groups 1–4, respectively). In these analyses, less severe injuries (as reflected by higher GCS scores) were highly correlated with higher FA values.

ences, multiple WM areas demonstrate significant association between FA and GCS (nominal $z = 6$; cluster size = 20; corrected $P < .01$, based on Monte Carlo simulation).

We categorized some of these major areas with significant correlation into 4 separate groups (groups 1–4) using rectangles of different colors (blue, red, green, and yellow), as shown in Fig 4. These 4 groups of voxels are distributed as follows: group 1 (blue rectangle) mainly involves part of the gCC and some WM areas where CC and IFO cross each other. Group 2 (red rectangle) mainly includes bilateral regions in the PLIC.

lated with higher FA values.

Discussion

FA is a measurement of the degree of directionality of the diffusion of water molecules in tissue and conveys physiologically relevant information about the integrity of WM structure and geometric organization. Lower FA often suggests a degradation of WM tracts and/or a breakdown of the barriers, such as the myelin sheaths and axonal membranes, for water diffusion. In the current study, only the 2 most severely injured

jured children, more than a year after injury, had significant abnormalities that were detectable on conventional MR imaging. For other children with TBI, the injury was difficult to characterize with conventional MR imaging and is probably underestimated. We observed extensive reductions in FA values throughout the WM of these young children, which may reflect the alteration of WM integrity in these regions after the injury. The apparent sensitivity and quantitative correlation of FA to the severity of injury remote to the time of brain trauma suggest that this imaging technique may offer new possibilities for both prognosis and monitoring the impact of rehabilitation on WM organization.

In comparison to the few previous studies that used DTI to characterize diffuse axonal damage after TBI in children,^{31,32} the current study adds significantly to our knowledge in 2 respects. First, the findings in our study are based on data from young children who were an average of 2.3 years postinjury, and most (78%) had injuries of moderate severity. In the study by Wilde et al,³² the average GCS score was 5.7, whereas the mean GCS for our sample was 10.22. Thus, the results from our study suggest that differences in WM integrity in children after early childhood TBI may persist for several years, even among children with less severe TBI. Second, the application of DTI using both an ROI-based comparison and a voxel-wise exploratory method provides complementary information about the impact of TBI on WM integrity based on the nature of these 2 data analysis methods, even in this relatively small sample of subjects. Consistent with our hypotheses and previous investigations in children^{31,32} and in adults,²⁰ our ROI-based comparisons revealed a significant decrease of FA in young children with TBI in 3 of the regions being studied (gCC, PLIC, and ALIC). Differences in the sCC also approached statistical significance. Extending previous investigations, voxel-wise analysis was used to explore WM throughout the brain, including areas that may be affected by the TBI but might be beyond the range of a priori hypotheses and predefined ROIs.

Although voxel-wise analysis is not hypothesis driven and can, therefore, provide scattered and difficult-to-interpret results, findings in the current investigation revealed many abnormal areas, for example, CS, SLF, SFO, as shown in Fig 2, that would elude ROI-based comparisons. One such specific example is the WM tissue in the CS that demonstrated a significant difference in FA. Because the CS includes an extensive area in the brain, there is no objective and precise method to outline its range, thus, defying ROI-based comparison. In general, this voxel-wise approach showed that significant FA value changes occurred in extensive WM areas including gCC, PLIC, SLF, IFO, SFO, ILF, and extensive regions in CS. These findings indicate that persistent WM changes after TBI in young children may extend into a variety of WM tracts, especially those relatively long fiber tracts that connect the 2 hemispheres (gCC), those that connect different lobes (SLF, IFO, SFO, and ILF), or, in the case of PLIC, as a part of a long projection fiber that extends from the vertex of cerebral cortex to cerebral peduncle. The mechanism underlying the vulnerability of these WM structures during TBI warrants further study. Subsequent research should examine how reduced FA values in each of these regions correspond with changes in neuropsychological abilities and behavioral performance.

Examining the relationship between GCS scores and FA values within the TBI group, we found that the FA value in many regions was highly correlated with the GCS score, similar to previous findings in adults,²¹ suggesting that FA values may provide a sensitive index of injury severity. It is interesting to note that, comparing Figs 2 and 4, in some of the regions, such as gCC, PLIC, SFO, and SLF, FA values in TBI patients not only differed from those in the control group but were also strongly correlated with the GCS score, indicating an association between the FA value and injury severity. However, in some other regions, such as corona radiata located lateral to ventricles, FA value was significantly correlated with GCS score (Fig 4, $Z = 19-29$), but the group difference was not significant (Fig 2). This suggests that the injury may have caused subtle changes to the WM in the region but was not severe enough to differentiate the TBI population as a group from the control group.

Limitations

The results of voxel-wise analysis cannot not be regarded as a strict superset of the results from ROI-based analysis, and, thus, these approaches at times yield apparently contradictory results. For example, although the ROI-based analyses found group differences in FA values in the ALIC and PLIC, the voxel-wise analyses revealed group differences in only a small region in PLIC and no differences in ALIC (Fig 2). There are several possible sources of these apparent discrepancies. First, the use of very stringent criteria to control for multiple comparisons in the voxel-wise analyses will limit the number of voxels that reach the significant threshold. A more liberal standard would lead to more voxels showing up as significant regions on Fig 2; however, there would be an accompanying increase in false-positive results, which might be misleading. The normalization procedure used in the voxel-wise analysis might serve as another potential source of discrepancy. Normalizing data to a standard brain template is a routine procedure and has been applied extensively in various imaging studies.^{28,33} However, this approach involves approximation based on certain landmarks, and some useful information might be lost in the procedure. In addition, the intersubject variance in WM distribution is another possible source for the discrepancy between the 2 methods.

Several additional limitations of the current investigation should also be noted. First, the sample size was small ($n = 9$ for TBI; $n = 12$ for OI), limiting both statistical power and the ability to control for confounding variables. Another limitation was the variability of imaging data at the time of injury. Most of the children in the current sample had CT scans rather than MR imaging, making it difficult to characterize the nature and location of the WM lesions at the time of injury. In addition, we did not have DTI information from the acute injury period, making it impossible to examine changes in WM integrity over the initial year after early childhood TBI.

Conclusion

The current findings suggest that DTI is a feasible, sensitive, and noninvasive means of examining WM changes in young children after TBI. Moreover, our results indicate that DTI can provide useful information about long-term WM changes in children with moderate, as well as severe, injuries. Future in-

vestigations that follow larger cohorts over time will be necessary to characterize WM changes over time after TBI in children, as well as their relationship to cognitive and behavioral outcomes. In this regard, it will be particularly important to examine the relationship between FA values in specific WM regions and both neuropsychologic skills and functional outcomes.

Acknowledgments

This study is supported in part by 1) NIH grant HD044279 from the National Council on Medical Rehabilitation Research in the National Institute of Child Health and Human Development; and 2) USPHS GCRC Grant #M01 RR 08084 from the National Center for Research Resources, NIH. This study is also supported in part by NIH grants R01 CA112181, P01 ES011261 and R21 ES012524.

References

- Fay GC, Jaffe KM, Polissar NL, et al. **Outcome of pediatric traumatic brain injury at three years: a cohort study.** *Arch Phys Med Rehabil* 1994;75:733–41
- Fletcher JM, Ewing-Cobbs L, Miner ME, et al. **Behavioral changes after closed head injury in children.** *J Consult Clin Psychol* 1990;58:93–98
- Janusz JA, Kirkwood MW, Yeates KO, et al. **Social problem-solving skills in children with traumatic brain injury: long-term outcomes and prediction of social competence.** *Child Neuropsychol* 2002;8:179–94
- Povlishock JT, Katz DI. **Update of neuropathology and neurological recovery after traumatic brain injury.** *J Head Trauma Rehabil* 2005;20:76–94
- Shaw K, MacKinnon MA, Raghupathi R, et al. **TUNEL-positive staining in white and grey matter after fatal head injury in man.** *Clin Neuropathol* 2001;20:106–12
- Williams S, Raghupathi R, MacKinnon MA, et al. **In situ DNA fragmentation occurs in white matter up to 12 months after head injury in man.** *Acta Neuropathol (Berl)* 2001;102:581–90
- Anderson VA, Catroppa C, Rosenfeld J, et al. **Recovery of memory function following traumatic brain injury in pre-school children.** *Brain Inj* 2000;14:679–92
- Ewing-Cobbs L, Fletcher JM, Levin HS, et al. **Longitudinal neuropsychological outcome in infants and preschoolers with traumatic brain injury.** *J Int Neuropsychol Soc* 1997;3:581–91
- Ewing-Cobbs L, Miner ME, Fletcher JM, et al. **Intellectual, motor, and language sequelae following closed head injury in infants and preschoolers.** *J Pediatr Psychol* 1989;14:531–47
- Levin HS, Song J, Ewing-Cobbs L, et al. **Word fluency in relation to severity of closed head injury, associated frontal brain lesions, and age at injury in children.** *Neuropsychologia* 2001;39:122–31
- Levin HS, Williams DH, Valastro M, et al. **Corpus callosal atrophy following closed head injury: detection with magnetic resonance imaging.** *J Neurosurg* 1990;73:77–81
- Levin HS, Benavidez DA, Verger-Maestre K, et al. **Reduction of corpus callosum growth after severe traumatic brain injury in children.** *Neurology* 2000;54:647–53
- Mendelsohn DB, Levin HS, Harward H, et al. **Corpus callosum lesions after closed head injury in children: MRI, clinical features and outcome.** *Neuroradiology* 1992;34:384–88
- Le Bihan D, Mangin JF, Poupon C, et al. **Diffusion tensor imaging: concepts and applications.** *J Magn Reson Imaging* 2001;13:534–46
- Neil J, Miller J, Mukherjee P, et al. **Diffusion tensor imaging of normal and injured developing human brain—a technical review.** *NMR Biomed* 2002;15:543–52
- Suzuki Y, Matsuzawa H, Kwee IL, et al. **Absolute eigenvalue diffusion tensor analysis for human brain maturation.** *NMR Biomed* 2003;16:257–60
- Barnea-Goraly N, Menon V, Eckert M, et al. **White matter development during childhood and adolescence: a cross-sectional diffusion tensor imaging study.** *Cereb Cortex* 2005;15:1848–54
- Snook L, Paulson LA, Roy D, et al. **Diffusion tensor imaging of neurodevelopment in children and young adults.** *Neuroimage* 2005;26:1164–73
- Hermoye L, Saint-Martin C, Cosnard G, et al. **Pediatric diffusion tensor imaging: normal database and observation of the white matter maturation in early childhood.** *Neuroimage* 2006;29:493–504
- Arfanakis K, Haughton VM, Carew JD, et al. **Diffusion tensor MR imaging in diffuse axonal injury.** *AJNR Am J Neuroradiol* 2002;23:794–802
- Huisman TA, Schwamm LH, Schaefer PW, et al. **Diffusion tensor imaging as potential biomarker of white matter injury in diffuse axonal injury.** *AJNR Am J Neuroradiol* 2004;25:370–76
- Inglese M, Makani S, Johnson G, et al. **Diffuse axonal injury in mild traumatic brain injury: a diffusion tensor imaging study.** *J Neurosurg* 2005;103:298–303
- Xu J, Vanverg T, Rasmussen I, et al. **High-resolution diffusion tensor imaging of males suffering from traumatic brain injury.** 12th Annual Meeting of Human Brain Mapping, CD-ROM in Neuroimage (2006), S2140; Florence, Italy, 2006
- Ewing-Cobbs L, Hasan KM, Prasad MR, et al. **Corpus callosum diffusion anisotropy correlates with neuropsychological outcomes in twins discordant for traumatic brain injury.** *AJNR Am J Neuroradiol* 2006;27:879–81
- Jiang H, van Zijl PC, Kim J, et al. **DTIStudio: resource program for diffusion tensor computation and fiber bundle tracking.** *Comput Methods Programs Biomed* 2006;81:106–16
- Schmithorst VJ, Wilke M, Dardzinski BJ, et al. **Correlation of white matter diffusivity and anisotropy with age during childhood and adolescence: a cross-sectional diffusion-tensor MR imaging study.** *Radiology* 2002;222: 212–18
- Schmithorst VJ, Holland SK. **Functional MRI evidence for disparate developmental processes underlying intelligence in boys and girls.** *Neuroimage* 2006;31:1366–79
- Talairach J, Tournoux P. *Co-planar Stereotaxic Atlas of the Human Brain.* New York: Thieme Medical; 1988
- Le TH, Mukherjee P, Henry RG, et al. **Diffusion tensor imaging with three-dimensional fiber tractography of traumatic axonal shearing injury: an imaging correlate for the posterior callosal “disconnection” syndrome: case report.** *Neurosurgery* 2005;56:189
- Schmithorst VJ, Difrancesco M, Dardzinski BJ, et al. *Sex Differences in White Matter Diffusion Anisotropy in the Normal Pediatric Population;* Miami: International Society of Magnetic Resonance in Medicine; 2005
- Hasan KM, Kanabar BP, Santos RM, et al. *Diffusion Tensor MRI after Pediatric Brain Injury.* Miami: International Society of Magnetic Resonance in Medicine; 2004: 1350
- Wilde EA, Chu Z, Bigler ED, et al. **Diffusion tensor imaging in the corpus callosum in children after moderate to severe traumatic brain injury.** *J Neurotrauma* 2006;23:1412–26
- Brett M, Christoff K, Cusack R, et al. **Using the Talairach atlas with the MNI template.** *Neuroimage*; 2001;13:S85