

Are your **MRI contrast agents** cost-effective?

Learn more about generic **Gadolinium-Based Contrast Agents**.



**FRESENIUS
KABI**

caring for life

AJNR

**Head and Neuroanatomy: Thieme Atlas of
Anatomy**

AJNR Am J Neuroradiol published online 18 October 2007
<http://www.ajnr.org/content/early/2007/10/18/ajnr.A0733.citation>

This information is current as
of April 20, 2024.

BOOK REVIEW

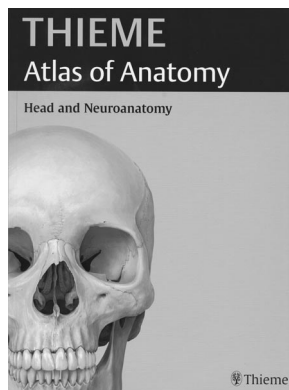
Head and Neuroanatomy: Thieme Atlas of Anatomy

M. Schuenke, E. Schulte, U. Schumacher, L.M. Ross, E.D. Lamperti, and E. Taub, eds. Stuttgart, Germany: Thieme; 2007, 420 pages, 1182 illustrations, 72 tables, \$64.95.

This beautifully illustrated, 420-page, softcover atlas is, in fact, more (*much more*) than a neuroanatomy atlas. The book undersells itself by simply naming it an “atlas.” A more energetic and eye-catching title would have been appropriate for this outstanding work.

The authors (Drs. Schuenke, Schulte, and Schumacher) have joined together the anatomy of the head (bony cranial muscles, blood vessels of the head and neck, cranial nerves, oral cavity, nose, eye and orbit, ear and vestibular apparatus, and sectional anatomy of the head) with detailed neuroanatomy (meninges, ventricular system, cerebrum, diencephalon,

brain stem, cerebellum, blood vessels of the brain, and spinal cord). However, that is not what makes this book special; rather, it is the interposed functional anatomy and clinical correlates to dysfunctional states in each of those anatomic areas. Throughout the book, the text is amplified with important summary tables and charts and, as warranted, histologic diagrams. Clearly, this work is more than an atlas.



A few examples will suffice to demonstrate the value of the book. In the section on functional neuroanatomy of the visual system is detailed functional anatomy of the geniculate, non-geniculate or cortical areas, the visual reflex system, and coordination of eye movement. In a similar manner, the functional aspects of the auditory and vestibular systems are beautifully illustrated and explained. The limbic system, frequently an arcane structure, is laid out both anatomically and functionally in a beautiful, simple, and understandable fashion. Furthermore, by using these 3 sections as examples, one can further coordinate these findings by going to earlier sections to see exquisitely detailed drawings of the eye or, even more stunning, drawings of the middle and inner ear with accompanying stylized histologic features of the small structures contained therein, or drawings of the allocortex (hippocampus and amygdala). It is virtually impossible to describe in words how impressive the drawings are throughout the book. As an aside, there are no radiographs, CTs, or MRs except for 1 set showing Alzheimer disease; please do not consider that a drawback.

The drawings are all in color and are superb. This excellently crafted atlas (and, as I said, it is much more than your typical atlas) should be on the shelves of all those in the clinical neurosciences. The next time you are attending a meeting, stop by Thieme Publishing and thumb through this book; its value will be immediately apparent. This atlas will be referred to often and will serve to clarify questions that arise frequently concerning the functional neuroanatomy of the brain and spinal cord. I will have this atlas on my desk immediately available for the review of many functional neurologic issues that arise daily. I highly recommend this book for all neuroradiologists, regardless of level, training, or experience.

DOI 10.3174/ajnr.A0733