

Are your **MRI contrast agents** cost-effective?

Learn more about generic **Gadolinium-Based Contrast Agents**.



**FRESENIUS
KABI**

caring for life

AJNR

A New Self-Expandable Nitinol Stent for the Treatment of Wide-Neck Aneurysms: Initial Clinical Experience

J.P.P. Peluso, W.J. van Rooij, M. Sluzewski and G.N. Beute

AJNR Am J Neuroradiol published online 24 April 2008

<http://www.ajnr.org/content/early/2008/04/24/ajnr.A1104.citation>

This information is current as of April 17, 2024.

ORIGINAL
RESEARCHJ.P.P. Peluso
W.J. van Rooij
M. Sluzewski
G.N. Beute

A New Self-Expandable Nitinol Stent for the Treatment of Wide-Neck Aneurysms: Initial Clinical Experience

BACKGROUND AND PURPOSE: Stent systems for intracranial use are continuously improved. We report our initial experience using a new self-expanding easy-to-place nitinol stent (Enterprise) in the treatment of wide-neck intracranial aneurysms.

MATERIALS AND METHODS: Between January and October 2007, 16 aneurysms in 15 patients were treated with stent assistance. Aneurysm size was a mean of 13.2 mm (median, 12 mm; range, 7–30 mm). Eight aneurysms had reopened after prior coiling, and 8 aneurysms were primarily treated, 1 after acute subarachnoid hemorrhage. Response to antiplatelet premedication was tested with a P2Y₁₂ assay before stent placement. On a 3D angiographic workstation, stent placement was simulated to assess vessel caliber and appropriate stent length.

RESULTS: In all aneurysms, the stent could be placed at the exact location as predicted from the computer simulation. Stent placement proved to be technically easy without the need for recapture in all patients. Although placement of the microcatheter through the stent struts and subsequent coil placement was challenging in some patients, coiling after stent placement resulted in complete or near-complete occlusion in all aneurysms. There were no technical or clinical complications. At 6 months, angiographic follow-up in 14 aneurysms revealed 4 aneurysms recanalized to 80% occlusion, 3 of which were additionally coiled.

CONCLUSION: In this small series, delivery and deployment of the Enterprise stent was technically easy. There were no technical or clinical complications. The device was valuable in the treatment of wide-neck aneurysms. The need for antiplatelet medication in patients treated with this and other stents remains a significant disadvantage.

Endovascular coil embolization of wide-neck intracranial aneurysms is technically challenging. Several treatment strategies are available to prevent coil migration into the parent vessel. The most widely used technique is balloon-assisted treatment, in which a balloon is temporarily inflated across the aneurysm neck during coil insertion.^{1,2} A permanent neck-bridge device (TriSpan; Boston Scientific, Natick, Mass) may be used to prevent coil migration in wide-neck bifurcation aneurysms.^{3,4} In recent years, stents for intracranial use became available. The first-generation stents were balloon expandable (INX/AVE; Medtronic, Santa Rosa, Calif), but limited flexibility was a major drawback. Later, the first self-expandable stents with an open or closed cell design became available for intracranial use.^{5,6} With some stent systems, the microcatheter has to be exchanged for the stent over a 300-cm microguidewire. The new Enterprise stent (Cordis Neurovascular, Miami Lakes, Fla) is a highly flexible nitinol stent, which can be delivered through a standard microcatheter, which is technically easier than the exchange procedure.^{7–9}

In this study, we report our initial clinical experience with this new stent system in the treatment of 16 wide-neck intracranial aneurysms.

Methods

Patients

Between January and October 2007, 16 aneurysms in 15 patients were treated with stent assistance (Table). There were 5 men and 10 women with a mean age of 53.8 years (median, 54 years; range, 36–66 years). Eight aneurysms had reopened after 1–3 prior coilings and were additionally treated 6–106 months after the first coiling. Eight aneurysms (1 ruptured and 7 unruptured) were primarily treated. Of 7 unruptured aneurysms, 3 were incidentally found, 3 were in addition to another ruptured aneurysm, and 1 was a dissection aneurysm. Aneurysm size was a mean of 13.2 mm (median, 12 mm; range, 7–30 mm). Aneurysm location was basilar tip in 7; ophthalmic artery in 2; and posterior inferior cerebellar artery, superior cerebellar artery, supraclinoidal internal carotid artery, cavernous sinus, middle cerebral artery, anterior communicating artery, and extracranial carotid artery. All aneurysms and aneurysm recurrences had very wide necks and were judged impossible to treat with other techniques. After treatment, clinical follow-up was scheduled at 6 weeks in the neurosurgical outpatient clinic and angiography was scheduled at 6 months.

Treatment Techniques

Preprocedure Testing. Patients with unruptured or previously coiled aneurysms were preloaded with clopidogrel (300-mg loading dose and 75 mg daily for 3 days) and aspirin (80 mg daily). Patients with ruptured aneurysms received 500-mg intravenous aspirin before stent placement. We used the VerifyNow rapid platelet function assay-aspirin (Ultegra RPFA-ASA; Accumetrics, San Diego, Calif) to calculate aspirin reaction units (ARU) and the P2Y₁₂ assay (VerifyNow) to calculate P2Y₁₂ reaction units and percentage platelet inhibition immediately before the stent placement. Aspirin resistance or low response was de-

Received January 11, 2008; accepted after revision February 28.

From the Departments of Radiology (J.P.P.P., W.J.v.R., M.S.) and Neurosurgery (G.N.B.), St. Elisabeth Ziekenhuis, Tilburg, the Netherlands.

Please address correspondence to Willem Jan van Rooij, MD, PhD, Department of Radiology, St. Elisabeth Ziekenhuis, Hilvarenbeekseweg 60, 5022 GC Tilburg, the Netherlands; e-mail: wjvanrooij@gmail.com

DOI 10.3174/ajnr.A1104

Characteristics of 15 patients with 16 aneurysms treated with stent assistance

Patient No.	Sex, Age (year)	Aneurysm Location	Treatment Indication	Aneurysm Size	Dome-to-Neck Ratio of Aneurysm or Recurrence
1	M, 66	Basilar tip	Recurrence	20	0:4
2	M, 60	Basilar tip	Recurrence	7	1:5
3	M, 49	Basilar tip	Recurrence	16	0:8
4	F, 58	Superior cerebellar artery	SAH	12	1:2
	F, 58	ICA	Additional	11	1:0
5	F, 66	Middle cerebral artery	Unruptured	10	1:2
6	F, 52	Ophthalmic artery	Recurrence	16	1:4
7	M, 65	Basilar tip	Recurrence	13	0:7
8	F, 39	Ophthalmic artery	Additional	8	0:8
9	F, 60	Cavernous sinus	Recurrence	30	1:3
10	F, 50	Basilar tip	Recurrence	10	0:7
11	F, 49	AcomA	Unruptured	9	1:1
12	F, 46	PICA	Additional	12	1:0
13	M, 51	Extracranial ICA	Dissection	7	1:0
14	F, 36	Basilar tip	Recurrence	16	1:0
15	F, 56	Basilar tip	Recurrence	14	0:8

Note:—SAH indicates subarachnoid hemorrhage; AcomA, anterior communicating artery; PICA, posterior inferior cerebellar artery; ICA, internal carotid artery.

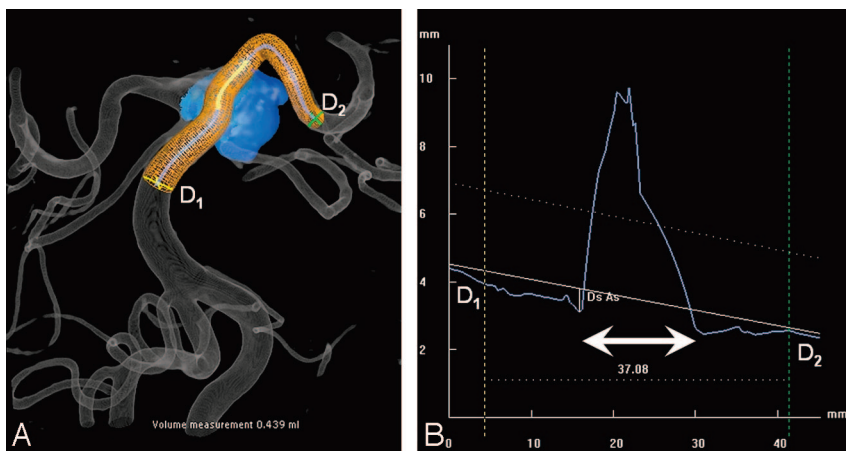


Fig 1. Computer simulation before stent placement in a superior cerebellar artery aneurysm (same patient as in Fig 2). *A*, 3D image after automated aneurysm detection (blue) and stent simulation. *B*, Corresponding graph indicating vessel diameters in segment lengths. Proximal and distal diameters are indicated by D1 (4.2 mm) and D2 (2.5 mm). The aneurysm neck is indicated by the bidirectional arrow. Use of a 37-mm stent will provide a proximal and distal overlap of 10 mm.

defined as ARU \geq 550, whereas clopidogrel resistance or low response was defined as percentage platelet inhibition \leq 40%. Both clopidogrel and aspirin were continued after the procedure for 3–6 months.

Coiling Procedure. Coiling was performed with the patient under general anesthesia on a biplane angiographic system (Integris BN 3000 Neuro; Philips Medical Systems, Best, the Netherlands). In all patients, 3D rotational angiography (3DRA) was performed of the vessel harboring the aneurysm. On a dedicated 3DRA workstation (Philips Medical Systems), stent placement was simulated by computer graphics on the 3D image (Figs 1 and 2). The software exactly calculates diameters and length of the vessel segment where the stent placement is intended. Accordingly, the proper stent length can be chosen. We aimed at a 10-mm stent overlap on either side of the aneurysm neck. After stent placement, the delivery microcatheter was removed. A new lower profile microcatheter (Excelsior 10; Boston Scientific) was introduced through the stent struts into the aneurysm, and coils were placed until the aneurysm was occluded. The Excelsior 10 microcatheter accommodates coils of different thicknesses, including 0.015-inch coils.

The Enterprise Stent. The Enterprise stent (Cordis Neurovascular) is a self-expandable highly flexible closed-cell stent. It is mounted on a flexible delivery wire and is delivered through a standard microcatheter (Prowler Select Plus; Cordis Neurovascular). Tantalum markers are attached to each side of the stent to facilitate visualization. The stent is partially retractable, which allows repositioning.

To place the stent, one must first navigate the microcatheter across the aneurysm neck. The stent is then introduced into the microcatheter and positioned over the aneurysm neck. The stent is deployed by retracting the microcatheter while keeping the stent in place. It can be recaptured up to the point where 70% of stent length is released. Once the proximal stent markers exit the tip of the microcatheter, the stent is fully deployed. During the study period, the only available stent diameter was 4.5 mm in lengths of 14, 22, 28, and 37 mm. The recommended parent vessel diameter for this stent diameter is 2.5–4 mm.

Results

Initial Results and Complications

In all aneurysms, the stent could be placed at the exact location as predicted from the computer simulation. Stent placement proved to be technically straightforward without the need for recapture in all cases. Once the delivery microcatheter was in the desired position, the stent easily negotiated the vascular curves. Although placement of the microcatheter through the stent struts and subsequent coil placement was challenging in some cases, coiling after stent placement resulted in complete or near-complete aneurysm occlusion in all 16 aneurysms. There were no technical or clinical complications.

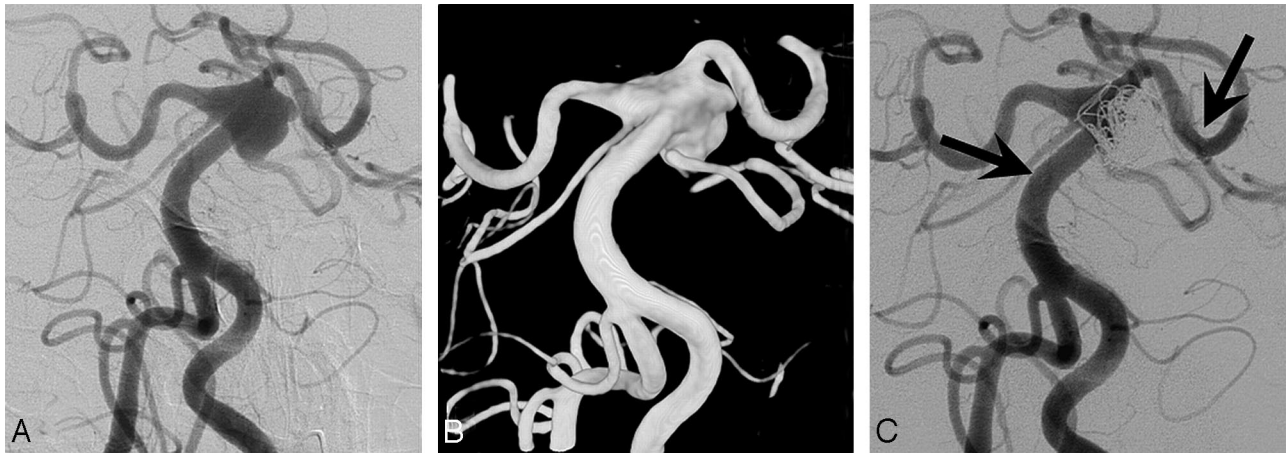

Fig 2. A 58-year-old woman with a ruptured superior cerebellar artery aneurysm without a neck. *A* and *B*, 2D and 3D vertebral angiograms demonstrate the dysplastic distal basilar segment with a large superior cerebellar artery aneurysm. The superior cerebellar artery arises from base of the aneurysmal sack, and the dysplastic segment extends to the proximal posterior cerebral arteries. *C*, Result after stent-assisted coiling. Proximal and distal stent markers are indicated by arrows. Flow in the superior cerebellar artery is preserved.

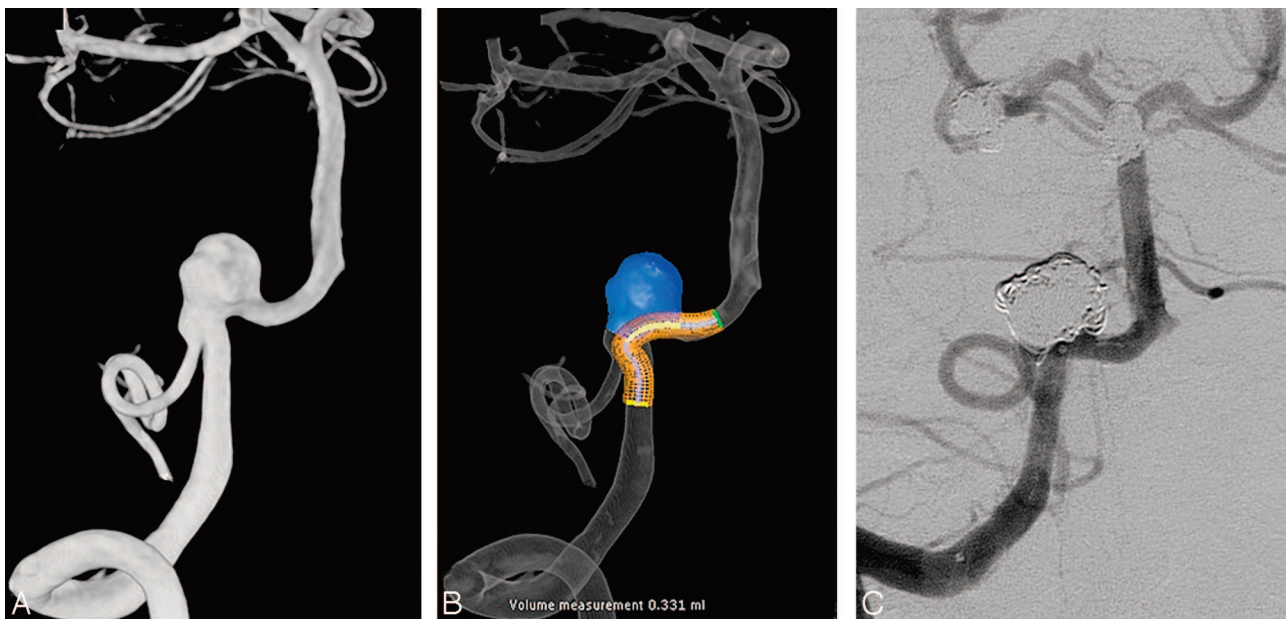


Fig 3. A 46-year-old woman with a wide-neck posterior inferior cerebellar artery aneurysm, additional to another ruptured aneurysm. *A*, 3D angiogram demonstrates the posterior inferior cerebellar artery originating from the base of the aneurysm. *B*, 3D image after automated aneurysm detection and stent simulation. *C*, Complete occlusion after stent-assisted coiling with preserved flow in the posterior inferior cerebellar artery.

Angiographic Follow-Up

Six-month angiographic follow-up was available for 14 aneurysms; 2 aneurysms are scheduled for follow-up. Of 13 aneurysms, 8 remained adequately occluded. Five aneurysms partially reopened by coil compaction, and 3 of these were additionally coiled. Additional coilings were without complications.

Representative Cases

A 58-year-old woman presented with acute poor-grade subarachnoid hemorrhage (Figs 1 and 2). Angiography demonstrated a 12-mm superior cerebellar artery aneurysm with an extremely wide neck in a dysplastic basilar tip. The superior cerebellar artery itself arose from the base of the aneurysm. After administration of 500-mg aspirin intravenously, a 22-mm stent was placed in the left posterior cerebral artery and basilar artery across the aneurysm neck. Subsequently, coils were placed until adequate occlusion was achieved. Due

to the very wide neck, the transition between basilar artery and the aneurysmal sac was unclear and some coil loops surrounded the stent. The patient completely recovered, and 6-month follow-up angiography demonstrated stable adequate aneurysm occlusion.

A 46-year-old woman was coiled in 2004 after rupture of a posterior communicating artery aneurysm. On angiography, 5 additional aneurysms were discovered, among them was a 12-mm posterior inferior cerebellar artery aneurysm with very wide neck (Fig 3). This aneurysm was treated with stent assistance. A 22-mm stent was placed across the aneurysm neck, and coils were inserted until the aneurysm was occluded with preserved flow in the parent posterior inferior cerebellar artery. At 6-month angiographic follow-up, the aneurysm had reopened with persistent filling of the lumen. After additional coil placement, the aneurysm was completely occluded.

Discussion

Use of a stent across the aneurysm neck to prevent coil herniation in the parent artery during coil insertion is an appealing technique. However, in our experience using first- and second-generation stents,^{5,6,10,11} exact placement proved to be quite problematic. The most important technical drawback was the exchange procedure over a 300-cm microguidewire. This guidewire had to be positioned far distal in the cerebral vasculature to ensure ample anchoring. While keeping tension on the wire, the stent system had to be negotiated through the vessel curves, which sometimes proved impossible because of limited stent flexibility. During pushing of the stent system, the guidewire was prone to migrate distally with possible perforation of distal small vessels (in patients under full anticoagulation). Because of these technical difficulties, we were very reluctant to treat wide-neck aneurysms with stents, and indication was limited to aneurysms that could not be treated with other techniques such as balloon or TriSpan assistance.

Another major drawback of stent placement is its thrombogenicity, with a need for prolonged antiplatelet therapy. With the use of clopidogrel, response must be verified with an appropriate test because many patients are nonresponders.¹²⁻¹⁵

The new Enterprise stent proved to be easier to handle than earlier stent systems. In all patients, we were able to place the stent at the exact site predicted by the simulation program on the 3DRA workstation. In some large and wide-neck aneurysms, it was awkward to pass the delivery microcatheter distal to the aneurysm neck. However, once the microcatheter was in the correct position distal to the aneurysm neck, the stent demonstrated sufficient flexibility and passed vessel curves without manifest friction. Although the stent is partially retractable for repositioning, we found no need to use this feature.

The next step, introduction of the microcatheter through the stent struts into the aneurysm, was easy in most cases. To facilitate passing the stent struts, we usually exchanged the delivery microcatheter for a lower profile catheter (Excelsior 10). With deployment of the first coil, exit of the first coil loop through the stent struts into the parent artery should be avoided, because it was sometimes hard to see whether the coil loop protruded through the stent struts. With increasing aneurysm occlusion by the coils, the microcatheter sometimes kicked back into the parent artery, and re-entering the aneurysm by using the coil as a guidewire was at times troublesome. With this maneuver, it was possible that the microcatheter entered the aneurysm at a different point through the stent, resulting in hooking the coil over a stent strut. If the coil cannot be delivered and has to be withdrawn, danger of coil stretching and coil fracture exists. When a certain compartment of the aneurysm remains insufficiently filled with coils, re-entering the aneurysm in this particular compartment may be difficult or impossible, especially when the entrance angle of the microcatheter through the stent is $<90^\circ$.

These technical hitches make adequate aneurysm occlusion with coils after stent placement, in our opinion, more difficult than with conventional supportive techniques. Thus, despite the availability of an easy-to-place stent system, the aforementioned technical problems in combination with the need for antiplatelet therapy have not resulted in expanding the indication for stent-assisted treatment in our institution,

and only aneurysms that cannot be treated with conventional supportive techniques are coiled after stent placement.

The dual microcatheter trapping technique of placing a catheter into the aneurysm first and then placing the stent struts with the microcatheter. With unfavorable aneurysm and parent vessel geometry, this technique might be helpful.

Some authors first occlude an aneurysm with coils and afterward place a stent across the aneurysm neck in the assumption that occlusion of the aneurysm over time will be more stable.¹¹ We strongly discourage this treatment strategy. In our opinion, confirmed in a recent prospective study,¹⁶ placing a stent after coiling introduces an additional risk of complications, both by the stent placement itself and by the antiplatelet medication, which is needed as a consequence.

Conclusion

In this small series, delivery and deployment of the Enterprise stent was technically easy. There were no technical or clinical complications. The device was valuable in the treatment of wide-neck aneurysms. The need for antiplatelet medication in patients treated with this as well as other stents remains a significant disadvantage.

References

1. Moret J, Cognard C, Weill A, et al. **Reconstruction technic in the treatment of wide-neck intracranial aneurysms: long-term angiographic and clinical results—apropos of 56 cases** [in French]. *J Neuroradiol* 1997;24:30–44
2. Sluzewski M, van Rooij WJ, Beute GN, et al. **Balloon-assisted coil embolization of intracranial aneurysms: incidence, complications, and angiography results.** *J Neurosurg* 2006;105:396–99
3. Raymond J, Guilbert F, Roy D. **Neck-bridge device for endovascular treatment of wide-neck bifurcation aneurysms: initial experience.** *Radiology* 2001;221:318–26
4. De Keukeleire K, Vanlangenhove P, Defreyne L. **Evaluation of a neck-bridge device to assist endovascular treatment of wide-neck aneurysms of the anterior circulation.** *AJNR Am J Neuroradiol* 2008;29:73–78. Epub 2007 Oct 10
5. Fiorella D, Albuquerque FC, Deshmukh VR, et al. **Usefulness of the Neuroform stent for the treatment of cerebral aneurysms: results at initial (3–6-mo) follow-up.** *Neurosurgery* 2005;56:1191–1201, discussion 1201–02
6. Kis B, Weber W, Berlit P, et al. **Elective treatment of saccular and broad-necked intracranial aneurysms using a closed-cell nitinol stent (Leo).** *Neurosurgery* 2006;58:443–45
7. Higashida RT, Halbach VV, Dowd CF, et al. **Initial clinical experience with a new self-expanding nitinol stent for the treatment of intracranial cerebral aneurysms: the Cordis Enterprise stent.** *AJNR Am J Neuroradiol* 2005;26:1751–56
8. Weber W, Bendszus M, Kis B, et al. **A new self-expanding nitinol stent (Enterprise) for the treatment of wide-necked intracranial aneurysms: initial clinical and angiographic results in 31 aneurysms.** *Neuroradiology* 2007;49:555–61
9. Benndorf G, Klucznik RP, Meyer D, et al. **“Cross-over” technique for horizontal stenting of an internal carotid bifurcation aneurysm using a new self-expandable stent: technical case report.** *Neurosurgery* 2006;58(suppl 1):ONS-E172
10. Lee YJ, Kim DJ, Suh SH, et al. **Stent-assisted coil embolization of intracranial wide-necked aneurysms.** *Neuroradiology* 2005;47:680–89
11. Biondi A, Janardhan V, Katz JM, et al. **Neuroform stent-assisted coil embolization of wide-neck intracranial aneurysms: strategies in stent deployment and midterm follow-up.** *Neurosurgery* 2007;61:460–68
12. Prabhakaran S, Wells KR, Lee VH, et al. **Prevalence and risk factors for aspirin and clopidogrel resistance in cerebrovascular stenting.** *AJNR Am J Neuroradiol* 2008;29:281–85. Epub 2007 Nov 7
13. Jaremo P, Lindahl TL, Fransson SG, et al. **Individual variations of platelet inhibition after loading doses of clopidogrel.** *J Intern Med* 2002;252:233–38
14. Gurbel PA, Bliden KP, Hiatt BL, et al. **Clopidogrel for coronary stenting: response variability, drug resistance, and the effect of pretreatment platelet reactivity.** *Circulation* 2003;107:2908–13
15. Serebruany VL, Steinhubl SR, Berger PB, et al. **Variability in platelet responsiveness to clopidogrel among 544 individuals.** *J Am Coll Cardiol* 2005;45:246–51
16. White PM, Lewis SC, Nahser H, et al, for the HELPS Trial Collaboration. **HydroCoil Endovascular Aneurysm Occlusion and Packing Study (HELPS Trial): Procedural Safety and Operator-Assessed Efficacy Results.** *AJNR Am J Neuroradiol* 2008;29:217–23. Epub 2008 Jan 9