

Are your **MRI contrast agents** cost-effective?

Learn more about generic **Gadolinium-Based Contrast Agents**.



**FRESENIUS
KABI**

caring for life

AJNR

**Magnetic Resonance Imaging of the Brain
and Spine, 4th ed., Vol. 1 and 2**

AJNR Am J Neuroradiol published online 11 March 2009
<http://www.ajnr.org/content/early/2009/03/11/ajnr.A1553.citation>

This information is current as
of April 19, 2024.

BOOK REVIEW

Magnetic Resonance Imaging of the Brain and Spine, 4th ed., Vol. 1 and 2

S.W. Atlas, ed. Lippincott Williams & Wilkins; 2008, 2000 pages, 6800 illustrations, \$429.00.

In a major and impressive expansion of his classic *Magnetic Resonance Imaging of the Brain and Spine*, Dr. Scott Atlas, in this fourth edition, has presented the neuroscience community with an in-depth and beautifully illustrated 2-volume (2000 pages) neuroradiology textbook. With 83 contributors, including neuroradiologists, neuropathologists, neurosurgeons, and physicists, one is confronted with a text containing descriptions and illustrations of most entities one would encounter in a practice of neuroradiology. An extra and important feature of this publication is the inclusion of the text as an on-line version (with your validated code).

This 2-volume set is divided into 5 parts: Principles of MR Imaging (191 pages), Brain (892 pages), Skull Base (274 pages), Spine and Spinal Cord (373 pages), and Advanced Applications (150 pages). Each of these parts could stand as a separate book on its own, so in reality, this single purchase would be equivalent to buying 5 separate books.

Compared with the third edition, published in 2002, this new edition has expanded features, increased text, and more illustrations. In a parenthetical sense, I do miss the chapter outline that was present at the beginning of each chapter in the third edition. Many chapters have new information so to fit all of this into an outwardly comparable-sized text; the publisher has wisely decreased the dimensions of the illustrations and lessened the font size in both the text and in the legends. With these style changes, along with a new formatting of charts and tables, the result is crisp and easy-to-read material. Along with the descriptive material, the chapters contain state-of-the-art MR images.

Volume 1 consists of 2 parts: 1) Principles and 2) Brain. The material covered in "Part One: Principles" includes instrumentation, contrast development and manipulation, image formation, flow and hemodynamics, fast imaging, and artifacts. It is doubtful that many will read this section from beginning to end, but certainly it will be used to look for a specific technique or an explanation of how a certain MR image is performed. "Part Two: Brain" (which is the largest of the

book) includes disorders of brain development, central nervous system phakomatoses, epilepsy, white matter disease and inherited metabolic disorders, brain tumors (adult and pediatric), intracranial hemorrhage, vascular malformations and aneurysms, ischemia/infarction, MR angiography, trauma, infection, the aging brain, dementia, and neurodegenerative disorders. In this part of

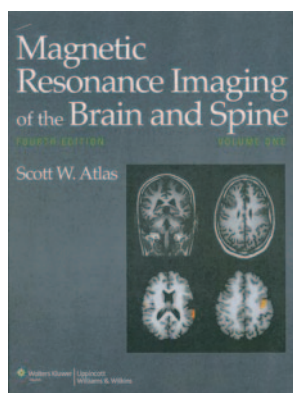
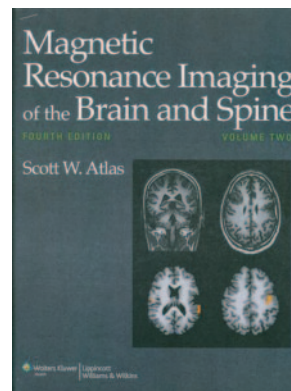
the book, I would have liked to have seen a separate chapter on the normal development of the brain. This could have included illustrations of the progressive maturation of the brain from the neonate to the young adult. Although such information is available from other sources, the changing signal intensity of gray and white matter and the pulse sequences used to elucidate the maturation should

be in a publication that strives for completeness. This concept would be a valuable chapter to add to a fifth edition.

Volume 2 consists of the 3 parts, the first of which ("Part Three") contains chapters on the skull base, sella and the parasellar region, temporal bone, and eye/orbital/visual system. The chapter on the temporal bone does contain information and illustrations on the postoperative temporal bone, but this could have been expanded and is recommended for a future edition. In general, most textbooks pay minimal attention to postoperative interpretations, but as we all know, these studies are a significant part of our work and often are the most vexing in interpretation. "Part Four: Spine and Spinal Cord" includes chapters on congenital spinal anomalies, degenerative disk disease, spinal cord and spinal tumors, trauma, vascular disorders, and spinal infection/inflammation.

The last part of the book ("Part Five: Advanced Applications") deals with advanced applications with chapters on the fetal spine and brain, diffusion and diffusion tensor imaging, perfusion imaging, clinical functional MR imaging, psychiatric disease, MR spectroscopy, and contrast agents. Although these chapters in the textbook retain similar titles, the material contained in each chapter has markedly expanded in many. For instance, consider the chapter on MR spectroscopy: the authors have changed (now Drs. Ratai and Gonzalez), the length has increased from 19 to 34 pages, and the explanations have expanded (with informative accompanying tables). The high-quality spectra, along with multivoxel displays and the metabolic maps, make this typical of the marked upgrades present throughout the book. Take another example, the chapter on spinal trauma. This chapter, written by Drs. Flanders and Schwartz, not only brings into consideration the many clinical aspects of spinal cord injury, but also devotes an entire section in that chapter on advanced techniques applicable to the injured spinal cord: diffusion-weighted imaging, diffusion tensor imaging, axon morphometry, tractography, thalamic MR imaging (in chronic dysesthetic pain), functional MR imaging of the spinal cord, and some work on transplantation. Although clearly these techniques do not have a role in daily clinical neuroradiology at the present time, this feature is pointed out as just one instance to show the extent to which Dr. Atlas has gone to ensure up-to-date information in the books.

It is difficult to write a review of such a complete work as this, but sample chapters and selected areas reveal the book's quality and value. For example, in the first chapter, "Instrumentation: Magnets, Coils and Hardware," one receives con-



cise summaries of the main magnets, gradient and radiofrequency coils, higher field MR imaging (3T and above), digital hardware, surface coils, and parallel imaging. Although parts of this chapter (like the detailed information fast imaging that only a physicist could love) go beyond what a neuroradiologist wants to know, it is safe to state that the fundamentals of what is needed are covered well. The only criticism of this section of the book is the lack of information on MR imaging safety (other than a very brief and perfunctory paragraph). I would encourage the addition of such a chapter in a future edition because, in reality, those guidelines and safety issues are much more of a concern to a neuroradiologist than detailed physics. There are other areas where additional material would be welcomed, but in a discipline as large and varied as neuroradiology and MR imaging of the brain and spine, it borders on the impossible to be totally inclusive and keep the volumes less wordy than that of the *Oxford English Dictionary*.

Often, the way to test the usefulness of a book is to randomly choose a topic or disease and see if the material was

covered or was at least easily searchable. I looked up *limbic encephalitis* in the index and could not find it under that term or under *encephalitis*. Then I tried to find a description or an illustration of an MR image in a patient in a hypoglycemic coma; that search was unsuccessful, but my search for spinal muscular atrophy was successful (though no illustrations were provided). Perhaps I was unlucky in the first 3 topics that I had chosen. I then searched for more common diseases (herpes encephalitis, amyotrophic lateral sclerosis, spinal cord ependymoma) and found good descriptive material, excellent images, and some histologic and gross anatomic correlates.

My overall impression is that one can no longer write or edit a textbook on neuroradiology that covers everything in an absolutely complete manner. For such information, one must look to specialized books; the field is otherwise simply too vast. In the end, however, if one is searching for a book that adequately covers the major issues in neuroradiology, Dr. Atlas's text would be an excellent choice.

DOI 10.3174/ajnr.A1553