

Are your MRI contrast agents cost-effective?

Learn more about generic Gadolinium-Based Contrast Agents.



FRESENIUS
KABI

caring for life

AJNR

Atypical Teratoid/Rhabdoid Tumors in Adult Patients: CT and MR Imaging Features

L. Han, Y. Qiu, C. Xie, J. Zhang, X. Lv, W. Xiong, W. Wang, X. Zhang and P. Wu

AJNR Am J Neuroradiol published online 4 November 2010
<http://www.ajnr.org/content/early/2010/11/24/ajnr.A2361.citation>

This information is current as of April 18, 2024.

CLINICAL REPORT

L. Han
Y. Qiu
C. Xie
J. Zhang
X. Lv
W. Xiong
W. Wang
X. Zhang
P. Wu



Atypical Teratoid/Rhabdoid Tumors in Adult Patients: CT and MR Imaging Features

SUMMARY: Primary AT/RT is a rare highly malignant tumor of the CNS, usually occurring in children younger than 5 years of age. The objective of this study was to characterize the CT and MR imaging findings in a series of 5 adult patients with pathologically proved AT/RT. All 5 AT/RTs were supratentorial. In 2 patients who underwent nonenhanced CT, the tumors appeared isoattenuated, and 1 of the 2 tumors contained calcifications. Solid portions of the tumors on MR imaging were isointense on T1-weighted, T2-weighted, and FLAIR images, and 1 case showed restricted diffusion on DWI. The tumors also demonstrated a bandlike rim of strong enhancement surrounding a central cystic area on contrast-enhanced T1-weighted imaging. One tumor was associated with destruction of the calvaria. Although AT/RTs can have nonspecific findings, the tumors in our series were large and isointense on T1-weighted, T2-weighted, and FLAIR images with central necrosis and prominent rim enhancement.

ABBREVIATIONS: ADC = apparent diffusion coefficient; AT/RT = atypical teratoid/rhabdoid tumor; CNS = central nervous system; DWI = diffusion-weighted imaging; FLAIR = fluid-attenuated inversion recovery; L = left; mRNA = messenger ribonucleic acid; N/A = not available, ND = not depicted; OS = overall survival; PNET = primitive neuroectodermal tumor; PR = partial resection; R = right; TR = total resection

Although AT/RT was first described as a rare, highly malignant childhood neoplasm of the kidney, it has also been reported at several extrarenal sites including the skin, chest wall, liver, thymus, optic nerve, and the CNS.¹⁻¹⁶ When found in the CNS, it usually arises from the posterior fossa and is most commonly found in children younger than 5 years of age.¹⁷ To our knowledge, only 29 cases of primary AT/RT of the CNS in adults have been reported (On-line Table).¹⁸⁻³⁰ The On-line Table summarizes the clinical and imaging data from our patients and from those in the literature.

The prognosis of patients with an AT/RT is poor, especially in patients younger than 3 years of age, with a survival time that averages 15 months in children and 38 months in adults.^{10,18,19,24}

To our knowledge, there are only limited case reports describing the imaging features of this entity in adults.^{8,9,18,19,21-31} The goal of this study was to characterize the CT and MR imaging features of CNS AT/RT in 5 adults.

Materials and Methods

Patients

This study was approved by our institutional review board in accordance with standards of the National Institutes of Health. Five con-

secutive adult patients who received a diagnosis of AT/RT from January 2001 to October 2009 were included in the study. All patients had undergone surgical resection of their tumor and had received postoperative radiation therapy and chemotherapy. The resection specimens were collected and analyzed at 1 central pathology laboratory. Definitive diagnosis was based on histologic and immunohistochemical evaluation. The clinical and imaging characteristics of the 5 patients were analyzed, including MR images for all 5 patients and CT scans for 2 patients.

Imaging Protocol

All CT examinations were performed by using a 16-detector CT scanner (LightSpeed; GE Healthcare, Milwaukee, Wisconsin). Noncontrast axial images were obtained from the vertex to the skull base by using 2.5-mm-thick sections, a tube current of 250 mA, and a voltage of 125 kV.

All preoperative MR images were acquired by using 1 of two 1.5T MR imaging systems (Magnetom VP, Siemens, Erlangen, Germany; Gyroscan-Intera, Philips Healthcare, Best, the Netherlands). T1- and T2-weighted images and T1-weighted images with contrast administration (gadopentetate dimeglumine) were reviewed by the radiologists. For 2 patients, FLAIR images were available. A DWI sequence was performed in 1 patient.

Imaging Review

Two experienced radiologists retrospectively reviewed the CT and MR images by consensus for the location, size, presence of calcification, T1 and T2 signal-intensity characteristics, extent of vasogenic edema, and enhancement patterns.

Results

Clinical Data

The patients' clinical data (3 men and 2 women) are summarized in the On-line Table. The patients' ages ranged from 24 to 50 years (median age, 32 years). Three patients presented

Received April 12, 2010; accepted after revision June 13.

From the Departments of Medical Imaging and Interventional Radiology (L.H., C.X., P.W.), Cancer Center, Sun Yat-Sen University, Guangzhou, P.R. China; Medical Imaging Center (X.Z., Y.Q., J.Z., X.L., W.X.), Nanfang Hospital, Southern Medical University, Guangzhou, P.R. China; and Imaging Center (W.W.), Guangdong 999 Brain Hospital, Guangzhou, P.R. China.

Drs Lu Jun Han and Ying Wei Qiu contributed equally to this work.

Please address correspondence to Pei Hong Wu, MD, Departments of Medical Imaging and Interventional Radiology, Cancer Center, Sun Yat-Sen University, No. 651 Dong Feng Dong Rd, Guangzhou 510060, P.R. China; e-mail: wupeihong_2008@yeah.net; or Xue Lin Zhang, MD, Medical Imaging Center, Nanfang Hospital, Southern Medical University, No. 1838, Guangzhou Avenue North, Guangzhou 510515, P.R. China; e-mail: zhangxuelin1998@126.com

Indicates article with supplemental on-line table.

DOI 10.3174/ajnr.A2361

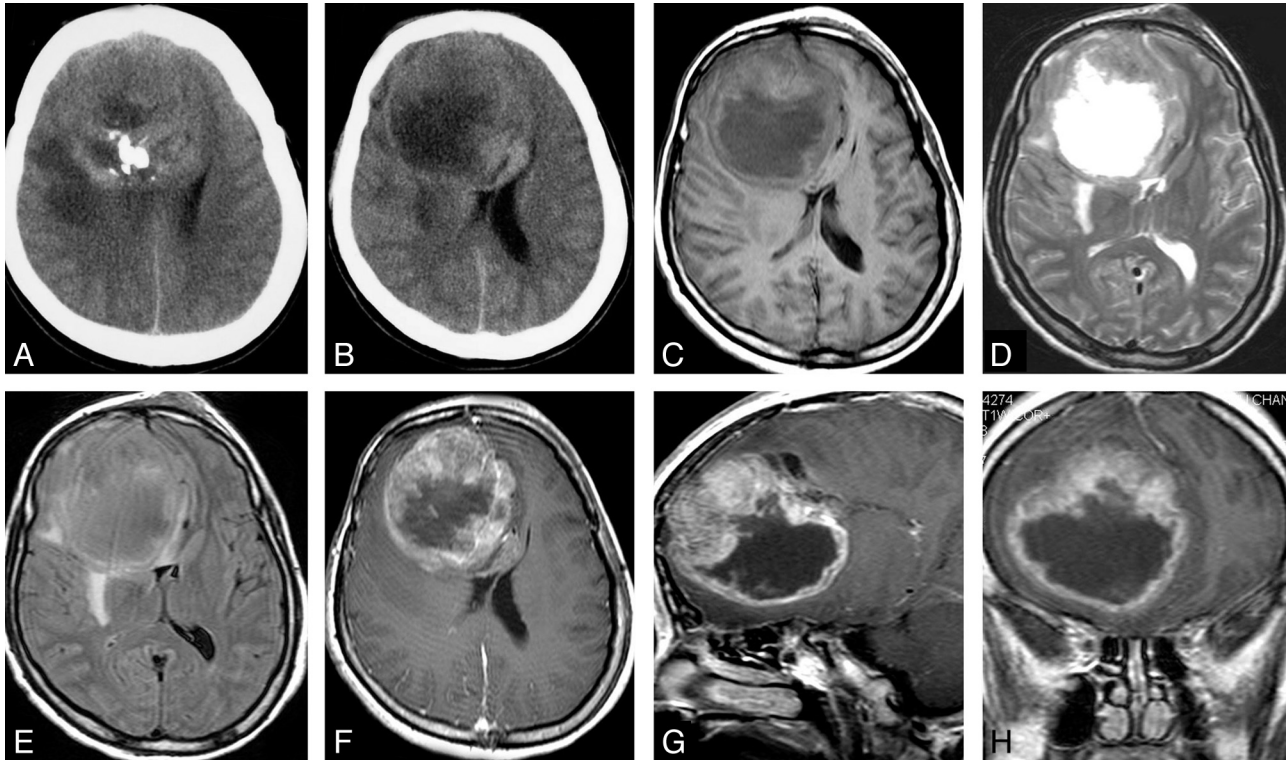


Fig 1. CT and MR images of a 35-year-old woman with AT/RT of the right frontal lobe. *A* and *B*, Axial CT images show a lesion with intermediate attenuation and multiple calcifications and zones of low attenuation. *C*, Axial T1-weighted MR image shows a lesion with marked necrosis; the necrotic component is hypointense, and the solid component is isointense. *D*, Axial T2-weighted MR image reveals a hyperintense cystic component and an isointense solid component. *E*, Axial FLAIR image demonstrates iso- and hyperintense signal intensity with mild peritumoral edema. *F–H*, Axial, sagittal, and coronal MR images show an irregular thick-walled tumor with bandlike rim ring enhancement surrounding central necrosis.

with a history of headache, 2 patients presented with nausea and vomiting, and 3 patients complained of blurred vision, epilepsy, and emotional disturbance, respectively. The course of the disease ranged from 1 month to 2 years.

Pathologic Findings

All specimens of AT/RT had histologic evidence of rhabdoid cells and were characterized by discrete cell borders and eccentric reniform nuclei, often with prominent nucleoli and eosinophilic cytoplasm. Necrosis was described in the reports of 4 lesions. The rhabdoid cells consistently displayed immunoreactivity for vimentin. Positive reactions of antibodies to epithelial membrane antigen, glial fibrillary acidic protein, smooth muscle antibody, and neurofilament protein were 80%, 80%, 60%, and 60%, respectively. The labeling index for Ki-67 was >40% in all 5 lesions. Additional cytogenetic, mRNA, or protein analyses were not performed.

Tumor Location and Size

All 5 AT/RTs were supratentorial (Figs 1–4). Two tumors were located in the right frontal lobe, and the remaining 3 tumors were located in the right temporal lobe, the left parieto-occipital lobe, and the right temporo-occipital lobe, respectively. The tumor within the right temporo-occipital lobe was associated with overlying calvarial destruction with extension into the galea.

At diagnosis, the tumors ranged from 4 to 10 cm in greatest diameter with a mean of 6.4 cm. Four tumors (80%) were >5 cm in at least 1 dimension. Only 1 tumor was <5 cm at initial presentation.

Preoperative CT and MR Imaging Characteristics

The patients' imaging findings are summarized in the On-line Table. On CT, the tumors appeared hyperattenuated compared with white matter, with a cystic/necrotic component (Figs 1A and 3A). One tumor showed lump and punctiform calcifications (Fig 1A).

Five patients had precontrast T1-weighted studies available for review. Three (60%) showed areas of both hypo- and isointensity, and 2 were hypointense. On the 5 T2-weighted studies performed, 4 (80%) showed areas of hyper- and isointensity and 1 (20%) had a mixed appearance with areas of hypo-, hyper-, and isointensity.

FLAIR images of 2 tumors before surgery were available for review. Solid portions of the tumor were iso- to slightly hyperintense ($n = 2$). Necrotic/cystic portions were iso- to slightly hyperintense ($n = 1$) (Fig 1E); the cystic portion of another tumor was hyperintense (Fig 2D).

One patient in this series had undergone preoperative DWI. The solid portion of this tumor was hyperintense on DWI relative to normal brain parenchyma, indicating restricted diffusion within this tumor. The cystic portion was hypointense on DWI and hyperintense on ADC imaging (Fig 2E, -F).

Of the 5 patients in our series, 4 (80%) had tumors that appeared relatively well-demarcated from the surrounding brain parenchyma. Contrast-enhanced T1-weighted images depicted the boundaries of the tumors most clearly. Three tumors had mild infiltration/peritumoral edema (Figs 1–3). Two had extensive adjacent edema (Fig 4).

In all 5 cases, the MR images demonstrated both solid and

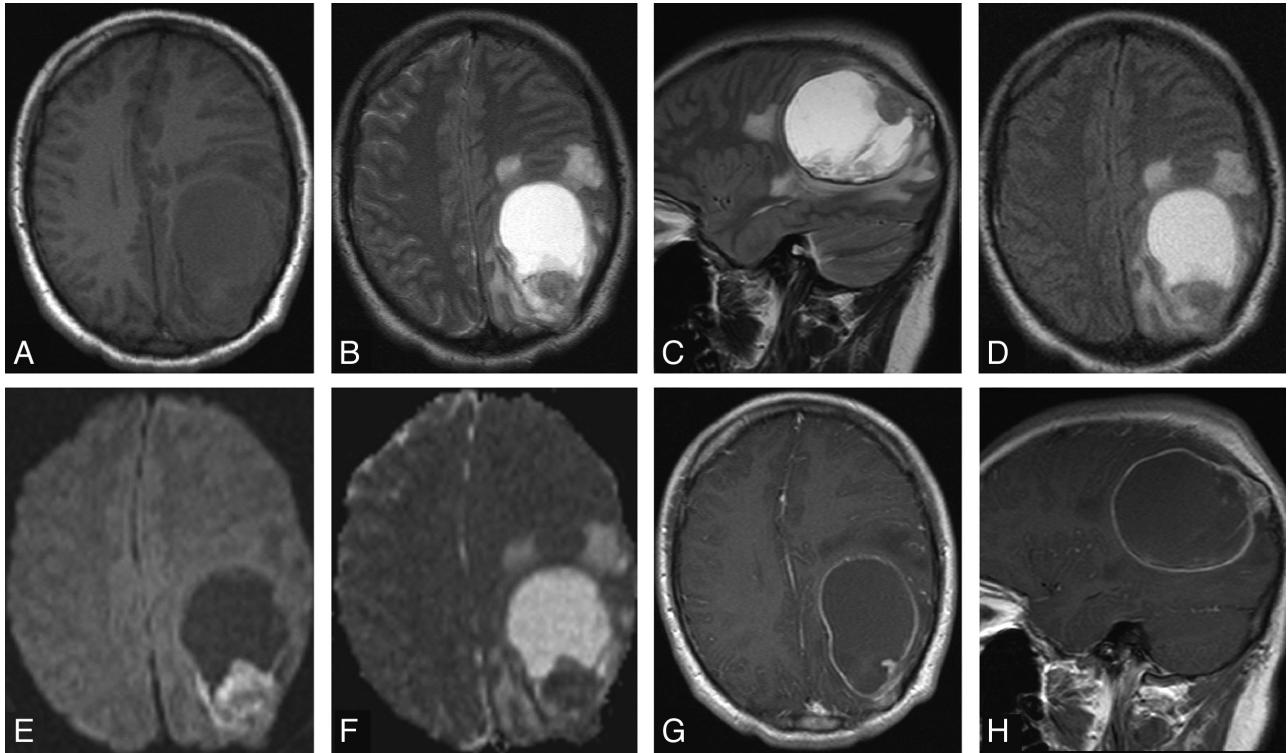


Fig 2. MR images of a 25-year-old man with AT/RT of the left parieto-occipital lobe. *A*, Axial T1-weighted MR image shows a hypointense lesion. *B* and *C*, Axial and sagittal T2-weighted MR images show a hyperintense lesion with an isointense tumor nodule. *D*, Axial FLAIR image shows a hyperintense cystic component of the lesion with mild peritumoral edema. *E* and *F*, Axial DWI and ADC MR images show the solid component to be diffusion-restricted. *G* and *H*, Axial and sagittal MR images show nodular ring enhancement surrounding central necrosis.

cystic components within the tumors. Three had obvious cystic and/or necrotic areas. All 5 patients had contrast-enhanced T1-weighted MR imaging performed, and their tumors demonstrated strong heterogeneous enhancement. In all 5 patients, an enhancement pattern consisting of a mixed solid and bandlike rim of strong enhancement surrounding a cystic or necrotic area was seen (Figs 1–4). Two tumors demonstrated nodular enhancement in the tumor walls (Fig 2). One case demonstrated intratumoral linear enhancement (Fig 3). In 1 patient, the tumor showed lobulated enhancement with calvarial destruction (Fig 4).

Patient Outcomes

All patients underwent surgical resection with 4 total resections and 1 partial resection. Postoperative adjuvant treatment consisted of aggressive chemotherapy ($n = 4$) and radiation therapy ($n = 5$). Four patients (80%) died between 10 to 25 months (mean, 17 months) after surgery. One patient was alive at 32 months after surgery with normal neurologic examination findings and follow-up MR imaging that showed no signs of tumor recurrence.

Discussion

The initial description of a rhabdoid tumor localized to the CNS was given in 1985.³² Rorke et al,¹⁶ in 1995, first characterized this tumor as an “atypical teratoid/rhabdoid tumor,” based on the disparate combination of rhabdoid, primitive neuroepithelial, epithelial, and mesenchymal components. Although most occur in infants and young children, AT/RT is being recognized in adults with increasing frequency. AT/RT was first recognized as a malignant intracranial rhabdoid tu-

mor in an adult patient in 1992 by Horn et al.³⁰ From then on, approximately 30 cases of adult AT/RT have been reported.^{18–30} In contrast to the pediatric neoplasm, most adult CNS rhabdoid tumors are supratentorial, with only 3 tumors located in the cerebellum and 2 in the spinal cord. Most cases were diagnosed on the basis of characteristic histologic and immunohistochemical features.

Atypical teratoid/rhabdoid tumor is the only nervous system tumor for which a pathognomonic alteration of a tumor-suppressor gene has been identified. Molecular studies have revealed that AT/RTs show alteration of the *INI1/hSNF5* gene on chromosome 22. This is a component of the *SWItch/Sucrose Non-Fermentable* chromatin remodeling complex and functions as a tumor suppressor by positively regulating transcription of a particular set of eukaryotic genes, possibly including the *c-Myc* target genes involved with differentiation and apoptosis.^{19,22,24} The loss of expression of *INI1* is considered to be diagnostic for AT/RT.³³ The diagnosis of AT/RT was not confirmed by cytogenetic or mRNA analysis, and this omission is a limitation of our retrospective review.

AT/RT is characterized by an aggressive clinical behavior in most children, who usually die within 7 months of initial diagnosis despite aggressive therapy.^{34,35} The behavior of the tumor in adults seems to differ somewhat in that survival time, based on current cases and literature review, averages 26 months (range, 1.5 months to 17 years). A recent report suggests that aggressive therapy, including surgery, radiation therapy, and multiagent chemotherapy designed for parameningeal rhabdomyosarcoma can significantly alter the course of the disease. More important, Zimmerman et al³⁶ have reported on the first 2 survivors treated with this modi-

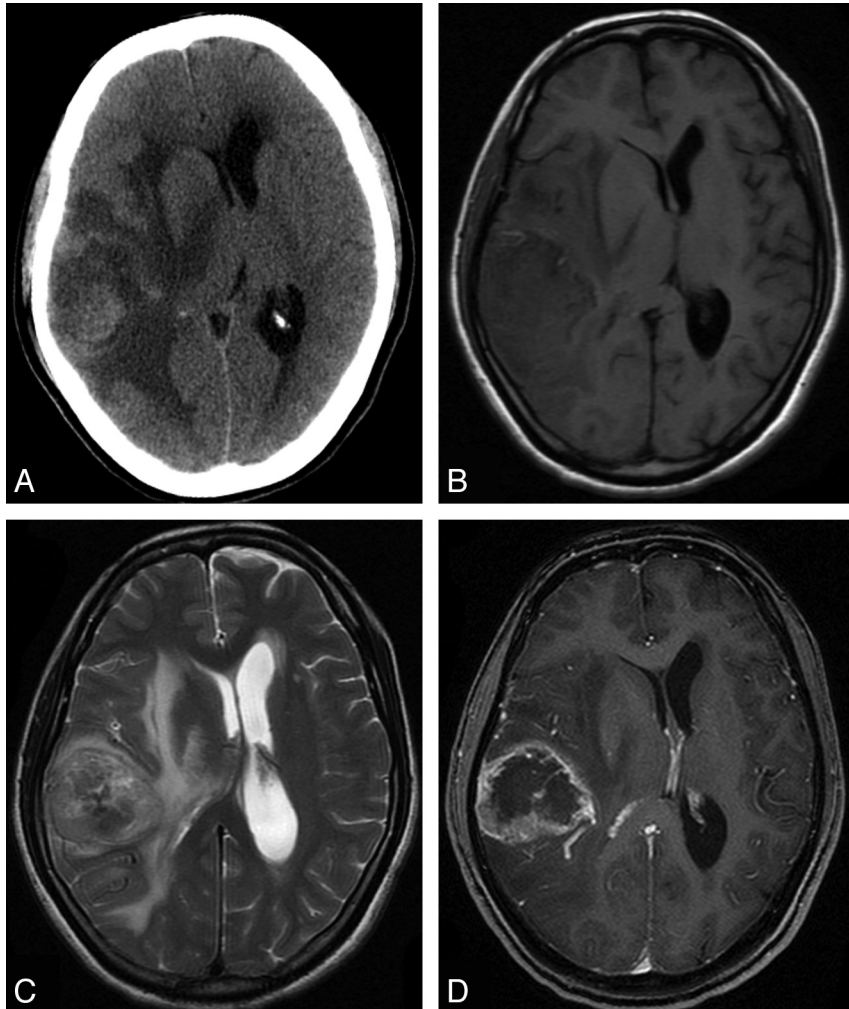


Fig 3. CT and MR images of a 50-year-old woman with AT/RT of the right temporal lobe. *A*, Axial CT image shows a lesion with intermediate attenuation and zones of low attenuation with marked peritumoral edema. *B*, Axial T1-weighted MR image shows a lesion with iso- to hypointense signal intensity with compression of the right lateral ventricle. *C*, Axial T2-weighted MR image shows a tumor with iso- to hyperintense signal intensity and with obvious edema. *D*, Axial MR image shows a tumor with an irregular thick wall, with ring and internal linear enhancement surrounding central necrosis.

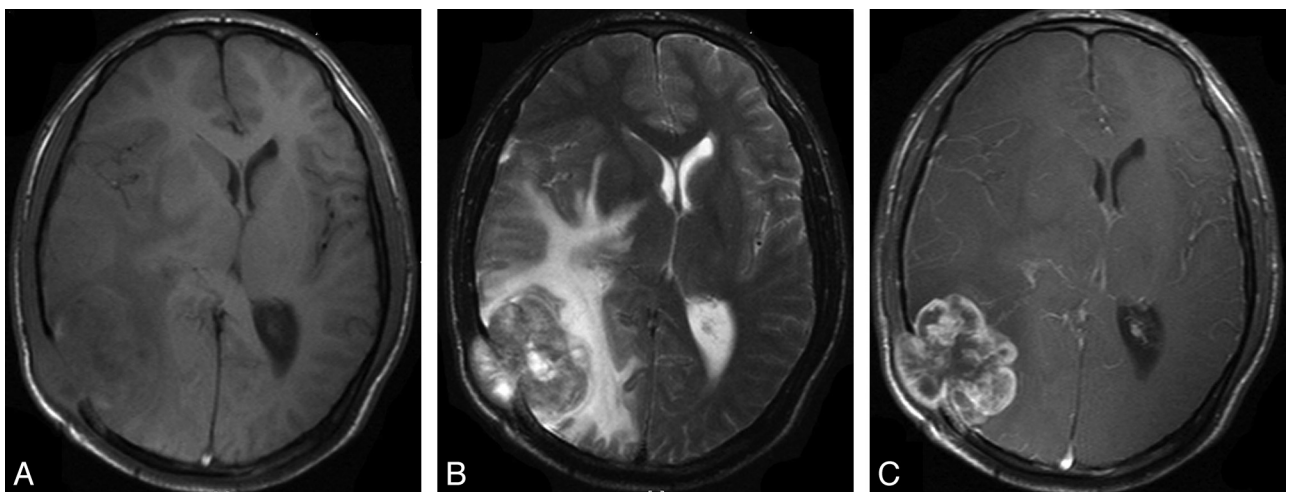


Fig 4. CT and MR images of a 24-year-old man with AT/RT of the right temporo-occipital lobe. *A*, Axial T1-weighted MR image shows a lesion with iso- to hypointense signal intensity. *B*, Axial T2-weighted MR image shows an iso- to hyperintense lesion with obvious peritumoral edema. *C*, MR image shows a tumor with irregular ring enhancement. The tumor has destroyed the overlying skull and extended into the galea.

fied regimen, after relapse with multiagent intravenous and intrathecal chemotherapy.

Imaging findings in children are usually nonspecific at the time of diagnosis. CT usually shows an isoattenuated or slightly hyperattenuated mass in relation to the normal gray matter, with mild-to-marked surrounding edema.¹ The CT findings in adults are similar to those in children.^{27,29,30} In the 2 patients in our series who underwent CT, the tumor appeared hyperattenuated, probably representing a high cellular attenuation; and the cystic/necrotic component was hypoattenuated compared with white matter. Meyers et al¹⁰ have reported that calcifications within AT/RT were seen in half of the children who underwent preoperative CT, and similar CT findings have been reported by other investigators.^{11,37} In our series, only 1 patient showed calcifications within the tumor.

According to the prior literature, MR imaging signal-intensity characteristics of the solid components of these tumors are similar to those of gray matter on T1- and T2-weighted images, and multiple necrotic or cystic foci are common.^{1,3,4,9-12,19,27} Our patients demonstrated similar imaging findings. In the 1 patient in our study who had preoperative DWI and ADC imaging, the solid portion of the tumor showed restricted diffusion.

In previous studies, AT/RT was shown to have mild-to-severe peritumoral edema. In our study, mild surrounding edema was noted in 3 patients, and 2 patients showed extensive adjacent edema.

AT/RT showed heterogeneous enhancement on our contrast-enhanced T1-weighted images. Some previous reports described AT/RT enhancement in children and adults as a bandlike wavy rim of strong and uniform enhancement completely or only partially surrounding a central cystic or necrotic area.⁴ Similar imaging findings were present in all our patients with central necrosis confirmed at the time of surgery, as well as pathology.

In children, leptomeningeal dissemination of tumor at diagnosis/initial staging has been previously reported in 21%–34% of patients with AT/RT by using myelography or enhanced MR imaging and CSF cytology.¹⁰ There was no dissemination of tumor in adult patients at the time of diagnosis in our series or in the prior literature, to our knowledge. In 1 of our patients, a right temporo-occipital tumor had destroyed the overlying calvaria extending into the galea, a feature also reported by Arslanoglu et al¹¹ and Evans et al,³⁷ which reflects the very aggressive nature of these tumors.

We considered PNET, glioblastoma, gliosarcoma, high-grade oligodendroglioma, meningioma, and metastatic disease in the differential diagnosis of our patients. Hemorrhage had been documented in many cases of PNET and in some previously reported cases of AT/RT in adult patients.^{19,27,29} Therefore, the presence of hemorrhage was not helpful in the differential diagnosis of these tumors. Some similarities in the imaging appearances of AT/RT and glioblastoma or gliosarcoma have been reported,³⁸ because those kinds of tumors have a predilection for similar sites and modes of enhancement, with calcification and destruction of the skull as key distinguishing features. Calcification had been documented in high-grade oligodendroglioma and in some cases of AT/RT in adult patients, so the presence of calcification was not helpful in the differential diagnosis of these tumors. Enhanced T1-

weighted images of most AT/RTs show heterogeneous enhancement, whereas most meningiomas often show homogeneous enhancement. The patient's age and the history of extracranial tumor can be useful in differentiating AT/RT from metastatic disease.

Conclusions

In summary, although extremely rare and usually fatal, primary AT/RT of the brain should be considered in the differential diagnosis of an aggressive intracerebral neoplasm in adults. AT/RT in an adult is often a supratentorial peripheral well-demarcated tumor with solid and cystic components and mild-to-moderate surrounding edema. In adult patients, AT/RT should be considered in the differential diagnosis of a tumor that is isointense on T1- and T2-weighted images, contains a bandlike rim of strong and uniform enhancement surrounding a central cystic area, contains calcifications on CT, and is associated with destruction of the skull. It is important to perform a total resection of such tumors followed by chemotherapy and radiation therapy to afford patients a better prognosis.

Acknowledgments

We thank J. Z. Chen for her technical assistance.

References

1. Lee IH, Yoo SY, Kim JH, et al. Atypical teratoid/rhabdoid tumors of the central nervous system: imaging and clinical findings in 16 children. *Clin Radiol* 2009;64:256–64
2. Ertan Y, Sezak M, Turhan T, et al. Atypical teratoid/rhabdoid tumor of the central nervous system: clinicopathologic and immunohistochemical features of four cases. *Childs Nerv Syst* 2009;25:707–11
3. Koral K, Gargan L, Bowers DC, et al. Imaging characteristics of atypical teratoid-rhabdoid tumor in children compared with medulloblastoma. *AJR Am J Roentgenol* 2008;190:809–14
4. Warmuth-Metz M, Bison B, Dannemann-Stern E, et al. CT and MR imaging in atypical teratoid/rhabdoid tumors of the central nervous system. *Neuroradiology* 2008;50:447–52
5. Tinsa F, Jallouli M, Douira W, et al. Atypical teratoid/rhabdoid tumor of the spine in a 4-year-old girl. *J Child Neurol* 2008;23:1439–42
6. Verma A, Morriss C. Atypical teratoid/rhabdoid tumor of the optic nerve. *Pediatr Radiol* 2008;38:1117–21
7. Tez S, Kokter A, Guler G, et al. Atypical teratoid/rhabdoid tumors: imaging findings of two cases and review of the literature. *Turk Neurosurg* 2008;18:30–34
8. Nishihira Y, Tan CF, Hirato J, et al. A case of congenital supratentorial tumor: atypical teratoid/rhabdoid tumor or primitive neuroectodermal tumor? *Neuropathology* 2007;27:551–55
9. Moeller KK, Coventry S, Jernigan S, et al. Atypical teratoid/rhabdoid tumor of the spine. *AJNR Am J Neuroradiol* 2007;28:593–95
10. Meyers SP, Khademian ZP, Biegel JA, et al. Primary intracranial atypical teratoid/rhabdoid tumors of infancy and childhood: MRI features and patient outcomes. *AJNR Am J Neuroradiol* 2006;27:962–71
11. Arslanoglu A, Aygun N, Tekhtani D, et al. Imaging findings of CNS atypical teratoid/rhabdoid tumors. *AJNR Am J Neuroradiol* 2004;25:476–80
12. Lee YK, Choi CG, Lee JH. Atypical teratoid/rhabdoid tumor of the cerebellum: report of two infantile cases. *AJNR Am J Neuroradiol* 2004;25:481–83
13. Dang T, Vassilyadi M, Michaud J, et al. Atypical teratoid/rhabdoid tumors. *Childs Nerv Syst* 2003;19:244–48
14. Yoon CS, Chuang S, Jay V. Primary malignant rhabdoid tumor of the brain: CT and MR findings. *Yonsei Med J* 2000;41:8–16
15. Zuccoli G, Izzi G, Bacchini E, et al. Central nervous system atypical teratoid/rhabdoid tumour of infancy: CT and MR findings. *Clin Imaging* 1999;23:356–60
16. Rorke LB, Packer R, Biegel J. Central nervous system atypical teratoid/rhabdoid tumors of infancy and childhood. *J Neurooncol* 1995;24:21–28
17. Rorke LB, Packer RJ, Biegel JA. Central nervous system atypical teratoid/rhabdoid tumors of infancy and childhood: definition of an entity. *J Neurosurg* 1996;85:56–65

18. Mirone G, Bouazza S, Chibbaro S, et al. **Primary malignant rhabdoid tumour of the brain in adults.** *J Clin Neurosci* 2009;16:1495–97. Epub 2009 Aug 15
19. Makuria AT, Rushing EJ, McGrail KM, et al. **Atypical teratoid rhabdoid tumor (AT/RT) in adults: review of four cases.** *J Neurooncol* 2008;88:321–30
20. Arita K, Sugiyama K, Sano T, et al. **Atypical teratoid/rhabdoid tumour in sella turcica in an adult.** *Acta Neurochir (Wien)* 2008;150:491–95, discussion 496. Epub 2008 Mar 6
21. Rezano T, Tunakan M, Kahraman A, et al. **Primary rhabdoid tumor of the brain in an adult.** *Neuropathology* 2006;26:57–61
22. Erickson ML, Johnson R, Bannykh SI, et al. **Malignant rhabdoid tumor in a pregnant adult female: literature review of central nervous system rhabdoid tumors.** *J Neurooncol* 2005;74:311–19
23. Raisanen J, Biegel JA, Hatanpaa KJ, et al. **Chromosome 22q deletions in atypical teratoid/rhabdoid tumors in adults.** *Brain Pathol* 2005;15:23–28
24. Kawaguchi T, Kumabe T, Watanabe M, et al. **Atypical teratoid/rhabdoid tumour with leptomeningeal dissemination in an adult.** *Acta Neurochir (Wien)* 2004;146:1033–38, discussion 1038
25. Pimentel J, Silva R, Pimentel T. **Primary malignant rhabdoid tumors of the central nervous system: considerations about two cases of adulthood presentation.** *J Neurooncol* 2003;61:121–26
26. Lutterbach J, Liegibel J, Koch D, et al. **Atypical teratoid/rhabdoid tumors in adult patients: case report and review of the literature.** *J Neurooncol* 2001;52:49–56
27. Arrazola J, Pedrosa I, Mendez R, et al. **Primary malignant rhabdoid tumour of the brain in an adult.** *Neuroradiology* 2000;42:363–67
28. Sugita Y, Takahashi Y, Hayashi I, et al. **Pineal malignant rhabdoid tumor with chondroid formation in an adult.** *Pathol Int* 1999;49:1114–18
29. Ashraf R, Bentley RC, Awan AN, et al. **Implantation metastasis of primary malignant rhabdoid tumor of the brain in an adult (one case report).** *Med Pediatr Oncol* 1997;28:223–27
30. Horn M, Schlote W, Lerch KD, et al. **Malignant rhabdoid tumor: primary intracranial manifestation in an adult.** *Acta Neuropathol* 1992;83:445–48
31. Kuge A, Kayama T, Tsuchiya D, et al. **Suprasellar primary malignant rhabdoid tumor in an adult: a case report** [in Japanese]. *No Shinkei Geka* 2000;28:351–58
32. Montgomery P, Kuhn JP, Berger PE. **Rhabdoid tumor of the kidney: a case report.** *Urol Radiol* 1985;7:42–44
33. Hoot AC, Russo P, Judkins AR, et al. **Immunohistochemical analysis of hSNF5/INI1 distinguishes renal and extra-renal malignant rhabdoid tumors from other pediatric soft tissue tumors.** *Am J Surg Pathol* 2004;28:1485–91
34. Packer RJ, Biegel JA, Blaney S, et al. **Atypical teratoid/rhabdoid tumor of the central nervous system: report on workshop.** *J Pediatr Hematol Oncol* 2002;24:337–42
35. Lath R, Unosson D, Blumbergs P, et al. **Rhabdoid glioblastoma: a case report.** *J Clin Neurosci* 2003;10:325–28
36. Zimmerman MA, Goumnerova LC, Proctor M, et al. **Continuous remission of newly diagnosed and relapsed central nervous system atypical teratoid/rhabdoid tumor.** *J Neurooncol* 2005;72:77–84
37. Evans A, Ganatra R, Morris SJ. **Imaging features of primary malignant rhabdoid tumour of the brain.** *Pediatr Radiol* 2001;31:631–33
38. Han LJ, Zhang XL, Qiu SJ, et al. **Magnetic resonance imaging of primary cerebral gliosarcoma: a report of 15 cases.** *Acta Radiol* 2008;49:1058–67