

Are your **MRI contrast agents** cost-effective?

Learn more about generic **Gadolinium-Based Contrast Agents**.



AJNR

Is It Possible to Recognize Cervical Artery Dissection on Stroke Brain MR Imaging? A Matched Case-Control Study

O. Naggara, F. Soares, E. Touze, D. Roy, X. Leclerc, J.-P. Pruvo, J.-L. Mas, J.-F. Meder and C. Oppenheim

This information is current as of April 18, 2024.

AJNR Am J Neuroradiol published online 14 April 2011
<http://www.ajnr.org/content/early/2011/04/14/ajnr.A2553>

ORIGINAL
RESEARCH

O. Naggara
F. Soares
E. Touze
D. Roy
X. Leclerc
J.-P. Pruvo
J.-L. Mas
J.-F. Meder
C. Oppenheim

Is It Possible to Recognize Cervical Artery Dissection on Stroke Brain MR Imaging? A Matched Case-Control Study

BACKGROUND AND PURPOSE: Extracranial CAD accounts for nearly 20% of cases of stroke in young adults. The mural hematoma frequently extends cranially to the petrous carotid segment in cCAD or is distally located in vCAD. We hypothesized that standard brain MR imaging could allow the early detection of CAD of the upper portion of carotid and vertebral arteries.

MATERIALS AND METHODS: Our prospectively maintained stroke data base was retrospectively queried to identify all patients with the final diagnosis of CAD. In the 103 consecutive patients studied, analysis of cervical fat-suppressed T1-weighted sequences demonstrated that the mural hematoma was located in the FOV of brain MR imaging in 77 patients. Subsequent to enrollment of a patient, a control patient was extracted from the same data base, within a similar categories for sex, age, NIHSS score, and stroke on DWI. Two blinded observers independently reviewed the 5 brain MR sequences of each examination and determined whether a CAD was present.

RESULTS: Fifty-nine of the 77 patients with CAD (76.6%) and 73 of the 77 patients without CAD (94.8%) were correctly classified. Brain MR imaging demonstrated cCAD more frequently than vCAD in 54/58 (93.1%) and 5/19 (26.3%) patients, respectively, ($P < .0001$).

CONCLUSIONS: Initial brain MR imaging can correctly suggest CAD in more than two-thirds of patients. This may have practical implications in patients with stroke with delayed cervical MRA or in those who are not initially suspected of having CAD.

ABBREVIATIONS: CAD = cervical artery dissection; cCAD = carotid artery dissection; CE = contrast-enhanced; DSA = digital subtraction angiography; DWI = diffusion-weighted imaging; FLAIR = fluid-attenuated inversion recovery; ICA = internal carotid artery; INSERM = Institut National de la Santé et de la Recherche Médicale; MRA = MR angiography; MRI = MR imaging; NIHSS = National Institutes of Health Stroke Scale; PWI = perfusion-weighted imaging; STARD = Standards for Reporting of Diagnostic Accuracy; TIA = transient ischemic attack; vCAD = vertebral artery dissection

Extracranial CAD accounts for nearly 20% of cases of stroke in young adults.^{1,2} Conclusive evidence of CAD early in the diagnosis of stroke would allow rapid deployment of therapy to reduce the risk of further thromboembolic events.³ Most patients with neurologic deficits undergo a brain MR imaging examination as part of their standard etiologic work-up, first, because DWI surpasses CT for the detection of acute ischemia and, second, because MR images accompanying DWI are more effective than CT for excluding stroke mimics.⁴ Imaging focused on the head provides a truncated view of the arterial vasculature and is not systematically followed by an evaluation of extracranial arteries. Indeed, despite stroke guidelines,⁴ only approximately one-fourth of patients with stroke had

carotid imaging within 2 weeks of the event,^{5,6} because of the differing availability of cervical artery imaging between institutions. Furthermore, cervical MRA is not part of the work-up of all patients who are not initially suspected of having CAD based on available history. Thus, patients with CAD may be undiagnosed and sustain additional infarctions before the dissection is discovered. In CAD, the mural hematoma frequently extends cranially to the petrous carotid segment in the case of cCAD or is distally located in the case of vCAD. These locations are within the limits of the FOV of standard brain MR imaging. We hypothesized that standard brain MR imaging could allow the early detection of CAD of the upper portion of the carotid and vertebral arteries.

Received July 2, 2010; accepted after revision September 12.

From the Departments of Neuroradiology (O.N., F.S., J-F.M., C.O.) and Neurology (E.T., J-L.M.), Paris-Descartes University, INSERM U894, Centre Hospitalier Sainte-Anne, Paris, France; Interventional Neuroradiology Research Unit (D.R.), Centre hospitalier de l'Université de Montréal, Notre-Dame Hospital, University of Montreal, Quebec, Canada; and Department of Neuroradiology (J-P.P., X.L.), Lille University Hospital Roger Salengro, Lille, France.

O.N., F.S., J-F.M., and C.O. planned the study data collection and identified the patient cohort; O.N. and F.S. gathered the data; and O.N., E.T., and C.O. did the statistical analysis. O.N., E.T., D.R., J-P.P., J-L.M., and X.L. drafted the manuscript. All authors read and approved the final manuscript.

Please address correspondence to Olivier Naggara, MD, Department of Neuroradiology, Centre Hospitalier Sainte-Anne, 1 rue Cabanis, 75014 Paris, France; e-mail: o.naggara@ch-sainte-anne.fr

DOI 10.3174/ajnr.A2553

Materials and Methods

Patients

The study was approved by the Ethics Committee of Ile de France III and was found to conform to generally accepted scientific principles and research ethics standards. Informed consent was waived. The manuscript was prepared in accordance with the STARD guidelines.⁷ Our case-control study was nested within a longitudinal cohort of patients referred to our institution for suspected acute stroke or TIA, between January 2002 and December 2007. This prospectively maintained data base was retrospectively queried to identify all consecutive patients with the final diagnosis of CAD ($n = 125$). CAD diagnosis

Table 1: Patient characteristics

	77 Patients with CAD	77 Controls	P
Age (yr, mean)	45.7 ± 9.2	45.0 ± 9.5	0.65
Male (%)	49 (63.6)	49 (63.6)	1
NIHSS score (mean)	3.2 ± 4.9	3.4 ± 5.4	0.85
Stroke on DWI	41	41	1
Brain MRI <3 hr	6	7	1

was based on ≥ 1 of the following criteria: 1) intimal flap or mural hematoma visible on cervical Doppler sonography ($n = 94$), 2) mural hematoma visible on cervical axial fat-suppressed T1-weighted imaging ($n = 125$), and 3) a nonatherosclerotic tapered flame-shaped occlusion ($n = 42$) or a stringlike stenosis ($n = 69$) on CE-MRA ($n = 122$) or conventional DSA ($n = 3$). One hundred three patients with a total of 130 CADs met the following inclusion criteria: 1) brain MR imaging examinations in DICOM format, and 2) cervical axial fat-suppressed T1-weighted and CE-MRA or DSA. Twenty-two patients were thus excluded (contraindication or no MR imaging examination, $n = 9$; no DICOM format, $n = 13$). In the 103 patients studied, analysis of axial cervical fat-suppressed T1-weighted sequences—from the aortic arch proceeding to the foramen magnum—demonstrated that the mural hematoma was located in the lower part of the FOV of brain MR images (the petrous segment of the ICA, the V3 segment of the vertebral artery) in 77 patients (74.8%; age range, 23–66 years) with 88 CADs (67.7%; 67 cCADs, 21 vCADs) (Table 1 and Fig 1). The other 26 patients with 42 dissected arteries vertebral segment, $n = 6$; V2 vertebral segment, $n = 15$; cervical carotid arteries, $n = 21$) were excluded. To evaluate the validity of CAD detection, we extracted 77 control patients from the same data base until 1 control patient was individually matched to each case patient, within corresponding sex, age, NIHSS score, and stroke on DWI categories. Controls met the following inclusion criteria: 1) brain MR imaging examinations in DICOM format, and 2) identified etiology for neurologic deficit other than CAD. The final study group included 154 patients (98 men, 56 women; mean age, 45.4 ± 9.4 years; age range, 23–66 years).

MR Imaging

All brain MR imaging examinations were performed on a 1.5T Signa MR imaging unit (GE Healthcare, Milwaukee, Wisconsin) by using a standardized protocol: 6-mm-thick sagittal T1-weighted imaging (TR/TE, 230/5.1 ms; matrix, 320×224 ; acquisition time, 40 seconds), located from 1 mastoid process to the other; 6-mm-thick bicommissural axial FLAIR imaging (TR/TE/TI, 9802/159.1/2300 ms; matrix, 256×192 ; acquisition time, 2 minutes 18 seconds); gradient recalled-echo T2-weighted imaging (TR/TE, 480/13 ms; matrix, 256×224 ; flip angle, 25°; acquisition time, 1 minute 25 seconds); DWI using spin-echo echo-planar imaging (TR/TE, 5000/88.2 ms; matrix, 128×128 ; acquisition time, 48 seconds); and 3D time-of-flight angiography of the circle of Willis (TR/TE, 27/3.6 ms; acquisition bandwidth, 25 kHz; flip angle, 20°; FOV, $240 \times 240 \times 65$ mm; matrix, 256×256 ; acquisition time, 2 minutes 56 seconds; single-slab acquisition segmented in 93 contiguous axial sections 0.7 mm thick), located from the vertex to the upper part of the second cervical vertebra.

Image Analysis

Intracranial MR imaging examinations were anonymized and randomly numbered. Two blinded observers independently reviewed the 5 brain MR sequences of each examination on a dedicated workstation (Advantage Windows 4.1, GE Healthcare). Each sequence data set was read separately and randomly analyzed in 2 different sessions separated by at least 2 months to minimize recall bias. Observers had to search for a crescentic hypersignal of the carotid or vertebral wall and for an increased external diameter (Fig 2). They had to conclude, for each sequence, whether a CAD was present. If by the end of the readings at least 3 sequences were positive, CAD was diagnosed. The standard of reference for CAD detection was represented by the consensus reading of the 2 observers, performed 2 months after the initial interpretation.

Statistical Analysis

The Statistical Package for the Social Sciences software (Version 15.0; SPSS, Chicago, Illinois) was used for the analysis. The Mann-Whitney

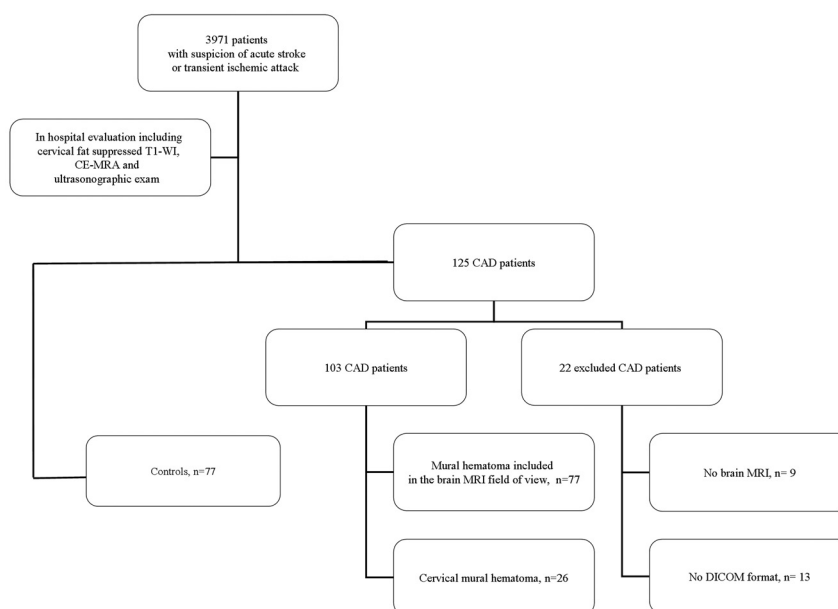


Fig 1. Flow chart showing inclusion of patients.

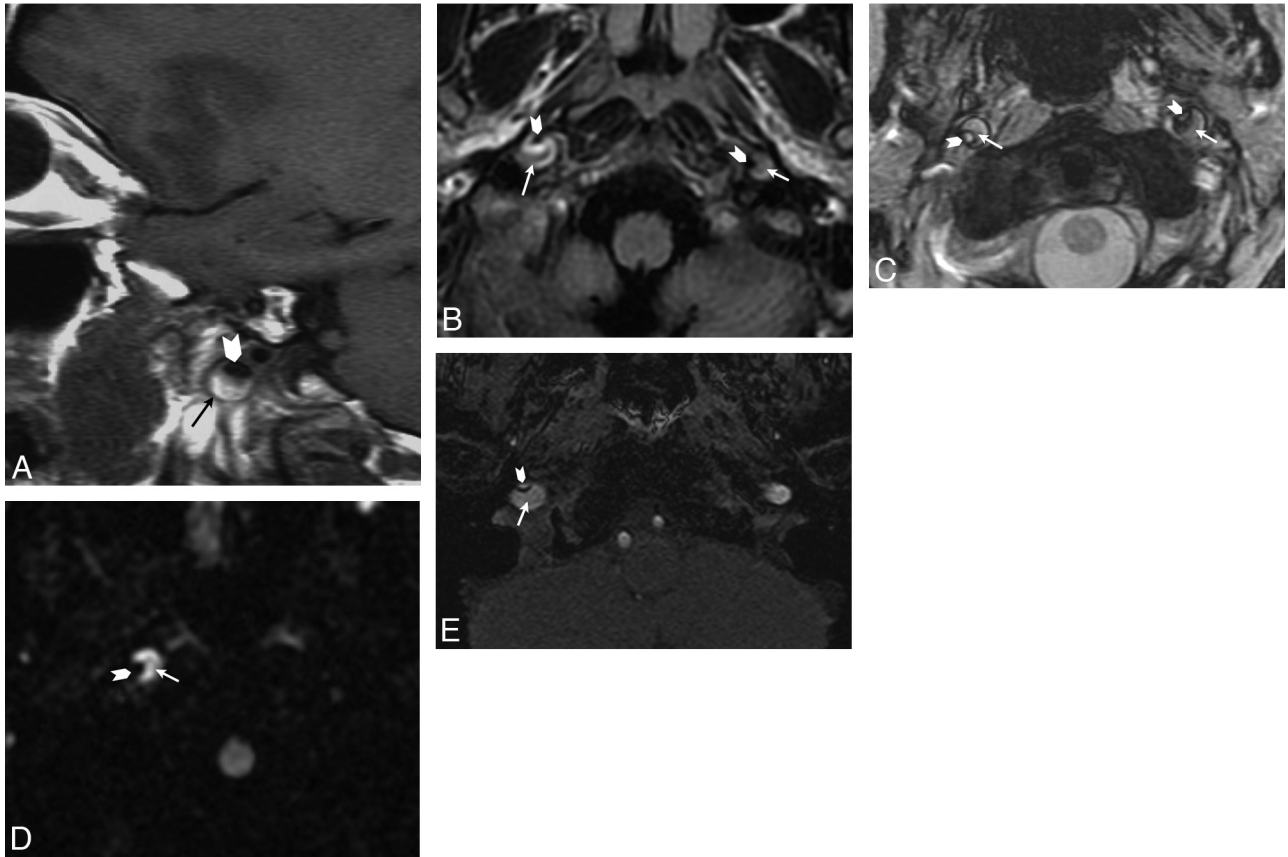


Fig 2. Illustration of CAD on brain MR imaging sequences. *A*, Sagittal T1-weighted image in a 42-year-old woman with left ICA dissection. *B* and *C*, Axial FLAIR (*B*) and gradient-recalled-echo T2-weighted (*C*) images in a 45-year-old man with bilateral ICA dissection. *D* and *E*, Axial DWI (*D*) and native sections of 3D time-of-flight angiography of the circle of Willis (*E*) in a 38-year-old man with right ICA dissection. Note the increased external diameter, crescentic mural thickening (arrows), and eccentric lumen (arrowheads) of the dissected ICA in all 3 patients.

U test and the Fisher exact test were used to compare, respectively, continuous parametric variables (age, NIHSS score) and categorical variables (sex, stroke on DWI sequence) between the 2 populations. Simple κ coefficients and their 95% confidence intervals were used to assess inter- and intraobserver agreement. We calculated the sensitivity of brain MR imaging in patients with and without CAD and compared the detection rate in cCAD and vCAD. We also compared the detection rate of CAD in occluded and nonoccluded arteries and in MR imaging performed >3 hours after the onset of symptoms versus within the first 3 hours after the onset of symptoms. We further compared the consensus reading with the radiologic report of each brain MR imaging. A 2-sided *P* value < .05 was considered statistically significant.

Results

Cases and controls did not differ significantly for clinical, demographic, and stroke status on DWI data (Table 1). Among the 77 patients and 88 CADs (67 cCADs and 21 vCADs), 58 patients (75.3%) had 64 cCADs (72.7%), 17 (22.1%) patients had 18 vCADs (20.5%), 2 patients (2.3%) had both cCAD and vCAD (6.8%, 3 cCADs and 3 vCADs). Inter- and intraobserver agreement was excellent ($\kappa = 0.87$, 95% confidence intervals: 0.57–0.94, and $\kappa = 0.91$, 95% confidence intervals: 0.56–0.96, respectively). Fifty-nine of the 77 patients with CAD (76.6%) and 73 of the 77 patients without CAD (94.8%) were correctly classified (Table 2). Only 18 of the 77 patients

with CAD (23.4%) had been correctly diagnosed according to the initial brain MR imaging report. Brain MR imaging demonstrated cCAD more frequently than vCAD (54/58, 93.1%, and 5/19, 26.3%, respectively; *P* < .0001). In 6 patients with CAD and 7 without it, MR imaging was performed within 3 hours after onset, with a correct classification in 83.3% and 100% of cases, respectively (not significant) (Table 2). In cases of occlusion, patients with and without CAD were correctly classified in 28/32 (87.5%) and 22/25 (88%) cases, respectively (not significant).

Table 2: Detection rate of CAD in 77 patients and 77 controls

	Overall No. (%)	No. of Patients (%)	No. of Controls (%)	<i>p</i>
Correct rating	132/154 (85.7)	59/77 (76.6)	73/77 (94.8)	.002
cCAD	–	54/58 (93.1)	–	<.0001
vCAD	–	5/19 (26.3)	–	
Onset to MRI <3 hr	12/13 (92.3)	5/6 (83.3)	7/7 (100)	.5
cCAD	–	5/6 (83.3)	–	
vCAD	–	0	–	
Onset to MRI >3 hr	120/141 (85.7)	54/71 (76.0)	66/70 (94.3)	.004
cCAD	–	49/52 (94.2)	–	
vCAD	–	5/19 (26.3)	–	
Occlusion	50/57 (87.7)	28/32 (87.5)	22/25 (88)	1
Stenosis or irregularity	82/97 (84.5)	31/45 (68.9)	51/52 (98.1)	<.0001

Discussion

The main findings of this case-control study were as follows: 1) Nearly 75% CADs were included within the FOV of brain MR imaging; and 2) more than three-quarters of such acute CADs could be diagnosed by using brain MR imaging only. These results might have clinical implications for patients who are not initially suspected of having CAD on the basis of available history at the time of protocol and at institutions where cervical CE-MRA is not coupled with MR brain imaging. Despite stroke imaging recommendations, cervical imaging is frequently delayed, with only half of patients with stroke having undergone carotid imaging within 12 weeks after the stroke event.⁶ In 2 prospective population-based studies, the median (interquartile range) times from the presenting event (stroke or TIA) to carotid imaging was 33 (12–62) days.⁵ Consequently, stroke brain MR imaging can contribute to a better and earlier identification of CAD in patients with stroke.

The fact that the readers performed significantly better than the radiologists in the initial brain MR imaging report (77% versus 23%) supports the contention that the interpretation of direct signs of CAD on brain MR imaging is a learnable skill; the excellent interobserver agreement between a senior neuroradiologist and a resident with <3 months' experience in neuroimaging demonstrates that the interpretation of highly conspicuous imaging findings requires little specialized training and can also be achieved in regular clinical practice.

Although several studies have described the proximal anatomic location of spontaneous CAD, albeit with conflicting results,^{8,9} data on the cranial extension of the mural hematoma are scarce. In the present study, we report that the mural hematoma extended in the cranial direction, involving the V3 segment or the petrous segment of the ICA in nearly 75% of CADs. This has to be kept in mind in clinical practice, because a possible intracranial extension of CAD should be considered before beginning an anticoagulant treatment. For patients with CAD and severe and sudden headache, many authors consider a lumbar puncture mandatory, to rule out a subarachnoid hemorrhage.¹⁰

Ischemic stroke in CAD can be preceded by at least 1 TIA in 10%–15% of patients, with latencies between stroke and TIA of ≤ 17 days.¹⁰ This group is of particular interest because patients with TIA are increasingly examined with brain MR imaging. The stroke may be prevented by immediate recognition of the CAD signs on brain MR imaging and initiation of antithrombotic or anticoagulation treatment.³

Mural hematoma can be definitely recognized on brain MR imaging even in the case of occlusion or in thrombolysis-eligible patients. In the latter case, it is important to avoid any delay in initiating treatment as a result of artery imaging. Some data suggest that an occluded large intracranial vessel is less likely to be recanalized by intravenous fibrinolysis alone if the parent cervical lumen is occluded or severely reduced.¹¹ Several studies on retrospective nonrandomized series^{12–15} have reported the outcome in patients with hyperacute stroke due to CAD, with both cervical occlusion or high-grade stenosis and intracranial occlusion treated by stent-assisted endovascular thrombolysis or thrombectomy. Such endovascular treatments were reportedly safe and effective and compared favorably with intravenous recombinant tissue plasminogen

activator.¹⁴ Thus, in institutions that have chosen MR imaging as the prime screening imaging technique in hyperacute stroke, standard brain MR imaging may reveal specific signs of CAD, thereby enabling faster triage of those patients who may derive the greatest benefit from endovascular thrombolysis.

Although the mismatch hypothesis has not yet been tested conclusively,¹⁶ penumbral selection, PWI, is being used to screen patients for acute thrombolytic therapy.¹⁷ The clinical constellation of a large middle cerebral artery stroke with a substantial mismatch between DWI and PWI in the 3- to 6-hour time window is for many stroke neurologists an indication for the off-label use of intravenous tissue plasminogen activator. Cervical CAD may lead to a misinterpretation of the PWI. A mismatch between a larger PWI abnormality, due to reduced lumen of the dissected artery, and a smaller DWI lesion, due to an embolic small-vessel stroke, may erroneously identify patients as being suitable candidates for recanalization therapies.

Our study has several limitations. First, it is unlikely to obviate cervical imaging if stroke brain MR imaging does not demonstrate any mural hematoma. Second, this analysis was retrospective and only 1 control was associated with each case, resulting in a population with a prevalence of 50% dissection. Third, the delay from onset to brain MR imaging was heterogeneous, with <10% of patients imaged within the first 3 hours after onset. Another potential limitation is that some patients with an extracranial arterial dissection were missed, because an intimal tear may occur and extend without mural hematoma.

Conclusions

Stroke brain MR imaging can allow early detection of CAD before dedicated imaging of the cervical arteries is performed. Although the absence of mural hematoma does not completely rule out CAD and does not obviate cervical imaging, stroke brain MR imaging can contribute to a better and earlier identification of patients with stroke who are suitable candidates for anticoagulation treatment or revascularization therapy. These results serve to remind neuroradiologists and general radiologists that much information can be derived from stroke brain MR imaging.

References

1. Schievink WI. Spontaneous dissection of the carotid and vertebral arteries. *N Engl J Med* 2001;344:898–906
2. Debette S, Leys D. Cervical-artery dissections: predisposing factors, diagnosis, and outcome. *Lancet Neurol* 2009;8:668–78
3. Engelter ST, Brandt T, Debette S, et al. Antiplatelets versus anticoagulation in cervical artery dissection. *Stroke* 2007;38:2605–11
4. Latchaw RE, Alberts MJ, Lev MH, et al. Recommendations for imaging of acute ischemic stroke: a scientific statement from the American Heart Association. *Stroke* 2009;40:3646–78
5. Fairhead JF, Mehta Z, Rothwell PM. Population-based study of delays in carotid imaging and surgery and the risk of recurrent stroke. *Neurology* 2005;65:371–75
6. Halliday AW, Lees T, Kamugasha D, et al. Waiting times for carotid endarterectomy in UK: observational study. *BMJ* 2009;338:b1847
7. Bossuyt PM, Reitsma JB, Bruns DE, et al. Towards complete and accurate reporting of studies of diagnostic accuracy: the STARD initiative. *Radiology* 2003;226:24–28
8. Mokri B, Houser OW, Sandok BA, et al. Spontaneous dissections of the vertebral arteries. *Neurology* 1988;38:880–85
9. Provenzale JM, Morgenlander JC, Gress D. Spontaneous vertebral dissection:

- clinical, conventional angiographic, CT, and MR findings. *J Comput Assist Tomogr* 1996;20:185–93
10. Arnold M, Bousser MG, Fahrni G, et al. **Vertebral artery dissection: presenting findings and predictors of outcome.** *Stroke* 2006;37:2499–503
 11. Zangerle A, Kiechl S, Spiegel M, et al. **Recanalization after thrombolysis in stroke patients: predictors and prognostic implications.** *Neurology* 2007;68:39–44
 12. Georgiadis D, Lanczik O, Schwab S, et al. **IV thrombolysis in patients with acute stroke due to spontaneous carotid dissection.** *Neurology* 2005;64:1612–14
 13. Derex L, Nighoghossian N, Turjman F, et al. **Intravenous TPA in acute ischemic stroke related to internal carotid artery dissection.** *Neurology* 2000;54:2159–61
 14. Lavalley PC, Mazighi M, Saint-Maurice JP, et al. **Stent-assisted endovascular thrombolysis versus intravenous thrombolysis in internal carotid artery dissection with tandem internal carotid and middle cerebral artery occlusion.** *Stroke* 2007;38:2270–74
 15. Baumgartner RW, Georgiadis D, Nedeltchev K, et al. **Stent-assisted endovascular thrombolysis versus intravenous thrombolysis in internal carotid artery dissection with tandem internal carotid and middle cerebral artery occlusion.** *Stroke* 2008;39:e27–28
 16. Schabitz WR. **MR mismatch is useful for patient selection for thrombolysis: No.** *Stroke* 2009;40:2908–09
 17. Hacke W, Albers G, Al-Rawi Y, et al. **The desmoteplase in acute ischemic stroke trial (DIAS): a phase II MRI-based 9-hour window acute stroke thrombolysis trial with intravenous desmoteplase.** *Stroke* 2005;36:66–73