

Are your **MRI contrast agents** cost-effective?

Learn more about generic **Gadolinium-Based Contrast Agents**.



**FRESENIUS
KABI**

caring for life

AJNR

**Nonbifurcating Cervical Carotid Artery
Diagnosed by MR Angiography**

A. Uchino, N. Saito, T. Watadani, W. Mizukoshi and R.
Nakajima

AJNR Am J Neuroradiol published online 26 May 2011
<http://www.ajnr.org/content/early/2011/05/26/ajnr.A2462>

This information is current as
of April 18, 2024.

ORIGINAL
RESEARCHA. Uchino
N. Saito
T. Watadani
W. Mizukoshi
R. NakajimaNonbifurcating Cervical Carotid Artery Diagnosed
by MR Angiography

BACKGROUND AND PURPOSE: A nonbifurcating cervical carotid artery is a branching anomaly in which the ECA has no proximal main trunk. We report its incidence and characteristic features on MRA.

MATERIALS AND METHODS: We retrospectively reviewed MRAs of 2866 patients obtained by using a standard noncontrast MRA protocol and two 1.5T MR imaging units and reviewed the English language literature to assess the occurrence and features of this nonbifurcating artery.

RESULTS: We diagnosed 6 cases, indicating an incidence of 0.21%, and found 11 cases reported in the literature. Analysis of all 17 cases demonstrated no laterality or sex predominance. The most prevalent pattern of branching order from proximal to distal was the F-L trunk, the distal trunk of the ECA, and the OA.

CONCLUSIONS: A nonbifurcating cervical carotid artery is rare but not as extremely rare as previously considered, and its correct diagnosis is necessary to avoid complications during interventional radiologic procedures or head and neck surgeries.

ABBREVIATIONS: APA = ascending pharyngeal artery; CCA = common carotid artery; DSA = digital subtraction angiography; ECA = external carotid artery; FA = facial artery; F-L = facial-lingual; ICA = internal carotid artery; LA = lingual artery; MIP = maximum intensity projection; MRA = MR angiography; OA = occipital artery; TOF = time-of-flight; VA = vertebral artery

Rarely, the major branches of the proximal ECA, such as the LA, FA, distal trunk of the ECA, or OA, arise separately from the terminal segment of the CCA or proximal ICA, resulting in the ECA having no proximal main trunk. This anomaly is called a nonbifurcating cervical carotid artery and may be caused by segmental agenesis of the most proximal ICA. Only 11 cases have been reported in the English language literature.¹⁻⁹ This anomaly is also called “unilateral”² or “congenital absence of the ECA.”⁶ We believe that this is the first report of this anomaly studied with MRA.

Materials and Methods

In accordance with the policies for exemption set by our internal institutional review board, we retrospectively reviewed images of the supra-aortic region from 5319 MRA examinations performed in 3626 patients in our institution from April 1, 2007, through December 31, 2009. Most of the examined patients had or were suspected of having ischemic cerebrovascular diseases. From these, we excluded from our study 625 patients who had not undergone examination of the extracranial region and 135 with unilateral or bilateral occlusion of the ICA or suboptimal image quality. Patients who previously underwent surgical ligation of the proximal ECA were not included. We ultimately reviewed and analyzed MRAs of 2866 patients (1696 men, 1170 women). Informed consent was not obtained because of the retrospective nature of the clinical study.

All patients were examined on either of two 1.5T scanners (Achieva Nova Dual, Philips Healthcare, Best, the Netherlands; and Magnetom Avanto, Siemens, Erlangen, Germany). Standard 3D TOF

MRA protocol was the following: TR, 20 ms; TE, 6.0 ms; flip angle, 16°; FOV, 20 × 20 cm; and section thickness, 0.65 mm for the Achieva Nova Dual, with an acquisition time, 5 minutes 30 seconds; and TR, 22 ms; TE, 7.0 ms; flip angle, 18°; FOV, 22 × 22 cm; and section thickness, 0.7 mm, with an acquisition time of 7 minutes 34 seconds for the Magnetom Avanto. Contrast-enhanced MRAs were not included.

The first author, an experienced neuroradiologist, retrospectively reviewed all MRAs with special attention paid to the pattern of carotid bifurcation. Our diagnostic criterion for a nonbifurcating cervical carotid artery was at least 2 branches of the ECA arising separately from a cervical carotid artery with no physiologic dilation of the origin of the ICA. Thus, we excluded patients with the LA arising from the distal CCA or with the OA arising from the proximal ICA.

Results

We diagnosed 6 cases of nonbifurcating cervical carotid artery among 2866 patients by using MRA (Table 1): 5 cases among 1696 men (incidence, 0.29%) and 1 case among 1170 women (incidence, 0.09%). The overall incidence was 0.21%. This affected 4 right and 2 left carotid arteries. In 4 patients, the pattern of branching order from proximal to distal was the F-L trunk, distal trunk of the ECA, and OA (Fig 1); in 1 patient, the pattern was the LA, the common trunk of the FA and ECA, and the OA; and in the remaining patient, the LA and common trunk of the FA and ECA arose from the carotid artery, but the OA arose from the VA (Fig 2). Conventional angiography was performed in only 1 of the 6 patients, in a patient with occlusion of the middle cerebral artery.

Discussion

We diagnosed 6 cases of nonbifurcating cervical carotid artery among 2866 patients. The incidence of 0.21% in our study was low, but it was almost the same as the reported 0.2% incidence of the persistent trigeminal artery, the most common type of

Received August 27, 2010; accepted after revision November 2.

From the Department of Diagnostic Radiology, Saitama Medical University International Medical Center, Saitama, Japan.

Please address correspondence to Akira Uchino, MD, Department of Diagnostic Radiology, Saitama Medical University International Medical Center, 1397-1 Yamane, Hidaka, Saitama 350-1298, Japan; e-mail: auchino@saitama-med.ac.jp

DOI 10.3174/ajnr.A2462

Table 1: Nonbifurcating cervical carotid artery in this study

Case No./Age (yr)/Sex/Left or Right	Branching Order (Proximal to Distal)	Diagnostic Modality
1/76/F/left	F-L trunk, main trunk of ECA, OA	MRA
2/60/M/left	F-L trunk, main trunk of ECA, OA	MRA
3/78/M/right	F-L trunk, main trunk of ECA, OA	MRA
4/72/M/right	F-L trunk, main trunk of ECA, OA	MRA
5/78/M/right	LA, common trunk of FA, ECA, OA	MRA
6/48/M/right	LA, common trunk of FA, ECA ^a	MRA/angiography

^a OA arising from the VA.

carotid-vertebrobasilar anastomosis.¹⁰ To our knowledge, ours is the first report of the incidence of nonbifurcating cervical carotid artery detected by MRA.

We found an additional 11 cases of this anomaly in the English language literature (Table 2) and thus analyzed 17 total cases (12 men, 5 women; 7 cases, right side; 10, left). Two of the 11 cases were diagnosed during postmortem examination and 9 cases, by angiography. In 10 patients, the branching order from proximal to distal was the LA, FA or F-L trunk, distal trunk of the ECA, and OA. In 5 of the 17 patients, the OA did not arise from the carotid artery. In 2 of our patients, the FA arose from the distal trunk of the ECA, resembling high bifurcation of the carotid artery, and in 1 of these 2, the OA arose from the VA (Fig 2).

Morimoto et al³ first used the term “nonbifurcating cervical carotid artery” in 1990. Normally, the LA, FA, and OA arise from the proximal main trunk of the ECA. As shown above, these branches rarely arise separately from a single large vessel,

so there is no bifurcation of the carotid artery. Two hypotheses are proposed to explain the formation of this anomaly—agenesis of either the proximal main trunk of the ECA or the most proximal ICA.³ Embryologically, the ICA is formed from the third aortic arch and dorsal aorta during early gestation. Abnormal regression of the third aortic arch might result in the persistence of the hyoid artery, which derives from the second aortic arch, and might produce high bifurcation of the carotid artery with an anomalous branching pattern¹¹ or a nonbifurcating carotid artery.

Although the proximal main trunk of the ECA is apparently absent, we support the hypothesis that this anomaly results from agenesis of the most proximal ICA because the affected artery does not have physiologic dilation of the origin of ICA and the OA arises most distally. Thus, the distal ICA seems to originate from the proximal OA or APA. The APA rarely arises from the proximal ICA, and in the case of acquired occlusion of the ICA at its origin, the APA serves as an important collateral pathway from the VA.¹² Lasjaunias et al¹³ reported that the OA is formed from the proatlantal artery and arises from the primitive ICA, ECA, and VA at points determined by the sites of regression. Thus, the OA rarely arises from the ICA¹⁴ or VA, as in our case 6. We suggest that in the 4 previously reported patients in whom the OA was not visualized, the OA may have arisen from the VA. Figure 3 schematically illustrates our proposed hypothesis regarding this anomaly.

Right-sided predominance of both congenital total absence of the ICA and an aberrant course of the ICA caused by segmental agenesis of the petrous ICA is well known. In contrast,

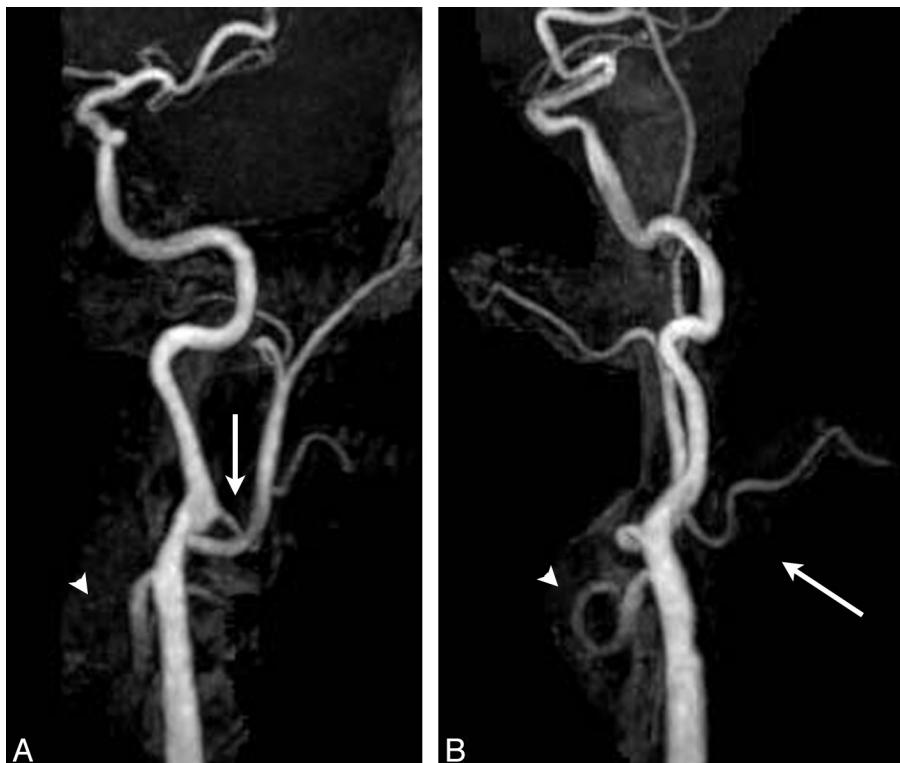


Fig 1. Case 2. Anteroposterior (A) and lateral (B) partial MIP images of the left carotid artery show a separately arising F-L trunk, a distal ECA, and the OA. There is no physiologic dilation of the ICA at its origin. Arrowheads and arrows in A indicate the most proximally arising F-L trunk and in B, the most distally arising OA.

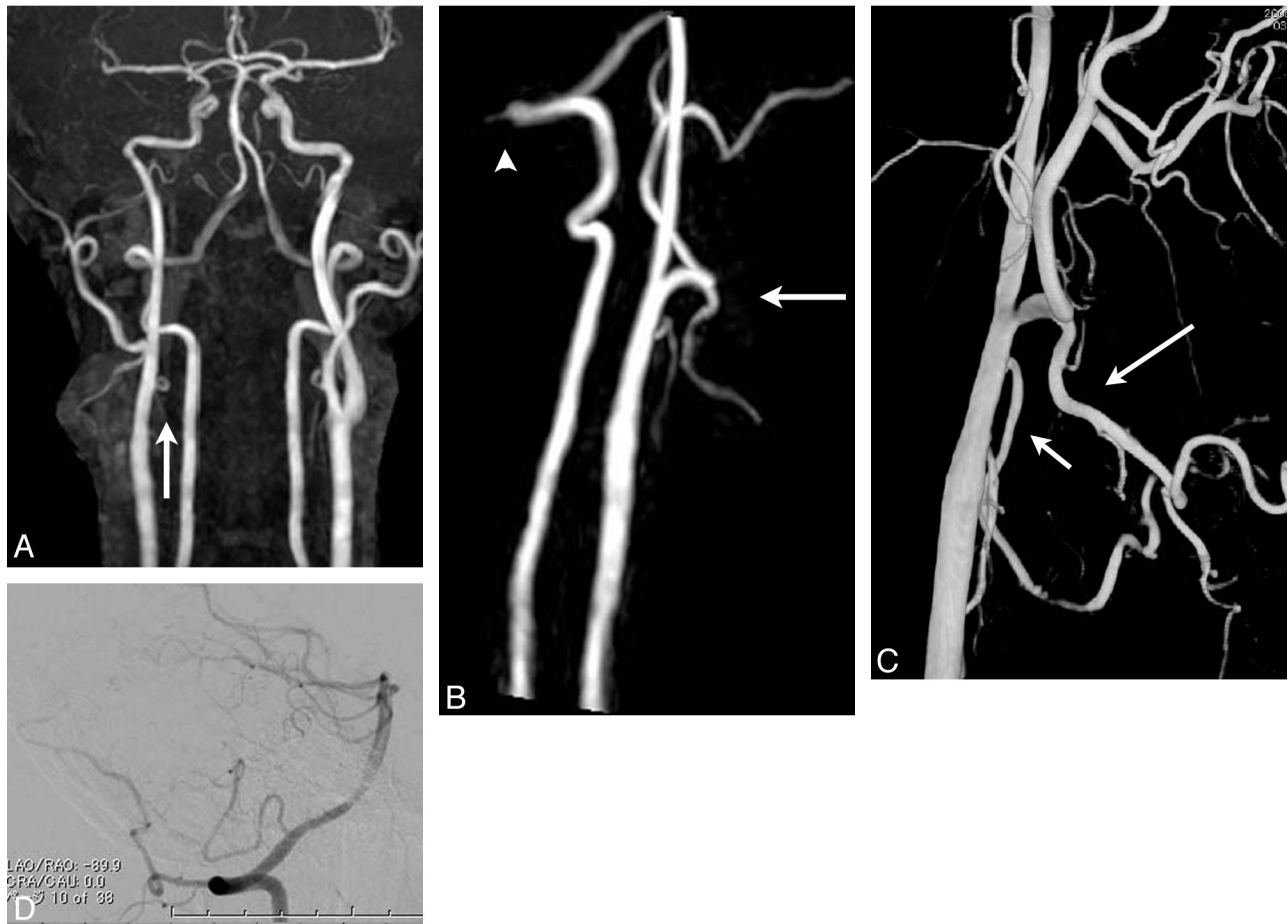


Fig 2. Case 6. Anteroposterior MIP image (A) and lateral partial MIP image of the right carotid and vertebrasilar arteries (B) show a straight ICA without physiologic dilation and a separately arising LA. The arrow in A indicates the LA. The FA originates from the distal ECA (arrow in B), resembling high bifurcation of the carotid artery. However, the OA arises from the right VA (arrowhead in B). C, 3D DSA of the right CCA clearly demonstrates the anomalously branching pattern. D, The short arrow indicates the LA, and the long arrow indicates the FA. DSA of a lateral projection of the right VA shows the OA arising from the level of the craniovertebral junction (arrowhead).

the nonbifurcating cervical carotid artery shows no significant lateral predominance. The reason for this difference is unknown.

In our institution, patients with or suspected of having ischemic cerebrovascular diseases routinely undergo MRA of intra- and extracranial regions that include the carotid bifurcation. We suggest that many cases of this anomaly have been

overlooked or misdiagnosed as high bifurcation of the carotid artery during angiography and that a nonbifurcating cervical carotid artery cannot be detected in routine cerebral MRA, which is usually performed to exclude the carotid bifurcation. Correct diagnosis is necessary to avoid complications, such as embolic cerebral infarctions, during interventional radiologic procedures^{8,9} or head and neck surgeries.

Our study is limited because it is a retrospective clinical

Table 2: Reported cases of a nonbifurcating cervical carotid artery in the English language literature

Reference No./ Age (yr)/Sex/ Left or Right	Branching Order (Proximal to Distal)	Diagnostic Modality
1/52/M/left	LA, FA, main trunk of ECA, OA	Autopsy
2/43/M/left	F-L trunk, main trunk of ECA ^a	Angiography/surgery
3/55/F/left	LA, FA, main trunk of ECA, OA	Angiography
4/76/M/left	F-L trunk, main trunk of ECA ^a	Angiography
5/67/M/left	LA, FA, main trunk of ECA, OA	Autopsy
6/66/M/right	LA, FA, main trunk of ECA ^a	Angiography/MRA/ surgery
7/75/F/left	F-L trunk, OA, main trunk of ECA	Angiography
7/67/F/left	F-L trunk, main trunk of ECA, OA	Angiography
7/65/M/left	F-L trunk, main trunk of ECA, OA	Angiography
8/64/F/right	LA, FA, main trunk of ECA ^a	Angiography
9/71/M/right	LA, FA, main trunk of ECA, OA	Angiography

^a OA arising from the carotid artery could not be identified.

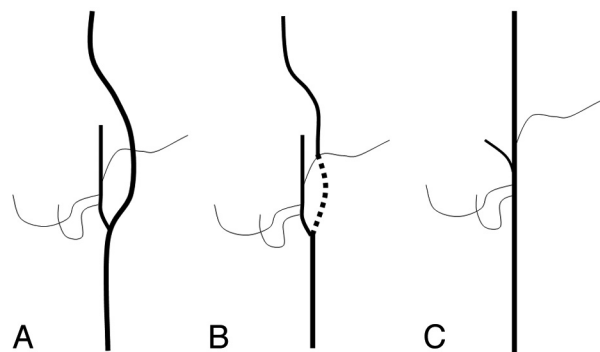


Fig 3. Schematic illustration of our hypothesis of a nonbifurcating cervical carotid artery in a lateral projection. A, Normal development. B, Agnesis of the most proximal ICA. C, Final configuration of this anomaly. The proximal OA or APA probably plays an important role in forming the nonbifurcating cervical carotid artery.

study, and only 1 neuroradiologist analyzed the MRAs. Also, because most of the examined patients had or were suspected of having ischemic cerebrovascular diseases, there may have been some selection bias in our study materials and results.

Conclusions

The nonbifurcating cervical carotid artery is rare but not as extremely rare as previously considered. It is important that diagnostic radiologists pay careful attention to a carotid bifurcation to find any arterial anomaly to avoid complications during interventional radiologic procedures or head and neck surgeries.

Acknowledgments

We thank Drs Shoichiro Ishihara and Shinya Kohyama for their contribution to Figs 2C and D and Rosalyn Uhrig, MA, for editorial assistance in the preparation of this manuscript.

References

1. Matsumoto M, Okuda H, Ishidoh E, et al. **An anomalous case of the common carotid artery giving off several branches and high division of the internal carotid artery.** *Okajimas Folia Anat Jpn* 1986;63:37–44
2. Franklin PD, Lee RG, Allard JC, et al. **Unilateral absence of the external carotid artery.** *Can Assoc Radiol J* 1988;39:293–94
3. Morimoto T, Nitta K, Kazekawa K, et al. **The anomaly of a non-bifurcating cervical carotid artery: case report.** *J Neurosurg* 1990;72:130–32
4. Lambiase RE, Haas RA, Carney WI Jr, et al. **Anomalous branching of the left common carotid artery with associated atherosclerotic changes: a case report.** *AJNR Am J Neuroradiol* 1991;12:187–89
5. Kaneko K, Akita M, Murata E, et al. **Unilateral anomalous left common carotid artery: a case report.** *Ann Anat* 1996;178:477–80
6. Rodriguez HE, Ziauddin MF, Podbielski FJ, et al. **Congenital absence of the external carotid artery: atherosclerosis without a bifurcation.** *J Vasc Surg* 2002;35:573–75
7. Ooigawa H, Nawashiro H, Fukui S, et al. **Non-bifurcating cervical carotid artery.** *J Clin Neurosci* 2006;13:944–47
8. Muroso S, Nakanishi Y, Minami T, et al. **Case report: intra-arterial chemotherapy for laryngeal cancer via a non-bifurcating carotid artery.** *Br J Radiol* 2009;82:e197–199
9. Kiyosue H, Mori H, Tanoue S, et al. **Non-bifurcating carotid artery coexisting with transverse sinus dural arteriovenous fistula.** *Neuroradiology* 2009;51:697–98
10. Luh GY, Dean BL, Tomsick TA, et al. **The persistent fetal carotid-vertebrobasilar anastomoses.** *AJR Am J Roentgenol* 1999;172:1427–32
11. Gluncic V, Petanjek Z, Marusic A, et al. **High bifurcation of common carotid artery, anomalous origin of ascending pharyngeal artery and anomalous branching pattern of external carotid artery.** *Surg Radiol Anat* 2001;23:123–25
12. Pelz DM, Fox AJ, Viñuela F, et al. **The ascending pharyngeal artery: a collateral pathway in complete occlusion of the internal carotid artery.** *AJNR Am J Neuroradiol* 1987;8:177–78
13. Lasjaunias P, Théron J, Moret J. **The occipital artery: anatomy—normal arteriographic aspects—embryological significance.** *Neuroradiology* 1978;15:31–37
14. Teal JS, Rumbaugh CL, Segall HD, et al. **Anomalous branches of the internal carotid artery.** *Radiology* 1973;106:567–73