

Are your MRI contrast agents cost-effective?

Learn more about generic Gadolinium-Based Contrast Agents.



AJNR

**Dynamic Changes in the Dural Sac
Cross-Sectional Area on Axial Loaded MR
Imaging: Is There a Difference between
Degenerative Spondylolisthesis and Spinal
Stenosis?**

This information is current as
of April 16, 2024.

H. Ozawa, H. Kanno, Y. Koizumi, N. Morozumi, T. Aizawa,
T. Kusakabe, Y. Ishii and E. Itoi

AJNR Am J Neuroradiol published online 9 February 2012
<http://www.ajnr.org/content/early/2012/02/09/ajnr.A2920>

ORIGINAL
RESEARCH

H. Ozawa
H. Kanno
Y. Koizumi
N. Morozumi
T. Aizawa
T. Kusakabe
Y. Ishii
E. Itoi

Dynamic Changes in the Dural Sac Cross-Sectional Area on Axial Loaded MR Imaging: Is There a Difference between Degenerative Spondylolisthesis and Spinal Stenosis?

BACKGROUND AND PURPOSE: Axial loaded MR imaging, which can simulate the spinal canal of patients in a standing position, demonstrates a significant reduction of the DCSA compared with conventional MR imaging and provides valuable imaging findings in the assessment of the lumbar spinal canal. The purpose of this study was to compare the DCSA on axial loaded MR imaging between patients with DS and SpS.

MATERIALS AND METHODS: Eighty-eight consecutive patients were divided into DS and SpS groups. DCSA on conventional MR imaging and axial loaded MR imaging and changes in the DCSA induced by axial loading were compared between DS and SpS groups. The prevalence of a significant change ($>15 \text{ mm}^2$) in the DCSA was compared between the 2 groups.

RESULTS: Axial loaded MR imaging demonstrated significantly smaller DCSA in the DS group ($35 \pm 22 \text{ mm}^2$) than in the SpS group ($50 \pm 31 \text{ mm}^2$), though conventional MR imaging did not show any differences between the 2 groups. The change in the DCSA induced by axial loading was significantly larger in the DS group ($17 \pm 12 \text{ mm}^2$) compared with the SpS group ($8 \pm 8 \text{ mm}^2$). The prevalence of a $>15\text{-mm}^2$ change in the DCSA was significantly higher in the DS group (62.5%) than in the SpS group (16.7%) (odds ratio, 8.33; 95% confidence interval, 3.09–22.50).

CONCLUSIONS: Axial loaded MR imaging demonstrated significantly larger changes in the DCSA in patients with DS compared those with SpS. A significant change in the DCSA was more frequently observed in patients with DS. Axial loaded MR imaging may therefore be a more useful tool to decrease the risk of underestimating the spinal canal narrowing in patients with DS than in those with SpS.

ABBREVIATIONS: DCSA = dural sac cross-sectional area; DS = degenerative spondylolisthesis; SpS = spinal stenosis

MR imaging is a noninvasive diagnostic tool and has been widely used for evaluating the narrowing of the lumbar spinal canal. To evaluate the severity of spinal canal narrowing, the DCSA is frequently measured by using axial MR imaging.^{1–6} The widely accepted radiologic cutoffs are $<75 \text{ mm}^2$ in the DCSA for absolute stenosis, $<100 \text{ mm}^2$ for relative stenosis, and $<130 \text{ mm}^2$ for early stenosis.^{2,4,7,8} However, conventional MR imaging is performed with patients in the supine position. In this position, the DCSA can be larger than that in the standing position.^{3,4,9} Hence, conventional MR imaging has a risk of underestimating the severity of the spinal canal narrowing.^{3,9–11} This disadvantage of conventional MR imaging creates difficulties in making an accurate diagnosis

and determining the precise indications for surgery, even for neurosurgeons.^{10,12,13}

Recently, a device for axial loading of the lumbar spine with the patients in the supine position during MR imaging has been developed.^{3,4} With the compression device, a physiologically normal weight-bearing condition in the upright position can be simulated in a supine position. The use of the device can cause a significant reduction in the DCSA and provide valuable information that conventional MR imaging cannot.^{3,4,6,10} DCSA on axial loaded MR imaging has been reported to correlate significantly with the severity of clinical symptoms in patients with spinal canal narrowing.¹¹ Furthermore, previous studies have demonstrated the $>15\text{-mm}^2$ decrease in the DCSA induced by axial loading to be a significant change, which increased the diagnostic specificity of spinal canal narrowing and influenced the indications for surgical treatment.^{4,10,12,13} Even if the reduction of the DCSA caused by axial loading is not significant, axial loaded MR imaging may still clarify important imaging findings, such as compression of the nerve root in the narrow lateral recess and in the foraminal stenosis.¹⁰ Therefore, evaluation of spinal canal narrowing in axial loaded MR imaging should be beneficial to achieve a more accurate diagnosis and to also select the optimal treatment.

Received July 27, 2011; accepted after revision September 23.

From the Department of Orthopedic Surgery (H.O., H.K., T.A., T.K., E.I.), Tohoku University School of Medicine, Sendai, Japan; and Department of Orthopedic Surgery (Y.K., N.M., Y.I.), Nishitaga National Hospital, Sendai, Japan.

This work was supported by a research grant from Japan Orthopaedics and Traumatology Foundation Inc (No. 205).

Paper previously presented at: 38th Annual Meeting of the Japanese Society for Spine Surgery and Related Research, April 23–24, 2009; Kobe, Japan.

Please address correspondence to Haruo Kanno, MD, PhD, Department of Orthopaedic Surgery, Tohoku University School of Medicine, 1-1 Seiryomachi, Aoba-ku, Sendai, 980-8574, Japan; e-mail: kanno-h@isis.ocn.ne.jp

<http://dx.doi.org/10.3174/ajnr.A2920>

DS and SpS of the lumbar spine were originally described as separate pathoanatomic entities,^{14,15} though both cause narrowing of the spinal canal that induces compression of the nerve roots and cauda equina. Not only SpS but also DS commonly causes neurogenic claudication and leg pain and/or numbness that is exacerbated during walking or being in the upright position.^{14,16} According to their similarities, DS is likely to be recognized as a subtype of SpS and classified as a subgroup among other degenerative causes of stenosis.¹⁷ Several studies have investigated the differences in the clinical symptoms and outcomes of treatment between patients with SpS and DS.¹⁸⁻²⁰ However, many other investigators have traditionally combined patients with DS and SpS in clinical studies, despite the fact that patients with DS and SpS may undergo different treatments.²¹⁻²⁶ There is still a lack of consensus in regard to whether patients with DS and SpS actually differ clinically.¹⁸

To date, there have been many studies to investigate the DCSA on MR imaging or CT during axial loading in patients with SpS.^{3,6,11-13,27,28} On the other hand, only 1 study analyzed the DCSA during axial loading in patients with DS.²⁹ This previous study suggested that the DCSA could be significantly decreased by axial loading in patients with DS. However, there has, so far, been no study to compare the changes in the DCSA on axial loaded MR imaging between patients with DS and SpS.

The purpose of this study was to compare the dynamic changes in the DCSA on axial loaded MR imaging between patients with DS and SpS. We compared the DCSA obtained by conventional MR imaging and axial loaded MR imaging and changes in the DCSA induced by axial loading between patients with DS and SpS. In addition, the prevalence of a significant change in the DCSA ($>15 \text{ mm}^2$) was also compared between the 2 patient groups.

Materials and Methods

Patients

This study included 88 consecutive patients (34 women and 54 men) who were referred to our institution for surgical treatment between October 2007 and September 2009. All patients had neurogenic intermittent claudication and leg pain or numbness with associated neurologic signs¹⁴ and had radiographically confirmed lumbar spinal canal narrowing on cross-sectional imaging. In all of the patients, the neurologic diagnosis, such as lumbar radiculopathy and/or cauda equina syndrome,^{30,31} was confirmed by >1 spine surgeon on the basis of clinical symptoms, neurologic examinations, and imaging studies including plain radiography, CT, and MR imaging of the lumbar spine. The exclusion criteria were prior lumbar spine surgery, spondylolysis, spinal anomalies, severe osteoporosis, polyneuropathy, and arterial insufficiency. The institutional review board of our institution approved this study. Informed consent was obtained from all patients before their participation in the study. At the time of the initial evaluation, the baseline characteristics such as the patient's age, sex, height, body weight, body mass index, and duration of symptoms were registered for each patient.

Conventional MR Imaging and Axial Loaded MR Imaging

The MR imaging was performed by using a 1.5T system (Magnetom Vision; Siemens, Erlangen, Germany) with a spine array coil. Axial

T2-weighted turbo spin-echo sequences were performed. The TR/TE was 4000/120 ms. The section thickness was 4 mm, and the FOV was 200 mm. The images were obtained at the middle of each intervertebral disk from L2/3 to L5/S1. The sections were placed as parallel as possible to the intervertebral disks.

After the conventional MR imaging, axial loading was applied by using an external commercially available nonmagnetic compression device, L-Spine (DynaWell Diagnostics, Las Vegas, Nevada).^{3,4} The compression force was approximately 50% of the patient's body weight, and the loading was commenced 5 minutes before and was continued during the MR imaging examination. A new scout image was obtained in the axially loaded position, and the sections were again placed in the plane of each disk. Both the axial loaded and nonloaded MR images were obtained with straight knees to simulate a normal upright position.^{9,27} To prevent flexion of the spine during axial loading, a cushion was placed behind the lumbar spine.^{9,32}

Measurement of DCSA

All measurements were performed by using the OsiriX Imaging Software program, version 2.7 (www.osirix-viewer.com). The DCSA was measured from L2/3 to L5/S1 on the axial image (Fig 1). The measurement was performed 3 times, and the mean value was calculated and used for the analysis in this study. Each of the 3 measurements was performed at intervals of >1 week. The measurements were performed by an experienced spine surgeon authorized by the Japanese Orthopaedic Association. In the measurements, the experimenter was blinded to which images were loaded or unloaded. Using unloaded and loaded images of a total of 40 intervertebral levels taken from 10 randomly selected patients in the present study, we confirmed the intraobserver and interobserver reliability for the measurement of the DCSA to be excellent (Pearson $r = 0.96$ and 0.97 , respectively; $P < .001$). Intraobserver reliability for the measurement of the DCSA was also confirmed to be excellent in our previous study.¹¹ On the basis of previous studies,^{1,9,11} the DCSA at the most constricted intervertebral level was used to represent the degree of the spinal canal narrowing for each subject. The most constricted intervertebral level that presented the smallest DCSA on conventional MR imaging was selected in each subject for data analyses in this study.

Radiologic Assessment for Patients with DS

On the neutral standing lateral radiograph of the lumbar spine, the degree of spondylolisthesis was measured at the most constricted intervertebral level as described above. The amount of spondylolisthesis was measured by using the method described by White and Panjabi.³³ All of the radiographs were obtained with a 150-cm tube-to-film distance. The central radiograph beam was focused on the most constricted intervertebral level. For the comparative analysis in this study, the patients with ≥ 3 -mm spondylolisthesis³⁴⁻³⁷ were assigned to the DS group, while the other patients were assigned to the SpS group.

Data Analysis

The baseline characteristics, such as the patient's age, sex, height, body weight, body mass index, the duration of symptoms, presence of low back pain, and the most constricted intervertebral level, were statistically compared between the DS and the SpS groups.

The Pearson correlation coefficient of the DCSA between the conventional MR imaging and the axial loaded MR imaging was calculated for each group. The differences in the DCSA between the conventional MR imaging and axial loaded MR imaging were also assessed by means of a Bland-Altman plot.^{38,39} The DCSA in the con-

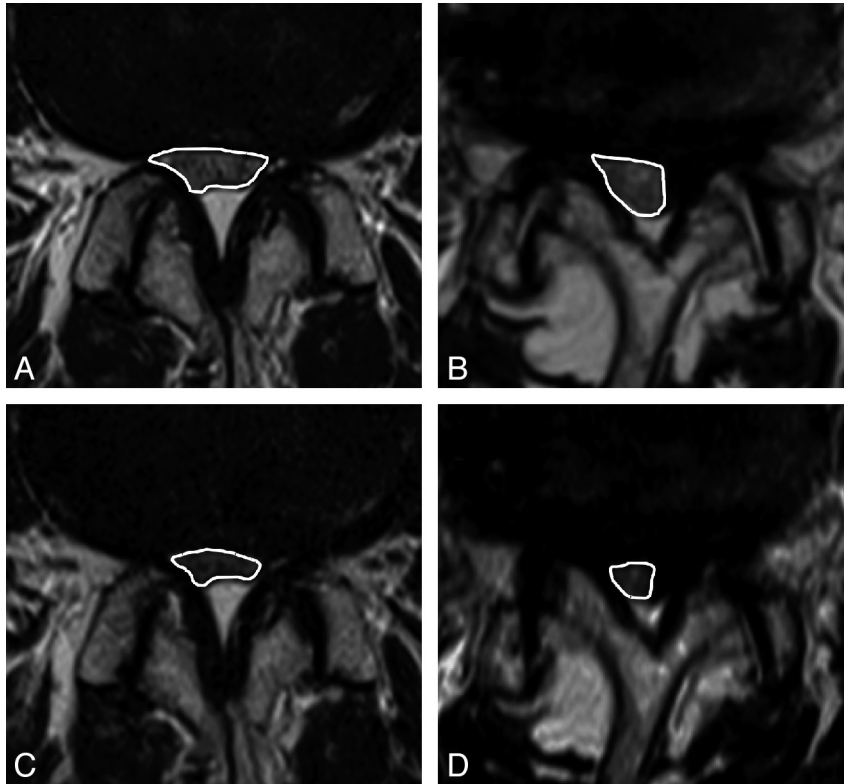


Fig 1. The measurement of DCSA on conventional MR imaging and axial loaded MR imaging in representative patients with SpS (A and C) and DS (B and D). The white lines indicate the outlines of the DCSA. In the first patient with SpS, the DCSA changed from 67 (A) to 41 mm² (C) due to the axial loading. In the second patient with DS, the DCSA changed from 52 (B) to 25 mm² (D).

ventional MR imaging and the axial loaded MR imaging was compared between the 2 groups. In addition, the changes in the DCSA between the conventional and the axial loaded MR imaging were calculated and then compared between the DS and the SpS groups.

On the basis of previous studies, a >15-mm² reduction in the DCSA induced by axial loading was defined as a significant change.^{3,4,10,13} The prevalence of a >15-mm² change in the DCSA was investigated and statistically compared between the 2 groups. Additionally, the odds ratio for a >15- and a ≤15-mm² change in the DCSA, the DCSA determined by conventional MR imaging and axial loaded MR imaging was compared in each group.

Statistical Methods

All statistical analyses were performed by using the GraphPad Prism, Version 4.0c, software program (GraphPad Software, San Diego, California). The differences in baseline characteristics between groups were tested for statistical significance by using the unpaired *t* test or the χ^2 test. The differences in the DCSA were analyzed by using the unpaired *t* test. Pearson correlation coefficients for the DCSA between the conventional MR imaging and axial loaded MR imaging were determined. The prevalence of a >15 mm² change was compared by using the χ^2 test. *P* < .05 was considered to be a statistically significant difference.

Results

Baseline Characteristics

Eighty-eight consecutive patients were divided into 48 patients (33 women and 15 men) in the SpS group and 40 pa-

Table 1: Comparison of baseline characteristics between SpS and DS groups

Baseline Characteristics	SpS Group (n = 48)	DS Group (n = 40)	P Value ^a
Age (yr) ^b	68 ± 9	68 ± 11	.730
Sex (male)	69%	53%	.090
Height (cm) ^b	161 ± 8	159 ± 10	.336
Body weight (kg) ^b	64 ± 10	65 ± 13	.702
Body mass index (kg/m ²) ^b	25 ± 3	26 ± 4	.251
Duration of symptoms (mo) ^b	28 ± 34	39 ± 31	.121
Presence of low back pain	48%	50%	.508
The most constricted level			.182
L2/3	2%	0%	
L3/4	21%	23%	
L4/5	63%	75%	
L5/S1	15%	3%	

^a There are no statistically significant differences in any parameters between 2 groups.

^b Values are mean ± SD.

tients (21 women and 19 men) in the DS group for the comparative analysis in this study. The baseline characteristics and the most constricted intervertebral level in each group are summarized in Table 1. There were no significant differences in any of these parameters between the DS and the SpS groups. The values of the DCSA at the most constricted level measured 3 times for all patients are summarized in Table 2.

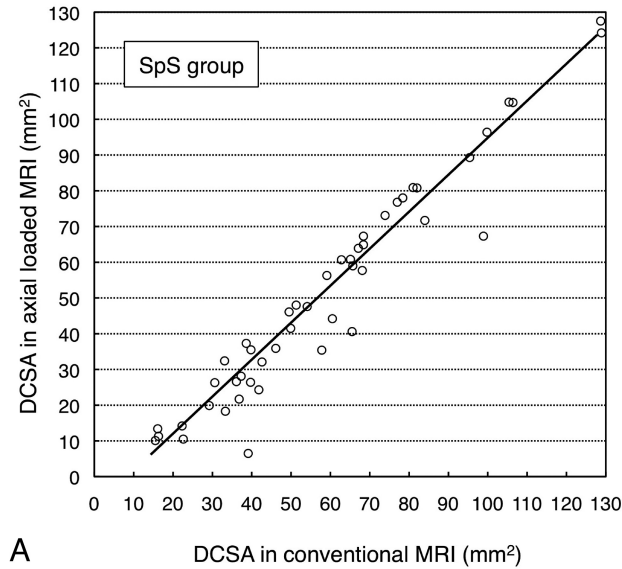
Comparison of DCSA in Conventional and Axial Loaded MR Imaging and Changes in the DCSA

The values of the DCSA in the conventional MR imaging and the axial loaded MR imaging for each patient are shown in Fig

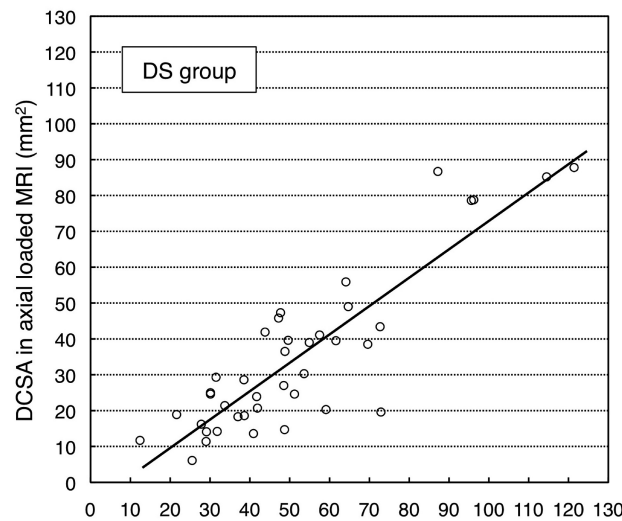
Table 2: Measurements of the DCSA in all patients^a

	DCSA on Conventional MR Imaging	DCSA on Axial Loaded MR Imaging
1st Measurement	56.9 ± 27.8	43.2 ± 29.3
2nd Measurement	54.7 ± 27.3	42.6 ± 28.0
3rd Measurement	54.2 ± 26.8	43.2 ± 28.3
Average ^b	55.3 ± 26.8	43.2 ± 28.2

^a Values are mean ± SD (mm²).
^b Average of the 3 measurements.



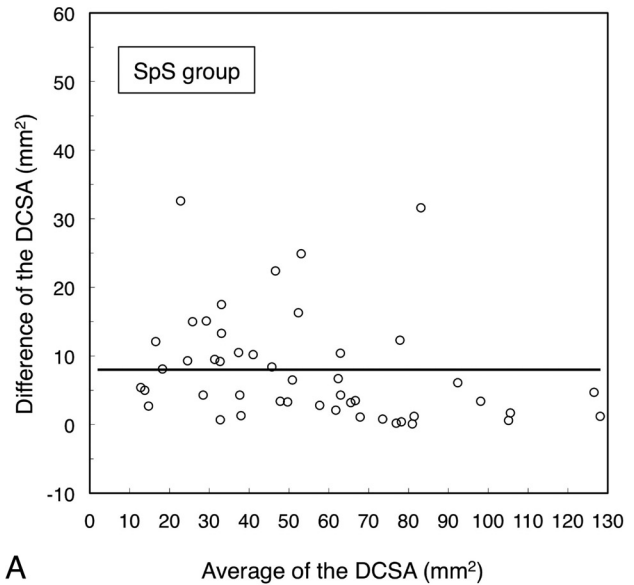
A DCSA in conventional MRI (mm²)



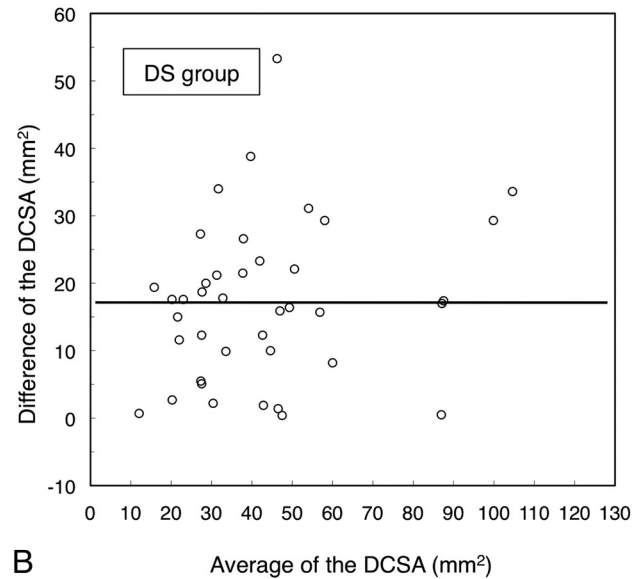
B DCSA in conventional MRI (mm²)

Fig 2. The values of DCSA for conventional MR imaging and axial loaded MR imaging at the most constricted intervertebral levels for each patient in the SpS (A) and the DS (B) groups. The Pearson correlation coefficients between conventional MR imaging and axial loaded MR imaging were 0.97 in the SpS group and 0.88 in the DS group ($P < .001$).

2. The Pearson correlation coefficient for the DCSA between the conventional MR imaging and the axial loaded MR imaging in the DS group ($r = 0.88$) was smaller than that in the SpS group ($r = 0.97$). The Bland-Altman plot showed the differences in the DCSA between the conventional MR imaging and the axial loaded MR imaging in the DS group to be larger than those in the SpS group (Fig 3).



A Average of the DCSA (mm²)



B Average of the DCSA (mm²)

Fig 3. Bland-Altman plots for each patient in the SpS (A) and the DS (B) groups. The y-axis shows the difference in the DCSA between conventional MR imaging and axial loaded MR imaging (DCSA in conventional MR imaging - DCSA in axial loaded MR imaging). The x-axis shows the average of the DCSA of the conventional and axial loaded MR imaging [(DCSA in conventional MR imaging + DCSA in axial loaded MR imaging) / 2]. The solid lines indicate the mean differences in the DCSA.

There was no statistical difference in the DCSA on the conventional MR imaging between the SpS group (58 ± 29 mm²) and the DS group (51 ± 25 mm²) ($P = .270$). On the other hand, the axial loaded MR imaging demonstrated a significantly smaller DCSA in the DS group (35 ± 22 mm²) than in the SpS group (50 ± 31 mm²) ($P = .009$) (Fig 4). In addition, the change in the DCSA induced by axial loading was significantly larger in the DS group (17 ± 12 mm²) than in the SpS group (8 ± 8 mm²) ($P < .001$) (Fig 5).

Prevalence of a >15-mm² Change in the DCSA

A >15-mm² change in the DCSA was found in 8 patients (16.7%) in the SpS group and 25 patients (62.5%) in the DS group (Table 3). The prevalence of a >15-mm² change in the

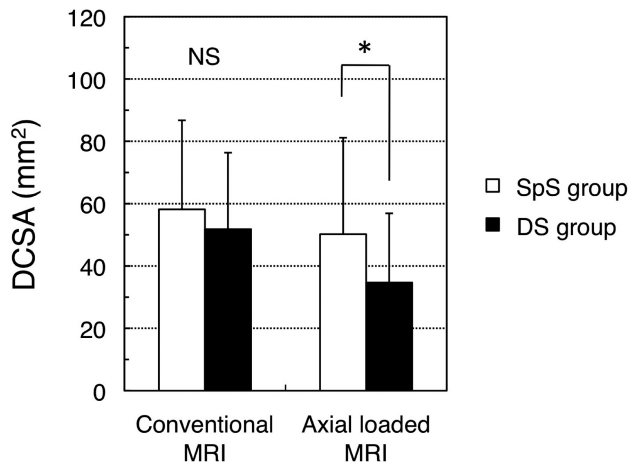


Fig 4. Comparison of the DCSA obtained by conventional MR imaging and axial loaded MR imaging between the SpS and the DS groups. The asterisk indicates $P < .05$; error bars, SD.

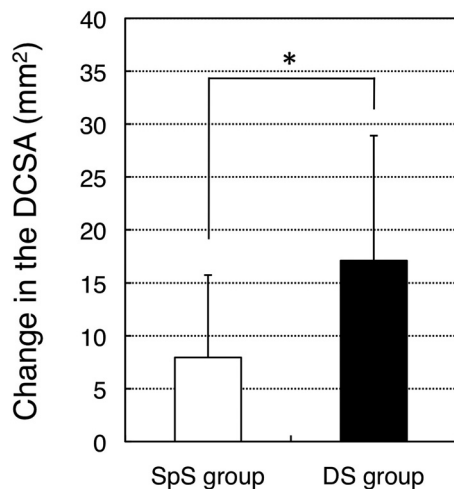


Fig 5. Comparison of the change in the DCSA induced by axial loading between the SpS and the DS groups. The asterisk indicates $P < .05$; error bars, SD.

	SpS Group (n = 48)	DS Group (n = 40)
≤15 mm ² change in the DCSA	40 (83.3%)	15 (37.5%)
>15 mm ² change in the DCSA	8 (16.7%)	25 (62.5%)

^a There is a significant difference (χ^2 test, $P < .001$; odds ratio, 8.33).

DCSA was significantly higher in the DS group than the SpS group ($P < .001$). The DS group was 8.33 times more likely to demonstrate a >15-mm² change in the DCSA compared with the SpS group (odds ratio, 8.33; 95% confidence interval, 3.09–22.50).

Comparison between Patients with >15-mm² and ≤15-mm² Changes in the DCSA

When the DCSA was compared in the SpS group, the axial loaded MR imaging demonstrated a significantly smaller DCSA in patients with a >15-mm² change in the DCSA (32 ± 19 mm²) than in those with a ≤15-mm² change (56 ± 31 mm²) ($P = .043$). On the other hand, the conventional MR imaging did not show any statistically significant differences

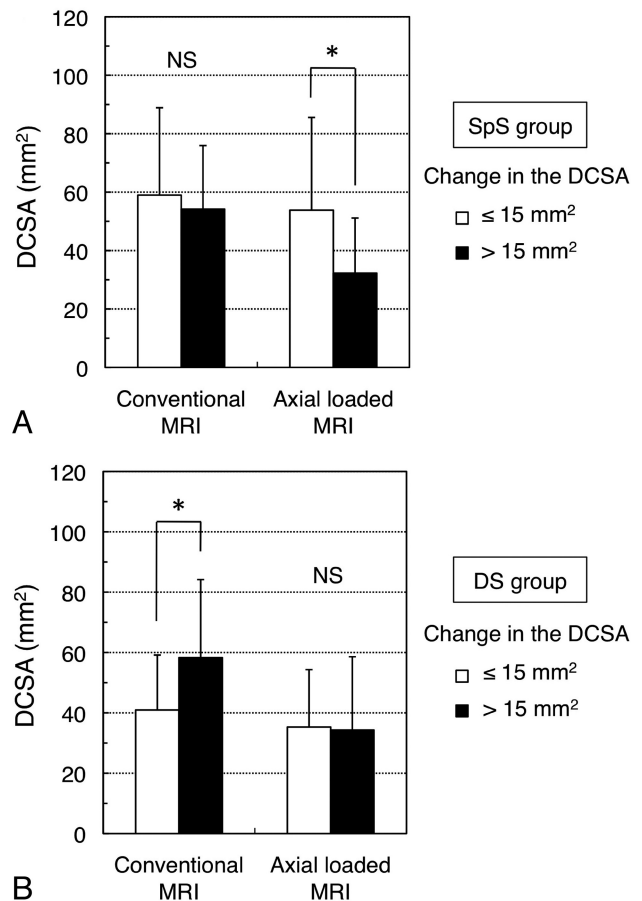


Fig 6. Comparison of the DCSA obtained by conventional MR imaging and axial loaded MR imaging between patients with >15- and ≤15-mm² changes in the DCSA in the SpS (A) and DS (B) groups. The asterisk indicates $P < .05$; error bars, SD.

between patients with a >15- and a ≤15-mm² change in the SpS group ($P = .672$) (Fig 6A). In the DS group, patients with a >15-mm² change had a significantly larger DCSA on conventional MR imaging (58 ± 26 mm²) than those with a ≤15-mm² change (41 ± 18 mm²) ($P = .028$), while the axial loaded MR imaging showed no significant difference between the patients with a >15- and a ≤15-mm² change in the DCSA ($P = .897$) (Fig 6B).

Discussion

Previous studies have shown axial loaded MR imaging to demonstrate a significant reduction of the DCSA and provide valuable imaging findings for the clinical assessment of patients with spinal canal narrowing.^{3,4,6,10} DS and SpS commonly cause spinal canal narrowing that induces compression of the nerve roots and cauda equina.¹⁶⁻¹⁸ However, to date, there has been no study to compare the DCSA in axial loaded MR imaging between patients with DS and SpS. The present study demonstrated that the DCSA in the axial loaded MR imaging was significantly smaller in patients with DS than in those with SpS, though conventional MR imaging did not show any difference between the 2 groups. In addition, the change in the DCSA induced by axial loading was significantly larger in the patients with DS compared with those with SpS. These results indicated that the DCSA in patients with DS is more likely to be decreased by axial loading than in those with SpS. There-

fore, the narrowing of the spinal canal in the standing position in patients with DS is likely to be more severe than that of patients with SpS, even if the severity looks similar between the 2 patient groups on conventional MR imaging. The clinical assessment on conventional MR imaging, therefore, has a higher risk of underestimating the severity of spinal canal narrowing in patients with DS than in those with SpS.

Several studies have suggested clinical risk factors for the marked change in the DCSA induced by axial loading. A previous report showed that the L4/5 intervertebral level has a higher prevalence of significant changes in the DCSA compared with the other levels.⁴ It has been reported that the progression of disk degeneration that is found in conventional MR imaging increases the risk of a significant reduction in the DCSA induced by axial loading.⁴⁰ The intervertebral levels with severe spinal canal narrowing on upright myelography demonstrated more evident reduction in dural sac size on axial loaded MR imaging than those without severe narrowing.⁹ The present study showed that the prevalence of a $>15\text{ mm}^2$ change in the DCSA was significantly higher in the DS group than in the SpS group. In fact, the DS group was 8.33 times more likely to demonstrate a $>15\text{-mm}^2$ change in the DCSA compared with the SpS group. Therefore, the presence of DS was strongly predictive of a marked change in the DCSA by axial loading during the clinical assessment of spinal canal narrowing.

Many previous studies have indicated a poor correlation between the DCSA measured on conventional MR imaging and the severity of clinical symptoms.^{5,41,42} These negative data might have resulted from the use of conventional MR imaging, which was unable to determine the actual condition of the spinal canal causing symptoms in patients in the upright position. On the other hand, the DCSA on axial loaded MR imaging demonstrated a significant correlation with the severity of symptoms in patients with spinal canal narrowing.¹¹ It was also demonstrated that patients with a $>15\text{-mm}^2$ change in the DCSA on axial loaded MR imaging had more severe symptoms than those with $\leq 15\text{-mm}^2$ change.¹¹ In the present study, the DCSA determined by conventional MR imaging did not differ between patients with a $>15\text{ mm}^2$ and those with a $\leq 15\text{-mm}^2$ change, in the SpS group. Moreover, in the DS group, the conventional MR imaging showed a significantly larger DCSA in patients with a $>15\text{-mm}^2$ change compared with those with a $\leq 15\text{-mm}^2$ change. These results suggest that conventional MR imaging probably failed to detect the crucial imaging findings that indicate a worsening of the clinical symptoms. Axial loaded MR imaging may, therefore, be a valuable tool for detecting important imaging findings that correlate with the clinical symptoms, which conventional MR imaging is unable to identify.

Axial loaded MR imaging has been reported to demonstrate morphologic changes caused by compression of the lumbar spine, including bulging disks, a thickening of the ligamentum flavum, a change in the shape of the dorsal fat pad, and a deformation of the dural sac and the nerve root.^{3,4,6,10} Several reports have suggested that the degree of spondylolisthesis in the sagittal image on axial loaded MR imaging is larger than that on conventional MR imaging.^{43,44} The dynamic change in the degree of spondylolisthesis was considered to induce the morphologic change of the dural sac

size.^{44,45} In the present study, the change in the DCSA induced by axial loading was significantly larger in patients with DS than in those with SpS. These findings suggest that the dynamic changes of spondylolisthesis during axial loading exacerbated the decrease in the DCSA in patients with DS.

Not only axial loading to the lumbar spine but the extension of the body trunk also induces a reduction of the dural sac size and thus may induce symptoms in patients with spinal canal narrowing.^{46,47} A previous study suggested that spinal extension more effectively reduced the dural sac size than axial loading.²⁸ On the other hand, axial loading more effectively induced clinical symptoms than the postural change.⁴⁸ In addition, the change in the DCSA caused by axial loading significantly correlated with the severity of clinical symptoms.¹¹ In this study, a reduction of the DCSA induced by axial loading was observed in both the SpS and the DS groups. These data suggest that axial loading can at least partially reduce the DCSA and worsen the clinical symptoms in patients with spinal canal narrowing such as those with SpS and DS.

MR imaging is a noninvasive diagnostic tool and is widely used for the clinical evaluation of spinal canal narrowing.^{1-5,11,41,42} However, conventional MR imaging cannot detect the DCSA in patients in the upright position and has a potential risk of underestimating the severity of spinal canal narrowing.⁹ Such a disadvantage of conventional MR imaging makes it difficult to make an accurate diagnosis and makes it impossible to provide precise indications for surgery in patients with spinal canal narrowing.^{10,12,13} In the present study, the reduction of the DCSA by axial loading was significantly larger in patients with DS than for those with SpS. Additionally, the patients with DS demonstrated a significantly higher prevalence of a $>15\text{-mm}^2$ change in the DCSA compared with those with SpS. Therefore, to make a more accurate diagnosis and provide an appropriate treatment, axial loaded MR imaging should be used for patients with DS. The axial loaded MR imaging can provide more beneficial and accurate information for the clinical assessment of patients with DS.

Conclusions

The present study showed the change in the DCSA induced by axial loading to be significantly larger in patients with DS than in those with SpS. Furthermore, a significant reduction in the DCSA on the axial loaded MR imaging was more frequently observed in patients with DS compared with those with SpS. Thus, axial loaded MR imaging may be a more useful tool to provide valuable imaging findings for the assessment of spinal canal narrowing in patients with DS than for those with SpS.

Acknowledgments

The authors thank the staff of Department of Radiology at Tohoku University Hospital and Nishitaga National Hospital for technical assistance and useful discussion in the study.

References

1. Ogikubo O, Forsberg L, Hansson T. The relationship between the cross-sectional area of the cauda equina and the preoperative symptoms in central lumbar spinal stenosis. *Spine (Phila Pa 1976)*. 2007;32:1423–28
2. Hamanishi C, Matukura N, Fujita M, et al. Cross-sectional area of the stenotic lumbar dural tube measured from the transverse views of magnetic resonance imaging. *J Spinal Disord Tech* 1994;7:388–93
3. Danielson BI, Willén J, Gaultz A, et al. Axial loading of the spine during CT and

- MR in patients with suspected lumbar spinal stenosis. *Acta Radiol* 1998;39:604–11
4. Willén J, Danielson B, Gaultz A, et al. Dynamic effects on the lumbar spinal canal: axially loaded CT-myelography and MRI in patients with sciatica and/or neurogenic claudication. *Spine (Phila Pa 1976)* 1997;22:2968–76
 5. Sirvanci M, Bhatia M, Ganiyusufoglu KA, et al. Degenerative lumbar spinal stenosis: correlation with Oswestry Disability Index and MR imaging. *Eur Spine J* 2008;17:679–85. Epub 2008 Mar 7
 6. Hansson T, Suzuki N, Hebelka H, et al. The narrowing of the lumbar spinal canal during loaded MRI: the effects of the disc and ligamentum flavum. *Eur Spine J* 2009;18:679–86
 7. Schönström N, Bolender NF, Spengler DM, et al. Pressure changes within the cauda equina following constriction of the dural sac: an in vitro experimental study. *Spine* 1984;9:604–07
 8. Bolender NF, Schonstrom NS, Spengler DM. Role of computed tomography and myelography in the diagnosis of central spinal stenosis. *J Bone Joint Surg Am* 1985;67:240–46
 9. Kanno H, Endo T, Ozawa H, et al. Axial loading during magnetic resonance imaging in patients with lumbar spinal stenosis: does it reproduce the positional change of the dural sac detected by upright myelography? *Spine (Phila Pa 1976)* 2011 Jan 20. [Epub ahead of print]
 10. Willén J, Danielson B. The diagnostic effect from axial loading of the lumbar spine during computed tomography and magnetic resonance imaging in patients with degenerative disorders. *Spine (Phila Pa 1976)* 2001;26:2607–14
 11. Kanno H, Ozawa H, Koizumi Y, et al. Dynamic change of dural sac cross-sectional area in axial loaded MRI correlates with the severity of clinical symptoms in patients with lumbar spinal canal stenosis. *Spine (Phila Pa 1976)* 2011 Feb 4. [Epub ahead of print]
 12. Hiwatashi A, Danielson B, Moritani T, et al. Axial loading during MR imaging can influence treatment decision for symptomatic spinal stenosis. *AJNR Am J Neuroradiol* 2004;25:170–74
 13. Willén J, Wessberg PJ, Danielson B. Surgical results in hidden lumbar spinal stenosis detected by axial loaded computed tomography and magnetic resonance imaging: an outcome study. *Spine (Phila Pa 1976)* 2008;33:E109–15
 14. Verbiest H. A radicular syndrome from developmental narrowing of the lumbar vertebral canal. *J Bone Joint Surg Br* 1954;36-B:230–37
 15. Junghanns H. Spondylolisthesen ohne Spalt in Zwischengelenkstück. *Archiv für Orthopädische Unfallchirurgie* 1930;29:118–27
 16. Sengupta DK, Herkowitz HN. Degenerative spondylolisthesis: review of current trends and controversies. *Spine (Phila Pa 1976)* 2005;30:S71–81
 17. Arnoldi CC, Brodsky AE, Cauchoix J, et al. Lumbar spinal stenosis and nerve root entrapment syndromes: definition and classification. *Clin Orthop Relat Res* 1976;4–5
 18. Pearson A, Blood E, Lurie J, et al. Degenerative spondylolisthesis versus spinal stenosis: does a slip matter? Comparison of baseline characteristics and outcomes (SPORT). *Spine (Phila Pa 1976)* 2010;35:298–305
 19. Cummins J, Lurie JD, Tosteson TD, et al. Descriptive epidemiology and prior healthcare utilization of patients in the Spine Patient Outcomes Research Trial's (SPORT) three observational cohorts: disc herniation, spinal stenosis, and degenerative spondylolisthesis. *Spine (Phila Pa 1976)* 2006;31:806–14
 20. Tosteson AN, Lurie JD, Tosteson TD, et al. Surgical treatment of spinal stenosis with and without degenerative spondylolisthesis: cost-effectiveness after 2 years. *Ann Intern Med* 2008;149:845–53
 21. Turner JA, Ersek M, Herron L, et al. Surgery for lumbar spinal stenosis: attempted meta-analysis of the literature. *Spine (Phila Pa 1976)* 1992;17:1–8
 22. Atlas SJ, Keller RB, Robson D, et al. Surgical and nonsurgical management of lumbar spinal stenosis: four-year outcomes from the Maine lumbar spine study. *Spine (Phila Pa 1976)* 2000;25:556–62
 23. Atlas SJ, Keller RB, Wu YA, et al. Long-term outcomes of surgical and nonsurgical management of lumbar spinal stenosis: 8 to 10 year results from the Maine lumbar spine study. *Spine (Phila Pa 1976)* 2005;30:936–43
 24. Malmivaara A, Slati P, Heliövaara M, et al. Surgical or nonoperative treatment for lumbar spinal stenosis? A randomized controlled trial. *Spine (Phila Pa 1976)* 2007;32:1–8
 25. Katz JN, Lipson SJ, Brick GW, et al. Clinical correlates of patient satisfaction after laminectomy for degenerative lumbar spinal stenosis. *Spine (Phila Pa 1976)* 1995;20:1155–60
 26. Katz JN, Stucki G, Lipson SJ, et al. Predictors of surgical outcome in degenerative lumbar spinal stenosis. *Spine (Phila Pa 1976)* 1999;24:2229–33
 27. Lohman CM, Tallroth K, Kettunen JA, et al. Comparison of radiologic signs and clinical symptoms of spinal stenosis. *Spine (Phila Pa 1976)* 2006;31:1834–40
 28. Madsen R, Jensen TS, Pope M, et al. The effect of body position and axial load on spinal canal morphology: an MRI study of central spinal stenosis. *Spine (Phila Pa 1976)* 2008;33:61–67
 29. Huang KY, Lin RM, Lee YL, et al. Factors affecting disability and physical function in degenerative lumbar spondylolisthesis of L4–5: evaluation with axially loaded MRI. *Eur Spine J* 2009;18:1851–57
 30. Suzuki H, Endo K, Kobayashi H, et al. Total sagittal spinal alignment in patients with lumbar canal stenosis accompanied by intermittent claudication. *Spine (Phila Pa 1976)* 2010;35:e344–46
 31. Sato K, Kikuchi S. Clinical analysis of two-level compression of the cauda equina and the nerve roots in lumbar spinal canal stenosis. *Spine (Phila Pa 1976)* 1997;22:1898–903, discussion 904
 32. Danielson B, Willén J. Axially loaded magnetic resonance image of the lumbar spine in asymptomatic individuals. *Spine (Phila Pa 1976)* 2001;26:2601–06
 33. White A, III, Panjabi M eds. *Clinical Biomechanics of the Spine*. 2nd ed. Philadelphia: Lippincott; 1990
 34. Vogt MT, Rubin DA, San Valentin R, et al. Degenerative lumbar listhesis and bone mineral density in elderly women: the study of osteoporotic fractures. *Spine (Phila Pa 1976)* 1999;24:2536–41
 35. Vogt MT, Rubin D, Valentin RS, et al. Lumbar olisthesis and lower back symptoms in elderly white women: the study of osteoporotic fractures. *Spine (Phila Pa 1976)* 1998;23:2640–47
 36. Brantigan JW, Neidre A. Achievement of normal sagittal plane alignment using a wedged carbon fiber reinforced polymer fusion cage in treatment of spondylolisthesis. *Spine J* 2003;3:186–96
 37. Ghogawala Z, Benzel EC, Amin-Hanjani S, et al. Prospective outcomes evaluation after decompression with or without instrumented fusion for lumbar stenosis and degenerative grade I spondylolisthesis. *J Neurosurg Spine* 2004;1:267–72
 38. Dewitte K, Fierens C, Stockl D, et al. Application of the Bland-Altman plot for interpretation of method-comparison studies: a critical investigation of its practice. *Clin Chem* 2002;48:799–801, author reply 801–02
 39. Bland JM, Altman DG. Statistical methods for assessing agreement between two methods of clinical measurement. *Lancet* 1986;1:307–10
 40. Ahn TJ, Lee SH, Choi G, et al. Effect of intervertebral disk degeneration on spinal stenosis during magnetic resonance imaging with axial loading. *Neurol Med Chir (Tokyo)* 2009;49:242–47, discussion 47
 41. Moon ES, Kim HS, Park JO, et al. Comparison of the predictive value of myelography, computed tomography and MRI on the treadmill test in lumbar spinal stenosis. *Yonsei Med J* 2005;46:806–11
 42. Zeifang F, Schiltewolf M, Abel R, et al. Gait analysis does not correlate with clinical and MR imaging parameters in patients with symptomatic lumbar spinal stenosis. *BMC Musculoskelet Disord* 2008;9:89
 43. Manenti G, Liccardo G, Sergiacomi G, et al. Axial loading MRI of the lumbar spine. *In Vivo* 2003;17:413–20
 44. Jayakumar P, Nnadi C, Saifuddin A, et al. Dynamic degenerative lumbar spondylolisthesis: diagnosis with axial loaded magnetic resonance imaging. *Spine (Phila Pa 1976)* 2006;31:E298–301
 45. Ben-Galim P, Reitman CA. The distended facet sign: an indicator of position-dependent spinal stenosis and degenerative spondylolisthesis. *Spine J* 2007;7:245–48
 46. Weishaupt D, Schmid MR, Zanetti M, et al. Positional MR imaging of the lumbar spine: does it demonstrate nerve root compromise not visible at conventional MR imaging? *Radiology* 2000;215:247–53
 47. Zamani AA, Moriarty T, Hsu L, et al. Functional MRI of the lumbar spine in erect position in a superconducting open-configuration MR system: preliminary results. *J Magn Reson Imaging* 1998;8:1329–33
 48. Oğuz H, Levendoğlu F, Oğün TC, et al. Loading is more effective than posture in lumbar spinal stenosis: a study with a treadmill equipment. *Eur Spine J* 2007;16:913–18