

Are your **MRI contrast agents** cost-effective?

Learn more about generic **Gadolinium-Based Contrast Agents**.



AJNR

Diagnostic Accuracy of PET for Recurrent Glioma Diagnosis: A Meta-Analysis

T. Nihashi, I.J. Dahabreh and T. Terasawa

AJNR Am J Neuroradiol published online 1 November 2012
<http://www.ajnr.org/content/early/2012/11/01/ajnr.A3324>

This information is current as of April 17, 2024.

Diagnostic Accuracy of PET for Recurrent Glioma Diagnosis: A Meta-Analysis

T. Nihashi, I.J. Dahabreh, and T. Terasawa



ABSTRACT

BACKGROUND AND PURPOSE: Studies have assessed PET by using various tracers to diagnose disease recurrence in patients with previously treated glioma; however, the accuracy of these methods, particularly compared with alternative imaging modalities, remains unclear. We conducted a meta-analysis to quantitatively synthesize the diagnostic accuracy of PET and compare it with alternative imaging modalities.

MATERIALS AND METHODS: We searched PubMed and Scopus (until June 2011), bibliographies, and review articles. Two reviewers extracted study characteristics, validity items, and quantitative data on diagnostic accuracy. We performed meta-analysis when ≥ 5 studies were available.

RESULTS: Twenty-six studies were eligible. Studies were heterogeneous in treatment strategies and diagnostic criteria of PET; recurrence was typically suspected by CT or MR imaging. The diagnostic accuracies of ^{18}F -FDG ($n = 16$) and ^{11}C -MET PET ($n = 7$) were heterogeneous across studies. ^{18}F -FDG PET had a summary sensitivity of 0.77 (95% CI, 0.66–0.85) and specificity of 0.78 (95% CI, 0.54–0.91) for any glioma histology; ^{11}C -methionine PET had a summary sensitivity of 0.70 (95% CI, 0.50–0.84) and specificity of 0.93 (95% CI, 0.44–1.0) for high-grade glioma. These estimates were stable in subgroup and sensitivity analyses. Data were limited on ^{18}F -FET ($n = 4$), ^{18}F -FLT ($n = 2$), and ^{18}F -boronophenylalanine ($n = 1$). Few studies performed direct comparisons between different PET tracers or between PET and other imaging modalities.

CONCLUSIONS: ^{18}F -FDG and ^{11}C -MET PET appear to have moderately good accuracy as add-on tests for diagnosing recurrent glioma suspected by CT or MR imaging. Studies comparing alternative tracers or PET versus other imaging modalities are scarce. Prospective studies performing head-to-head comparisons between alternative imaging modalities are needed.

ABBREVIATIONS: CI = confidence interval; ^{11}C -MET = 11-carbon methionine; ^{18}F -FET = 18-fluorine fluoroethyltyrosine; ^{18}F -FLT = 18-fluorine fluorothymidine; ROC = receiver operating characteristic; ^{201}Tl = thallium 201

Gliomas are the most commonly diagnosed primary brain tumors in the United States.¹ Despite recent advances in temozolomide-based multimodality therapy, high-grade gliomas remain incurable diseases with a median survival of < 3 years for

glioblastoma and < 5 years for anaplastic gliomas.^{2–4} In contrast, low-grade gliomas, which include astrocytoma, oligodendroglioma, and oligoastrocytoma, are indolent malignant tumors, typically surgically treated,^{3,5} with a median survival of > 5 years.

Treatment-induced necrosis is a common treatment-related morbidity in the management of gliomas, which typically occurs 3–12 months posttreatment.⁶ On conventional MR imaging with gadolinium enhancement, treatment-induced necrosis typically presents as an increase in the size of contrast-enhancing lesions, which mimics tumor progression or recurrence after remission.

Received May 1, 2012; accepted after revision July 29.

From the Department of Radiology (T.N.), Nagoya University Graduate School of Medicine, Nagoya, Japan; Center for Clinical Evidence Synthesis (I.J.D., T.T.), Institute for Clinical Research and Health Policy Studies, Tufts Medical Center, Boston, Massachusetts; Center for Evidence-based Medicine (I.J.D.), Brown University, Providence, Rhode Island; Department of Internal Medicine (T.T.), Fujita Health University Nanakuri Sanatorium, Fujita Health University School of Medicine, Tsu, Mie, Japan; and Clinical Research Center (T.T.), National Hospital Organization Nagoya Medical Center, Nagoya, Japan.

Takashi Nihashi and Teruhiko Terasawa contributed equally to the study and manuscript.

Please address correspondence to Teruhiko Terasawa, MD, PhD, Fujita Health University Nanakuri Sanatorium, 424-1 Odoricho, Tsu, Mie, 514-1295 Japan; e-mail: terasawa@fujita-hu.ac.jp

Indicates open access to non-subscribers at www.ajnr.org

Indicates article with supplemental on-line tables.

Indicates article with supplemental on-line figures.

Evidence-Based Medicine Series 1

<http://dx.doi.org/10.3174/ajnr.A3324>

Differentiating the 2 conditions is challenging,^{6,7} and reliable noninvasive neuroimaging modalities are needed to better guide the management of patients with suspected recurrence.

PET is a promising molecular neuroimaging technique that provides metabolic tumor information complementing the CT and MR imaging examinations.⁸ Several studies have evaluated PET by using various tracers (eg, ¹⁸F-FDG, ¹¹C-MET, ¹⁸F-FET, or ¹⁸F-FLT) as a test for aiding the differential diagnosis of suspected glioma recurrence. ¹⁸F-FDG is the most widely used tracer; its uptake correlates with the amount of glucose consumption and the local metabolic rate within the glioma lesion.⁹ Uptake of ¹⁸F-FDG in high-grade glioma is typically similar to or less than that in normal gray matter; uptake in low-grade glioma is similar to that in white matter.^{8,10} Due to the low contrast between tumor and healthy brain tissue with ¹⁸F-FDG, however, more specific tracers have been developed. Amino acid tracers such as ¹¹C-MET and ¹⁸F-FET offer higher contrast than ¹⁸F-FDG based on the increased intracellular amino acid use and extracellular matrix production of tumor cells.^{8,10} Further, uptake of ¹⁸F-FLT correlates well with thymidine kinase-1 activity, a cytosolic enzyme with high concentration in proliferating cells but low in resting cells.^{8,10} Because cell proliferation rates are higher in malignant glioma cells compared with scar tissue, ¹⁸F-FLT can also differentiate tumor recurrence from treatment-induced necrosis.

Studies evaluating novel PET tracers have small sample sizes and use heterogeneous designs, making interpretation of published data difficult. Furthermore, the comparative effectiveness of alternative imaging modalities such as advanced MR imaging techniques (eg, perfusion MR imaging or MR spectroscopy) is currently uncertain. We performed a systematic review to provide a comprehensive summary and quantitative synthesis of information on the diagnostic accuracy of PET by using various tracers to diagnose disease recurrence in patients with previously treated glioma. We also aimed to compare PET with other imaging modalities for differentiating recurrent or progressive glioma from treatment-induced necrosis, when used as add-on tests to conventional MR imaging.

MATERIALS AND METHODS

Search Strategy, Study Eligibility, and Data Abstraction

We searched the Medline and Scopus databases (from inception through June 30, 2011) with no language restriction. The complete search strategies are presented in the On-line Appendix. To complement our data base searches, we examined the reference lists of eligible studies and relevant review articles.

Two reviewers (T.N., T.T.) independently screened abstracts and further examined full-text articles of potentially eligible citations. Studies that assessed PET by using any tracer for differentiating disease recurrence from treatment-induced necrosis in patients with suspected glioma recurrence after any form of treatment were eligible. We included both prospective and retrospective studies, and we considered pathologic confirmation with or without clinical follow-up as the reference standard. We included only English language publications that evaluated at least 10 patients; smaller studies do not provide meaningful estimates of accuracy. We excluded studies that did not provide adequate information to allow the calculation of sensitivity and specificity.

We also excluded editorials, comments, letters to the editor, and review articles.

One of 2 reviewers (T.N., T.T.) extracted descriptive data from each eligible study, which were verified by a second reviewer. We extracted the following information from eligible studies: first author, year of publication, journal, patient demographic and clinical characteristics, therapeutic interventions, technical specifications of PET, and interpretation of PET results. Two reviewers (I.J.D., T.T.) independently extracted quantitative data regarding imaging results and final diagnoses. Discrepancies were resolved by consensus. When studies performed a direct comparison between different imaging modalities (eg, ¹⁸F-FDG PET versus thallium 201 [²⁰¹Tl] SPECT), we extracted data on accuracy for all imaging tests investigated.

We took particular care to identify publications with at least partially overlapping populations by comparing authors, centers, recruitment periods, patient demographic characteristics, and glioma histologies. We included all relevant publications in qualitative synthesis but only included studies with nonoverlapping patient populations in meta-analyses, to avoid double counting of evidence. Specifically, when multiple publications with potentially overlapping patient populations were available, we only included the publication with the largest sample size in the meta-analysis.

Validity Assessment

To assess the validity and reporting quality of studies, we evaluated 14 items that were considered relevant to the review topic on the basis of the Quality Assessment of Diagnostic Accuracy Studies instrument.^{11,12} The complete operational definition of each item is available from the authors on request. For comparative studies of diagnostic tests, we extracted the proportion of study participants receiving each comparator test. We operationally defined an “optimal direct comparison” as the performance of both tests at the same time point in at least 90% of eligible patients. This cutoff was chosen to limit the potential for patient selection and disease progression bias. Two reviewers (T.N., T.T.) independently assessed study quality, and discrepancies were resolved by consensus.

Data Synthesis

For each study, we constructed a 2 × 2 contingency table consisting of true-positive, false-positive, false-negative, and true-negative results. Patients were categorized according to whether they were test positive or negative (on the basis of imaging) and whether they had relapsed glioma by the reference standard. We extracted results of visual and quantitative assessments separately. When a study reported test results at multiple time points during clinical follow-up, we only recorded the results of the test performed closest to the completion of treatment (ie, the first instance of PET performance after recurrence was suspected). Also, in studies in which histologic results were negative and clinical follow-up results were also reported, we planned to only consider the clinical status as the reference standard because it is more important from the patient’s perspective. However, no cases of discrepant results between pathologic and clinical reference standards were reported in the studies we reviewed.

We recorded the counts of true-positive, false-positive, false-negative, and true-negative results based on the cutoff values specified by each study (when reported). When studies did not specify cutoff values but did report numeric data of quantitative assessment for each enrolled patient, we used the following methods to construct a 2×2 of test results: For ^{18}F -FDG, we determined the optimal cutoff threshold for defining positive and negative scans by ROC analysis; for ^{11}C -MET results, we used a cutoff value of 1.5 of the tumor-to-normal reference ratio or similar indices to define positive (>1.5) and negative (≤ 1.5) results as the main analysis as recommended by experts⁹ and the optimal cutoff threshold determined by ROC analysis as a sensitivity analysis.

We calculated sensitivity and specificity for each study with their corresponding 95% CIs. We obtained summary estimates of sensitivity and specificity with their corresponding 95% CIs by using bivariate random effects meta-analysis with the exact binomial likelihood, when ≥ 5 studies were available (because of model complexity at least 5 studies are required for estimation).^{13,14} Summary positive and negative likelihood ratios were calculated from the summary sensitivity and specificity estimates. We assessed between-study heterogeneity visually, by plotting sensitivity and specificity separately in forest plots, and also in the ROC space. We constructed summary ROC curves and confidence regions for summary sensitivity and specificity when appropriate.^{13,15} For each ROC curve, we estimated the Q^* statistic, the point on the curve where sensitivity and specificity are equal, as a global measure of diagnostic accuracy. When a study reported results based on both visual and quantitative assessments of PET imaging, visual assessment was preferred over qualitative assessment for ^{18}F -FDG PET and quantitative assessment was preferred over visual assessment for ^{11}C -MET PET because the respective assessment methods were in the majority of cases. Alternative approaches (ie, by using quantitative assessment for ^{18}F -FDG PET and visual assessment for ^{11}C -MET PET) were explored in sensitivity analyses.

To explore heterogeneity, we performed a subgroup analysis limited to high-grade gliomas only. To further explore whether study-level characteristics could explain between-study heterogeneity, we performed univariate (single predictor) meta-regression analyses by using the bivariate model (2 outcomes, sensitivity and specificity, modeled jointly). We assessed the following, a priori selected, covariates: year of publication, study design (prospective versus retrospective), study size, relapse rate, proportion of use of temozolomide, and type of reference standard (pathology only versus pathology and clinical follow-up).

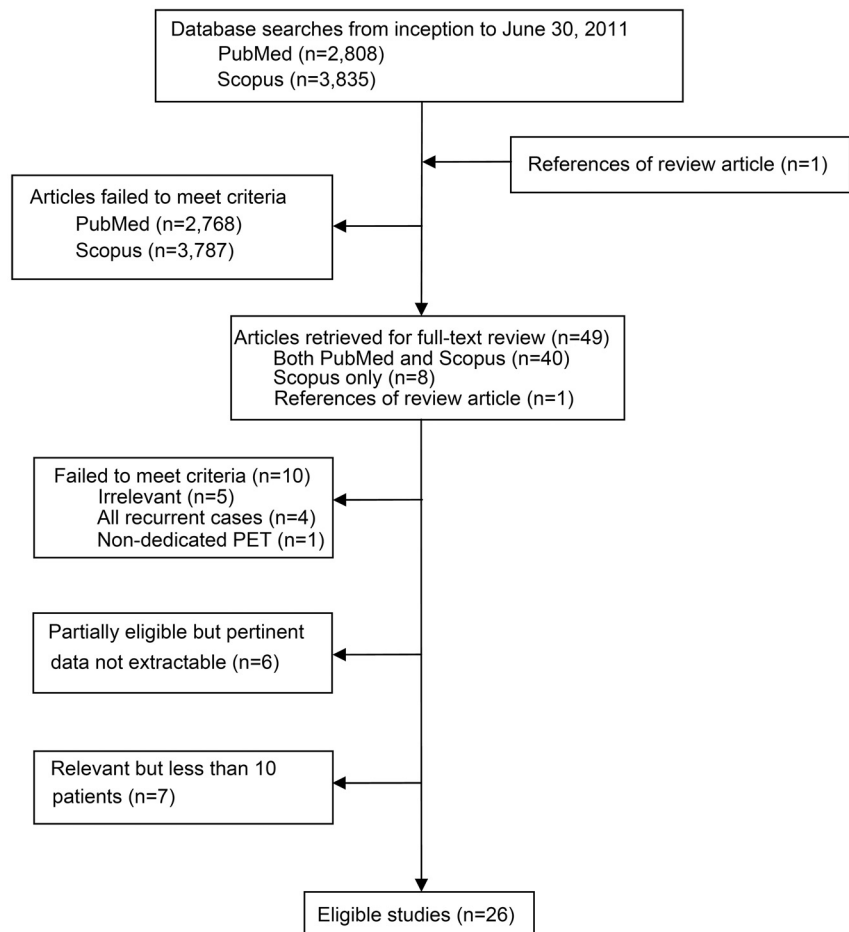


FIG 1. Study flow diagram.

Analyses were conducted by using STATA 11.1/SE (StataCorp, College Station, Texas) and Meta-Analyst, Version 3.0 β (Tufts Medical Center, Boston, Massachusetts). All tests were 2-sided, and statistical significance was defined as a P value $< .05$.

RESULTS

Study Selection and Characteristics

Our PubMed and Scopus searches identified 2808 and 3835 citations, respectively, of which 48 were considered potentially eligible and were retrieved in full text for further assessment. We identified an additional potentially eligible article by perusing the reference lists of relevant review articles. After full text review, 23 publications were excluded and 26 studies were considered eligible for this review (Fig 1).¹⁶⁻⁴¹ A complete list of excluded studies along with reasons for exclusion is provided in the Appendix.

The 26 eligible studies included a total of 780 previously treated patients with suspicion of recurrent glioma, typically experiencing worsening clinical symptoms or demonstrating new or progressing lesions on CT or conventional MR imaging, in whom PET was evaluated to differentiate between recurrence and treatment-related necrosis (On-line Table 1). A pair of studies each for ^{18}F -FDG,^{16,35} ^{11}C -MET,^{29,36} and ^{18}F -FET PET^{24,26} were conducted in the same institutions and potentially included overlapping patient groups. The 2 most commonly evaluated PET tracers

were ^{18}F -FDG (16 studies) and ^{11}C -MET (7 studies). Four studies compared different PET tracers: Two compared ^{18}F -FDG with ^{11}C -MET,^{25,39} 1 compared ^{18}F -FDG with ^{18}F -FLT,⁴⁰ and 1 compared ^{18}F -FLT with ^{18}F -FET.³¹ Six studies reported comparisons between ^{18}F -FDG PET and other imaging modalities: 2 with ^{201}Tl -SPECT,^{17,27} 2 with perfusion MR imaging,^{33,39} 1 with iodine 123- α -methyl-tyrosine SPECT,²¹ 1 with MR spectroscopy,³³ 1 with MR imaging evaluating dynamic susceptibility contrast-enhanced cerebral blood volume,³² and 1 with MR imaging evaluating arterial spin-labeling.³² Four studies compared ^{11}C -MET PET with other imaging modalities: 2 with perfusion MR imaging,^{38,39} 1 with ^{201}Tl -SPECT,²⁰ and 1 with MR spectroscopy.³⁰

Twenty of 26 studies (77%) included both high- and low-grade gliomas,^{16-33,40,41} and 6 exclusively included high-grade gliomas.³⁴⁻³⁹ Although few studies reported specific clinical contexts of PET assessment (ie, whether included patients were investigated for potential recurrence after primary therapy or after salvage therapy), patients typically underwent PET >6 months after completion of therapy. Twenty-one of 26 studies (77%) had a retrospective design. Typically, the reference standard comprised biopsy or clinical follow-up; 4 of 26 studies (15%) used biopsy as the sole reference standard to assess recurrence. Mean or median follow-up ranged between 7 and 34 months.

Studies adopted various treatment strategies (On-line Table 2). Most used multimodality therapies typically comprising surgery and some form of radiation therapy with or without chemotherapy. Only 4 recent studies explicitly reported that patients with high-grade glioma were treated with temozolomide.^{33,38-40}

Regarding imaging techniques and technologies, included studies generally followed guidelines by the European Association of Nuclear Medicine (On-line Table 3).^{42,43} All studies used stand-alone dedicated PET scanners except for 1 study, in which some patients underwent combined PET/CT instead of stand-alone PET.

Studies used variable diagnostic criteria both for visual and quantitative assessments (On-line Table 4). The 2 indexes most commonly used in quantitative assessments were maximum standardized uptake values within the region of interest of the suspected lesions and the ratio of uptake in the suspected lesion to that in a reference area. No study explicitly reported how the region of interest was specified. Studies typically reported pairs of sensitivity and specificity on the basis of the optimal cutoff values estimated by ROC analysis. Only 1 study reported inter-rater agreement when multiple interpreters were involved in the interpretation of PET results.²⁵

Assessment of Validity

No study adequately reported all 14 items relevant to study validity that we assessed (On-line Table 5). Reporting was particularly poor regarding the following items: blinding of interpreters of the index and reference standard tests, whether the decision to perform biopsy was based on PET results, and whether additional treatments were applied during clinical follow-up. Most studies had a retrospective design and did not clearly report whether consecutive patients were included. Six of 26 studies (23%) adopted a

reference standard comprising biopsy only without clinical follow-up.

Sensitivity, Specificity, Likelihood Ratios, and Summary ROC Curves

Studies reported heterogeneous sensitivities and specificities for ^{18}F -FDG PET (On-line Fig 1). When considering both low- and high-grade gliomas,^{16-19,21-23,27,32,33,40,41} sensitivity ranged between 0.23 and 0.95 and specificity ranged between 0.17 and 1.0. For high-grade gliomas,^{16-19,27,34,35,39,41} sensitivity ranged between 0.18 and 1.00 and specificity ranged 0.25 and 1.0. Studies including both low- and high-grade gliomas had a summary sensitivity of 0.77 (95% CI, 0.66–0.85) and a summary specificity of 0.78 (95% CI, 0.54–0.91), corresponding to a positive likelihood ratio of 3.4 (95% CI, 1.6–7.5) and a negative likelihood ratio of 0.30 (95% CI, 0.21–0.43) (Fig 2). In analyses limited to high-grade glioma, summary sensitivity was 0.79 (95% CI, 0.67–0.88) and summary specificity was 0.70 (95% CI, 0.50–0.84), corresponding to a positive likelihood ratio of 2.6 (95% CI, 1.5–4.4) and a negative likelihood ratio of 0.30 (95% CI, 0.20–0.46). The summary ROC curves and confidence regions for summary sensitivity and specificity were similar for studies of both all glioma histologies and the subgroup of high-grade gliomas with comparable Q^* statistics of 0.77 and 0.75, respectively. These estimates were similar in subgroup analyses in which only studies adopting visual assessment were considered and in sensitivity analyses (On-line Fig 2).

Similarly, studies reported widely ranging sensitivity and specificity estimates for ^{11}C -MET PET. When we considered both low- and high-grade gliomas,^{20,25,29,30} sensitivity ranged between 0.55 and 0.80 and specificity ranged between 0.70 and 1.0 (On-line Fig 1). For high-grade gliomas,^{20,25,30,36,39} sensitivity ranged between 0.44 and 0.93 and specificity ranged between 0.50 and 1.0. For high-grade gliomas, the summary sensitivity was 0.70 (95% CI, 0.50–0.84) and summary specificity was 0.93 (95% CI, 0.44–1.00), corresponding to a positive likelihood ratio of 10.31 (95% CI, 0.76–139.39) and a negative likelihood ratio of 0.32 (95% CI, 0.18–0.57), and the Q^* statistic was 0.79 (Fig 2). These estimates were similar in subgroup analyses in which only studies using quantitative assessment were considered and in sensitivity analyses (On-line Fig 2).

Studies evaluating ^{18}F -FET^{24,26,28,31} and ^{18}F -FLT^{31,40} reported consistently high sensitivity, particularly for high-grade glioma (On-line Fig 1). We did not perform meta-analysis for ^{18}F -FET,^{24,26,28,31} ^{18}F -FLT,^{31,40} or ^{18}F -boronophenylalanine³⁷ because there were few studies investigating each of these tracers.

Meta-Regression Analyses

We performed meta-regression analyses only for studies evaluating ^{18}F -FDG PET (both for all glioma histologies and for high-grade glioma alone) because this was the only tracer evaluated in >10 studies. In meta-regression analyses, year of publication, study design, sample size, relapse rate, proportion of use of temozolomide, or the type of reference standard did not affect test performance statistically significantly (all P values > .05).

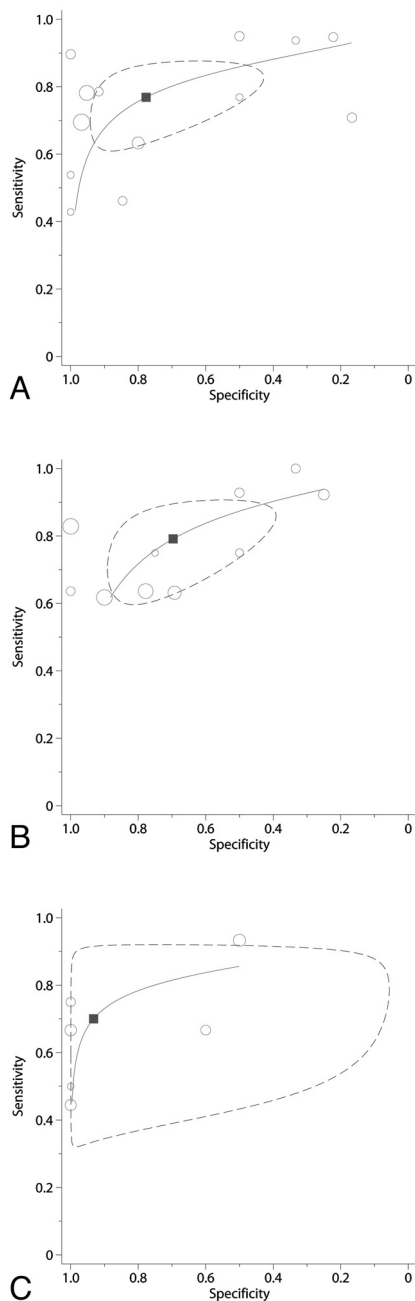


FIG 2. Receiver operator characteristic curves of PET for differentiating recurrent glioma from treatment-induced necrosis (^{18}F -fluorodeoxyglucose PET for both high- and low-grade glioma histology [A], and high-grade glioma only [B], and ^{11}C -methionine PET for high-grade glioma only [C]). The size of each circle is proportional to the sample size of the corresponding study (all study participants). The dashed line represents the 95% confidence region for the summary sensitivity and specificity (depicted by a square).

Comparisons among Different PET Tracers

Six studies^{20,25,31,36,39,40} reported on 9 comparisons among pairs of different PET tracers. In all except 1 study, both tests were performed in at least 90% of study participants. Generally, test comparisons showed trade-offs between sensitivity and specificity (consistent with diagnostic threshold effects), suggesting that different tracers may have broadly similar diagnostic accuracy (On-line Fig 3).

Comparisons between PET and Other Imaging Modalities

Six studies^{17,21,27,32,33,39} reported on 10 comparisons between ^{18}F -FDG PET and other imaging tests. Five comparisons were between ^{18}F -FDG PET and advanced MR imaging techniques; only 1 of these comparisons involved >90% of study participants. No study explicitly stated how patients were selected for additional diagnostic testing, suggesting that selection bias may have affected results. ROC plots did not show any clear pattern (On-line Fig 3).

Four studies^{20,30,38,39} reported on 8 comparisons between ^{11}C -MET PET and other imaging tests. Among 4 comparisons between ^{11}C -MET PET with advanced MR imaging techniques, only 1 involved >90% of study participants. Studies again did not report why patients were excluded from additional testing. No consistent pattern regarding comparative diagnostic accuracy was evident from these studies (On-line Fig 3).

DISCUSSION

This systematic review suggests that PET by using ^{18}F -FDG or ^{11}C -MET has moderately good overall accuracy for diagnosing disease recurrence, independent of histologic grade, among patients with glioma for whom recurrence was suspected by conventional anatomic imaging tests such as CT or MR imaging. These results are mainly based on visual assessment for ^{18}F -FDG, and quantitative assessment for ^{11}C -MET; however, various diagnostic criteria and thresholds were adopted across studies. Evidence on other tracers is sparse. Furthermore, evidence is limited regarding comparisons among different PET tracers, as well as for the comparison of PET with non-PET imaging modalities.

^{18}F -FET and ^{18}F -FLT are relatively new PET tracers and have been in clinical use only for the past decade. Their diagnostic accuracy has been assessed only in a limited number of referral centers. Although promising pilot data have been reported, further validation is needed. The studies we reviewed typically focused on individual imaging modalities and did not allow a complete comparative evaluation of the available imaging technologies. Furthermore, most studies retrospectively and jointly assessed low- and high-grade gliomas treated with heterogeneous treatment strategies and adopted heterogeneous methodologies for confirming disease relapse with diverse follow-up protocols. Our findings expand the findings of previous narrative reviews^{9,44} by providing a quantitative overview of the diagnostic accuracy of PET for differentiating between disease recurrence and treatment-induced changes. Additionally, our work provides a comprehensive review of studies directly comparing different PET tracers and those comparing PET with alternative imaging tests in this clinical setting.

Several limitations of the available evidence are worth noting. Most studies had limited internal and external validity; therefore, reported accuracy estimates may not be replicable or relevant to other clinical settings. Also, few studies used treatment strategies that would be consistent with the current standards of care (ie, surgery alone for low-grade glioma and temozolomide-based multimodality therapy for high-grade glioma). Thus, our results may be less applicable to current clinical practice. In addition, our analyses on comparative evidence are based on a limited number of studies. Furthermore, studies comparing PET with MR imag-

ing modalities are based mostly on selected patients; therefore, our results should be interpreted with caution. Finally, no studies of ^{18}F -choline or 3,4-dihydroxy-6- ^{18}F -fluoro-L-phenylalanine PET⁹ fulfilled our inclusion criteria, and we did not consider non-comparative studies of non-PET imaging modalities.

Pseudoprogression is a clinically benign phenomenon characterized by the appearance and subsequent stabilization (or spontaneous regression) of enhancing lesions on routine MR imaging, within 2 months after completion of concurrent treatment with temozolomide and radiation.⁶ It is unclear whether our results are directly applicable to the use of PET for differentiating between pseudoprogression and true tumor progression; few patients in our review had been treated with temozolomide-based therapies, and most patients had been evaluated with PET at later time than when pseudoprogression is typically suspected.

Future studies of PET for the evaluation of glioma relapse should use prospective designs, focus on clinically relevant patient populations treated with standardized protocols, and avoid potential biases in evaluating test accuracy. An important research priority is the assessment of test performance for distinguishing pseudoprogression from true tumor progression in the context of temozolomide-based treatment for high-grade glioma. Given the current emphasis on the comparative effectiveness of health care interventions, research efforts should focus on the relative benefits and risks of competing imaging modalities in real-world clinical settings.⁴⁵ Data on head-to-head comparisons among individual imaging modalities (ie, comparisons among different PET tracers [eg, ^{18}F -FDG PET versus ^{11}C -MET PET] and comparisons of PET versus novel MR imaging techniques [eg, MR spectroscopy, diffusion-weighted imaging, and perfusion-weighted imaging]) and more complex testing strategies (eg, PET alone versus PET plus another non-PET technique) are particularly needed.

CONCLUSIONS

Both ^{18}F -FDG and ^{11}C -MET PET have moderately good overall accuracy for detecting recurrent glioma in patients with suspected recurrence following active treatment. Data on other PET tracers, though seemingly promising, are scarce. Comparative evidence is generally limited and whether a specific PET tracer outperforms others or whether PET is superior to alternative imaging modalities remains unclear. Prospective comparative studies are needed to elucidate the optimal imaging strategy for evaluating patients with suspected recurrent glioma.

ACKNOWLEDGMENTS

We thank Drs Masazumi Fujii and Shigenori Takebayashi (Department of Neurosurgery, Nagoya University Graduate School of Medicine) and Dr Yoshiro Ando (Department of Radiology, Nagoya University Graduate School of Medicine) for helpful comments on a previous version of the manuscript.

Disclosures: Takashi Nihashi—*RELATED: Grant:* The Ministry of Education, Culture, Sports, Science, and Technology of Japan (No. 21791183). Teruhiko Terawata—*RELATED: Grant:* ULIRRO25752 from the National Center for Research Resources,* *Comments:* Tufts-Clinical Translational Science Institute. *Money paid to the institution.

REFERENCES

1. **CBTRUS Statistical Report: Primary Brain and Central Nervous System Tumors Diagnosed in the United States in 2011; 2004–2007.** <http://www.cbtrus.org/2011-NPCR-SEER/WEB-0407-Report-3-3-2011.pdf>. Accessed October 3, 2012.
2. Wen PY, Kesari S. **Malignant gliomas in adults.** *N Engl J Med* 2008;359:492–507
3. National Cancer Comprehensive Network. **Clinical Practice Guidelines in Oncology: Central Nervous System Cancers.** Version 2.2011. 2011. http://www.nccn.org/professionals/physician_gls/f_guidelines.asp. Accessed on September 22, 2011.
4. Stupp R, Tonn JC, Brada M, et al. **High-grade malignant glioma: ESMO clinical practice guidelines for diagnosis, treatment and follow-up.** *Ann Oncol* 2010;21:v190–v193
5. Soffiotti R, Baumert BG, Bello L, et al. **Guidelines on management of low-grade gliomas: report of an EFNS-EANO* Task Force.** *Eur J Neurol* 2010;17:1124–33
6. Brandsma D, Stalpers L, Taal W, et al. **Clinical features, mechanisms, and management of pseudoprogression in malignant gliomas.** *Lancet Oncol* 2008;9:453–61
7. Wen PY, Macdonald DR, Reardon DA, et al. **Updated response assessment criteria for high-grade gliomas: response assessment in Neuro-Oncology Working Group.** *J Clin Oncol* 2010;28:1963–72
8. la Fougère C, Suchorska B, Bartenstein P, et al. **Molecular imaging of gliomas with PET: opportunities and limitations.** *Neuro-oncology* 2011;13:806–19
9. Dhermain FG, Hau P, Lanfermann H, et al. **Advanced MRI and PET imaging for assessment of treatment response in patients with gliomas.** *Lancet Neurol* 2010;9:906–20
10. Heiss WD, Raab P, Lanfermann H. **Multimodality assessment of brain tumors and tumor recurrence.** *J Nucl Med* 2011;52:1585–600
11. Whiting P, Rutjes AW, Reitsma JB, et al. **The development of QUADAS: a tool for the quality assessment of studies of diagnostic accuracy included in systematic reviews.** *BMC Med Res Methodol* 2003;3:25
12. Whiting PF, Weswood ME, Rutjes AW, et al. **Evaluation of QUADAS, a tool for the quality assessment of diagnostic accuracy studies.** *BMC Med Res Methodol* 2006;6:9
13. Reitsma JB, Glas AS, Rutjes AW, et al. **Bivariate analysis of sensitivity and specificity produces informative summary measures in diagnostic reviews.** *J Clin Epidemiol* 2005;58:982–90
14. Chu H, Cole SR. **Bivariate meta-analysis of sensitivity and specificity with sparse data: a generalized linear mixed model approach.** *J Clin Epidemiol* 2006;59:1331–32
15. Harbord RM, Deeks JJ, Egger M, et al. **A unification of models for meta-analysis of diagnostic accuracy studies.** *Biostatistics* 2007;8:239–51
16. Janus TJ, Kim EE, Tilbury R, et al. **Use of [18F]fluorodeoxyglucose positron emission tomography in patients with primary malignant brain tumors.** *Ann Neurol* 1993;33:540–48
17. Kahn D, Follett KA, Bushnell DL, et al. **Diagnosis of recurrent brain tumor: value of 201Tl SPECT vs 18F-fluorodeoxyglucose PET.** *AJR Am J Roentgenol* 1994;163:1459–65
18. Nelson SJ, Day MR, Buffone PJ, et al. **Alignment of volume MR images and high resolution [18F]fluorodeoxyglucose PET images for the evaluation of patients with brain tumors.** *J Comput Assist Tomogr* 1997;21:183–91
19. Ricci PE, Karis JP, Heiserman JE, et al. **Differentiating recurrent tumor from radiation necrosis: time for re-evaluation of positron emission tomography?** *AJNR Am J Neuroradiol* 1998;19:407–13
20. Sonoda Y, Kumabe T, Takahashi T, et al. **Clinical usefulness of 11C-MET PET and 201Tl SPECT for differentiation of recurrent glioma from radiation necrosis.** *Neurol Med Chir (Tokyo)* 1998;38:342–47, discussion 347–48
21. Bader JB, Samnick S, Moringlane JR, et al. **Evaluation of I-3-[123I]iodo-alpha-methyltyrosine SPET and [18F]fluorodeoxyglucose PET in the detection and grading of recurrences in patients**

- pretreated for gliomas at follow-up: a comparative study with stereotactic biopsy. *Eur J Nucl Med* 1999;26:144–51
22. Thompson TP, Lunsford LD, Kondziolka D. Distinguishing recurrent tumor and radiation necrosis with positron emission tomography versus stereotactic biopsy. *Stereotact Funct Neurosurg* 1999;73:9–14
 23. Belohlávek O, Klener J, Vymazal J, et al. The diagnostics of recurrent gliomas using FDG-PET: still questionable? *Nucl Med Rev Cent East Eur* 2002;5:127–30
 24. Pöpperl G, Gotz C, Rachinger W, et al. Value of O-(2-[18F]fluoroethyl)-L-tyrosine PET for the diagnosis of recurrent glioma. *Eur J Nucl Med Mol Imaging* 2004;31:1464–70
 25. Van Laere K, Ceysens S, Van CF, et al. Direct comparison of 18F-FDG and 11C-methionine PET in suspected recurrence of glioma: sensitivity, inter-observer variability and prognostic value. *Eur J Nucl Med Mol Imaging* 2005;32:39–51
 26. Rachinger W, Goetz C, Popperl G, et al. Positron emission tomography with O-(2-[18F]fluoroethyl)-L-tyrosine versus magnetic resonance imaging in the diagnosis of recurrent gliomas. *Neurosurgery* 2005;57:505–11
 27. Gómez-Río M, Rodríguez-Fernández A, Ramos-Font C, et al. Diagnostic accuracy of 201 thallium-SPECT and 18F-FDG-PET in the clinical assessment of glioma recurrence. *Eur J Nucl Med Mol Imaging* 2008;35:966–75
 28. Mehrkens JH, Popperl G, Rachinger W, et al. The positive predictive value of O-(2-[18F]fluoroethyl)-L-tyrosine (FET) PET in the diagnosis of a glioma recurrence after multimodal treatment. *J Neurooncol* 2008;88:27–35
 29. Terakawa Y, Tsuyuguchi N, Iwai Y, et al. Diagnostic accuracy of 11C-methionine PET for differentiation of recurrent brain tumors from radiation necrosis after radiotherapy. *J Nucl Med* 2008;49:694–99
 30. Nakajima T, Kumabe T, Kanamori M, et al. Differential diagnosis between radiation necrosis and glioma progression using sequential proton magnetic resonance spectroscopy and methionine positron emission tomography. *Neurol Med Chir (Tokyo)* 2009;49:394–401
 31. Jeong SY, Lee TH, Rhee CH, et al. 3'-deoxy-3'-[18F]fluorothymidine and O-(2-[18F]fluoroethyl)-L-tyrosine PET in patients with suspicious recurrence of glioma after multimodal treatment: initial results of a retrospective comparative study. *Nucl Med Mol Imaging* 2010;44:45–54
 32. Ozsunar Y, Mullins ME, Kwong K, et al. Glioma recurrence versus radiation necrosis? A pilot comparison of arterial spin-labeled, dynamic susceptibility contrast enhanced MRI, and FDG-PET imaging. *Acad Radiol* 2010;17:282–90
 33. Prat R, Galeano I, Lucas A, et al. Relative value of magnetic resonance spectroscopy, magnetic resonance perfusion, and 2-(18F) fluoro-2-deoxy-D-glucose positron emission tomography for detection of recurrence or grade increase in gliomas. *J Clin Neurosci* 2010;17:50–53
 34. Valk PE, Budinger TF, Levin VA, et al. PET of malignant cerebral tumors after interstitial brachytherapy: demonstration of metabolic activity and correlation with clinical outcome. *J Neurosurg* 1988;69:830–38
 35. Van Tassel P, Bruner JM, Maor MH, et al. MR of toxic effects of accelerated fractionation radiation therapy and carboplatin chemotherapy for malignant gliomas. *AJNR Am J Neuroradiol* 1995;16:715–26
 36. Tsuyuguchi N, Takami T, Sunada I, et al. Methionine positron emission tomography for differentiation of recurrent brain tumor and radiation necrosis after stereotactic radiosurgery—in malignant glioma. *Ann Nucl Med* 2004;18:291–96
 37. Miyashita M, Miyatake S, Imahori Y, et al. Evaluation of fluoride-labeled boronophenylalanine-PET imaging for the study of radiation effects in patients with glioblastomas. *J Neurooncol* 2008;89:239–46
 38. Dandois V, Rommel D, Renard L, et al. Substitution of 11C-methionine PET by perfusion MRI during the follow-up of treated high-grade gliomas: preliminary results in clinical practice. *J Neuroradiol* 2010;37:89–97
 39. Kim YH, Oh SW, Lim YJ, et al. Differentiating radiation necrosis from tumor recurrence in high-grade gliomas: assessing the efficacy of 18F-FDG PET, 11C-methionine PET and perfusion MRI. *Clin Neurol Neurosurg* 2010;112:758–65
 40. Spence AM, Muzi M, Link JM, et al. NCI-sponsored trial for the evaluation of safety and preliminary efficacy of 3'-deoxy-3'-[18F]fluorothymidine (FLT) as a marker of proliferation in patients with recurrent gliomas: preliminary efficacy studies. *Mol Imaging Biol* 2009;11:343–55
 41. Santra A, Kumar R, Sharma P, et al. F-18 FDG PET-CT in patients with recurrent glioma: comparison with contrast enhanced MRI. *Eur J Radiol* 2012;81:508–13
 42. Vander Borgh T, Asenbaum S, Bartenstein P, et al. EANM procedure guidelines for brain tumour imaging using labelled amino acid analogues. *Eur J Nucl Med Mol Imaging* 2006;33:1374–80
 43. Varrone A, Asenbaum S, Vander BT, et al. EANM procedure guidelines for PET brain imaging using [18F]FDG, version 2. *Eur J Nucl Med Mol Imaging* 2009;36:2103–10
 44. Alexiou GA, Tsiouris S, Kyritsis AP, et al. Glioma recurrence versus radiation necrosis: accuracy of current imaging modalities. *J Neurooncol* 2009;95:1–11
 45. Gatsonis C. The promise and realities of comparative effectiveness research. *Stat Med* 2010;29:1977–81, discussion 1996–97