

Are your **MRI contrast agents** cost-effective?

Learn more about generic **Gadolinium-Based Contrast Agents**.



AJNR

This information is current as of April 17, 2024.

**Predictors of Functional Outcome after
Emergency Carotid Artery Stenting and
Intra-Arterial Thrombolysis for Treatment of
Acute Stroke Associated with Obstruction of
the Proximal Internal Carotid Artery and
Tandem Downstream Occlusion**

H.S. Kwak, S.B. Hwang, G.Y. Jin, D.S. Hippe and G.H. Chung

AJNR Am J Neuroradiol published online 8 November 2012
<http://www.ajnr.org/content/early/2012/11/08/ajnr.A3304>

Predictors of Functional Outcome after Emergency Carotid Artery Stenting and Intra-Arterial Thrombolysis for Treatment of Acute Stroke Associated with Obstruction of the Proximal Internal Carotid Artery and Tandem Downstream Occlusion

H.S. Kwak, S.B. Hwang, G.Y. Jin, D.S. Hippe, and G.H. Chung



ABSTRACT

BACKGROUND AND PURPOSE: Patients who develop severe stroke symptoms due to acute internal carotid artery occlusion eventually in combination with a thromboembolic obstruction of the middle cerebral artery incur a major risk of developing extensive MCA infarction with a poor outcome. The purpose of this study was to evaluate the outcome for patients with tandem occlusions in the MCA and/or distal ICA, retrospectively, who had undergone stent implantation in the proximal segment of the ICA in addition to intra-arterial thrombolysis.

MATERIALS AND METHODS: Thirty-five patients with tandem occlusions of the MCA and/or distal ICA and acute occlusion of the proximal ICA underwent stent implantation for the proximal ICA occlusion and IAT for the tandem occlusion. Clinical outcome measures were assessed on admission and at discharge by using the National Institutes of Health Stroke Scale as well as 3 months after treatment by using the modified Rankin Scale.

RESULTS: The median NIHSS score on admission was 12 (range, 6–22). All patients had patent flow into the M1 and ICA after carotid artery stent placement and IAT. After the procedure, 19 patients (54.3%) were TICI grade III; 7 (20.0%), TICI grade IIb; and 9 (25.7%), TICI grade IIa. Symptomatic intracerebral hemorrhage occurred in 1 patient (2.9%). The overall mortality rate was 11.4% (4/35). At 3-month follow-up, the median NIHSS score was 4 (range, 1–17). NIHSS score at admission and TICI grade were all found to be independently associated with an unfavorable outcome at 3 months.

CONCLUSIONS: Initial stroke severity, degree of successful revascularization, and the side of ischemia were found to independently predict the functional outcome at 3 months after treatment.

ABBREVIATIONS: CAS = carotid artery stenting; IAT = intra-arterial thrombolysis; mRS = modified Rankin Scale; TICI = Thrombolysis in Cerebral Ischemia; UK = urokinase

Occlusion of the carotid artery is clinically silent or accompanied by only mild symptoms if there is adequate collateral flow.¹ However, there is a subgroup of patients who develop severe stroke symptoms due to acute internal carotid artery occlusion eventually in combination with a thromboembolic obstruction of the central arteries, such as the terminal carotid segment or the middle cerebral artery, and subsequently incur a major risk of developing extensive MCA infarction with a poor outcome.^{2,3} In this group of patients, early restoration of flow in the occluded ICA may

improve the symptoms of acute stroke, prevent stroke deterioration, and reduce the long-term stroke recurrence risk. Some authors have reported successful revascularization of patients with acute stroke symptoms secondary to ICA occlusions.^{4–8} However, previous studies have some potential drawbacks: 1) a broad range of time windows between symptom onset and treatment, 2) a small number of cases, 3) a small number of tandem lesions into the MCA and distal ICA, and 4) minor or mild neurologic deficits. Therefore, the purpose of our study was to evaluate retrospectively the outcome for patients with tandem lesions in the MCA and/or distal ICA who had undergone stent implantation in the proximal segment of the ICA in addition to intra-arterial thrombolysis.

MATERIALS AND METHODS

Patient Selection

This retrospective analysis was conducted with institutional review board approval. Between 2005 and 2010, patients with acute stroke symptoms who were admitted to our university-based

Received March 21, 2012; accepted after revision June 27.

From the Department of Radiology and Research Institute of Medical Science (H.S.K., S.B.H., G.Y.J., G.H.C.), Chonbuk National University Medical School and Hospital, Chonbuk, South Korea; and Department of Radiology (D.S.H.), University of Washington, Seattle, Washington.

Please address correspondence to Hyo-Sung Kwak, MD, Department of Radiology and Research Institute of Medical Science, Chonbuk National University Medical School and Hospital, 634-18, Keumam-Dong, Jeonju-shi, Chonbuk, 561-712, South Korea; e-mail: kwak8140@bnu.ac.kr

Indicates open access to non-subscribers at www.ajnr.org

<http://dx.doi.org/10.3174/ajnr.A3304>

stroke center within 6 hours of symptom onset were considered for inclusion in this study. The diagnosis of ischemic stroke was based on the presence of a focal neurologic deficit with or without demonstration of corresponding ischemic lesions. Permission for pharmacologic or mechanical thrombolytic treatment, including carotid artery stent placement and IAT, was obtained from the patient's legal representatives. The inclusion criteria for this study were the following: 1) occlusion of the ipsilateral proximal ICA, confirmed by angiography; 2) the presence of a tandem thrombotic lesion with acute complete obstruction of the distal ICA or MCA (M1 and/or M2), confirmed by intra-arterial digital subtraction angiography; 3) anterior circulation stroke symptoms within 6 hours before treatment; 4) CT or MR imaging exclusion of hemorrhage; and 5) CT signs of ischemia that affected less than one-third of the MCA territory. Angiography was performed by 1 interventional neuroradiologist with 5 years of experience in endovascular treatment.

Endovascular Treatment

On admission, the National Institutes of Health Stroke Scale score was assessed by a stroke neurologist. Eligible patients who met standard National Institute of Neurologic Disorders and Stroke criteria were treated with 0.9 mg/kg of IV rTPA.

Endovascular treatment was performed by the same interventional neuroradiologist. Routine 3- or 4-vessel cerebral angiography was performed before treatment for evaluation of collateral flow. Then the double coaxial system, which was assembled by combining an outermost 80-cm-long 8F introducer sheath (Super Arrow Flex; Arrow International, Reading, Pennsylvania) and an inner 100-cm-long 8F guiding catheter (Guider Softip; Boston Scientific, Natick, Massachusetts), was placed in the common carotid artery to enable placement of the carotid artery stent and the PS reperfusion catheter. Systemic anticoagulation was initiated with a 3000-U bolus of intravenous heparin followed by 1000-U/hr infusion. An end-hole microcatheter (Microferret; Cook, Bjæverskov, Denmark) over a straight microguidewire (Synchro-14; Boston Scientific) was advanced through an 8F guiding catheter. After complete occlusion was demonstrated, a microguidewire was gently passed into the ipsilateral common carotid artery, through the occlusion, and then into the distal cervical ICA. Repeat angiography of the ICA distal to the occlusion through microcatheter was performed to assess thrombus/occlusion in the intracranial circulation (tandem occlusion).

All patients included in this study had thrombus in the MCA and/or distal ICA segment. An embolic protection device was not used for any of these patients. The microcatheter was exchanged for a small-diameter (3.0-mm) angioplasty balloon, which was inflated to 6 atm to predilate the occlusion. Deployment of a self-expandable stent (Precise; Cordis, Miami Lakes, Florida), the size of which was chosen according to the presumed parent size, was performed over the wire. Poststenting angioplasty by using a 5- to 6-mm diameter balloon was performed to achieve a residual diameter stenosis of <20%.

After CAS, cerebral angiography was performed for evaluation of occlusion of the MCA and/or the distal ICA. An end-hole microcatheter was advanced over a microguidewire through an 8F guide catheter into the occlusion site in patients with M1, M2, or

distal ICA thrombus. The microcatheter tip was placed into the thrombus, and then a 100,000-U bolus of urokinase diluted to 10 mL in a mixture of saline and contrast medium (7:3) was manually infused for 3–5 minutes. We mixed the contrast medium for early detection of recanalization during UK infusion. We performed the repeat UK injection and mechanical clot disruption with a microcatheter and a microguidewire after cerebral angiography for evaluation of recanalization of the occluded vessel. Mechanical clot disruption was undertaken after 100,000 U of UK was administered. Mechanical clot maceration consisted of multiple passes of the microguidewire through the clot. The microguidewire was gently rotated clockwise, while being advanced. During this process, the microcatheter was often advanced multiple times over the microguidewire as well. After withdrawal of the microguidewire from the microcatheter, an additional 100,000 U of UK was manually infused for 3–5 minutes through the microcatheter at the site of the remaining thrombus. The UK infusions were stopped immediately if the control angiograms showed complete recanalization.

Mechanical clot disruption by using a microcatheter and a microguidewire was reattempted if recanalization was not achieved after UK infusion. One patient with distal migration of thrombus into the posterior cerebral artery was additionally infused with 100,000 U of UK through a microcatheter at the site of the occluded artery. The patients who did not achieve complete recanalization after mechanical clot disruption by using a microcatheter and a UK infusion underwent percutaneous angioplasty. Patients with distal ICA thrombus underwent the combined procedure, such as aspiration thrombectomy with a 5F catheter and/or reperfusion catheter, UK injection, and mechanical clot disruption, with a microcatheter and microguidewire.

Each patient was given an oral load of clopidogrel (300 mg) immediately after the procedure, and each received maintenance doses of both aspirin (100 mg daily) and clopidogrel (75 mg daily) starting the day after the procedure. In addition, strict blood pressure guidelines were adhered to by maintaining a mean blood pressure of <100 mmHg for at least 48 hours after revascularization in the Neuro Intensive Care Unit because of concerns of hyperperfusion to the ipsilateral hemisphere.

Data Collection

Pretreatment and posttreatment angiograms were evaluated by the same interventional neuroradiologist. The recanalization status was classified according to the Thrombolysis in Cerebral Ischemia perfusion scale. TICI perfusion categories include grade 0 (no perfusion), grade I (penetration with minimal perfusion), grade II (partial perfusion), grade IIa (partial perfusion with incomplete distal filling of <50% of the expected territory), grade IIb (partial perfusion with incomplete distal filling of 50%–99% of the expected territory), and grade III (full perfusion with normal filling of the distal branches in a normal hemodynamic fashion). Recanalization was defined as TICI grade II or III.

For each patient, age, sex, NIHSS score on admission, time from symptoms to IA therapy, duration of the procedure, UK dose, recanalization status, occurrence of symptomatic intracranial hemorrhage, and modified Rankin Scale score at discharge were recorded. After 3 months, the patients were brought back for

another clinical evaluation and updated NIHSS and mRS scores were recorded. The clinical evaluation was performed by stroke neurologists who were not blinded to the treatment. The primary clinical outcome was the mRS at 3 months, which was further dichotomized as favorable (mRS \leq 2) or unfavorable (mRS $>$ 2).

Statistical Analysis

Continuous values are expressed as the interquartile range and/or the range. Categorical variables are summarized by using counts and percentages. Patients were grouped by favorable (mRS \leq 2) and unfavorable (mRS $>$ 2) outcomes at 3 months. Continuous and categorical variables were compared between these groups by using the Mann-Whitney *U* test and Fisher exact test, respectively. Linear trends between favorable/unfavorable outcome and TICI grade were tested by using the χ^2 test for trend. Multivariate analysis for favorable/unfavorable outcome was conducted by using logistic regression. Variables with *P* $<$.20 from univariate analysis were taken as candidate predictors and were entered into a backward-selection algorithm to identify a set of independent predictors. Statistical significance was defined as *P* $<$.05. All statistical analysis was performed by using R 2.14.1 (R Foundation for Statistical Computing, Vienna, Austria).

RESULTS

Between 2005 and 2010, two hundred fifty-four consecutive patients with acute ischemic stroke were admitted to our institution within 6 hours of onset of symptoms. Of these patients, 42 were confirmed to have proximal ICA occlusion, tandem thrombotic distal ICA/MCA occlusion, and ischemia affecting less than one-third of the MCA territory by CT. Five patients did not undergo recanalization of the ICA obstruction either because there was good or moderate leptomeningeal collateral flow and/or contralateral collateral flow to the territory of the occluded MCA (*n* = 3) or because CT showed that the ischemia affected more than one-third of the MCA territory (*n* = 2). Two patients were lost to follow-up and did not receive a clinical evaluation at 3 months, leaving 35 patients available for analysis.

Baseline clinical characteristics and preprocedural findings are summarized in Table 1. Most patients were men (88.6%) with ages between 51 and 84 years (median, 65 years). Six (17.1%) had a medical history of stroke. The time from symptom onset to admission ranged from 60 to 340 minutes (median, 180 minutes), and the time from onset to IAT ranged from 140 to 435 minutes (median, 270). The median NIHSS score at admission was 12 (range, 6–22). Eight patients (22.9%) received IV rtPA before angiography. All patients had a tandem thrombotic occlusion distal to the primary ICA occlusion. Twenty-five (71.4%) patients had a tandem intracranial occlusion in M1, and 5 (14.3%) had an occlusion in M2. The remaining 5 had an occlusion of distal ICA.

Table 1 also summarizes the clinical findings during and after the interventional procedure. The technical success rate of the carotid artery stent placement after passage of the microguidewire was 100%. The median duration of IA therapy was 90 minutes (range, 40–180 minutes). The total UK dose used most was frequently 100,000 U, but the dose ranged up to 500,000 U in some cases. All patients had patent flow into the M1 and ICA after carotid artery stent placement and IAT (TICI grade II or III). After

Table 1: Summary of patient demographics, preprocedural findings, periprocedural findings, and outcomes after 3 months

Patient Demographics	No. (%) or Median (IQR)	Range
Age (yr)	65 (63–76)	51–84
Male	31 (88.6)	–
Previous medical history	–	–
Diabetes mellitus	7 (20.0)	–
Hypertension	19 (54.3)	–
Hypercholesterolemia	10 (28.6)	–
Smoking	17 (48.6)	–
Cardiac disease	5 (14.3)	–
Prior stroke	6 (17.1)	–
Preprocedural findings		
Time to hospital (min) ^a	180 (125–210)	60–340
Time to IA therapy (min) ^a	270 (190–310)	140–435
NIHSS at admission	12 (8–17)	6–22
Modified Rankin scale	4 (3–4)	3–5
3	11 (31.4)	–
4	21 (60.0)	–
5	3 (8.6)	–
Right-sided occlusion	15 (42.9)	–
Tandem occlusion site	–	–
M1	25 (71.4)	–
M2	5 (14.3)	–
Distal ICA thrombus	5 (14.3)	–
Received IV rtPA	8 (22.9)	–
Periprocedural findings		
Procedure duration (min)	90 (68–120)	40–180
Urokinase dose ($\times 10^4$ U)	10 (10–30)	10–50
TICI grade	–	–
IIa	9 (25.7)	–
IIb	7 (20.0)	–
III	19 (54.3)	–
Complications	2 (5.7)	–
Symptomatic hemorrhage	1 (2.9)	–
Brain swelling	1 (2.9)	–
Follow-up evaluation at 3 months		
NIHSS ^b	4 (2–7)	1–17
Modified Rankin Scale	2 (1–3)	0–6
0	3 (8.6)	–
1	11 (31.4)	–
2	8 (22.9)	–
3	5 (14.3)	–
4	4 (11.4)	–
5	0 (0.0)	–
6	4 (11.4)	–
Favorable outcome	22 (62.9)	–
Mortality	4 (11.4)	–

Note:—IQR indicates interquartile range; IA indicates intra-arterial.

^a From onset of symptoms.

^b Excluding the 4 patients who died within 3 months. Favorable outcome was defined as a modified Rankin Scale score of \leq 2 at 3 months.

the procedure, 19 patients (54.3%) were classified as TICI grade III, 7 (20.0%) as TICI grade IIb, and 9 (25.7%) as TICI grade IIa.

No procedure-related complications such as vessel rupture or dissection were observed. However, symptomatic intracerebral hemorrhage occurred in 1 patient (2.9%) after the procedure. Another patient underwent decompressive surgery due to brain swelling and edema. Even though they received intravenous rtPA injections because of early admission after symptom onset, 2 patients had high initial NIHSS scores (20 and 22) and showed severe deterioration immediately after the procedure and later died.

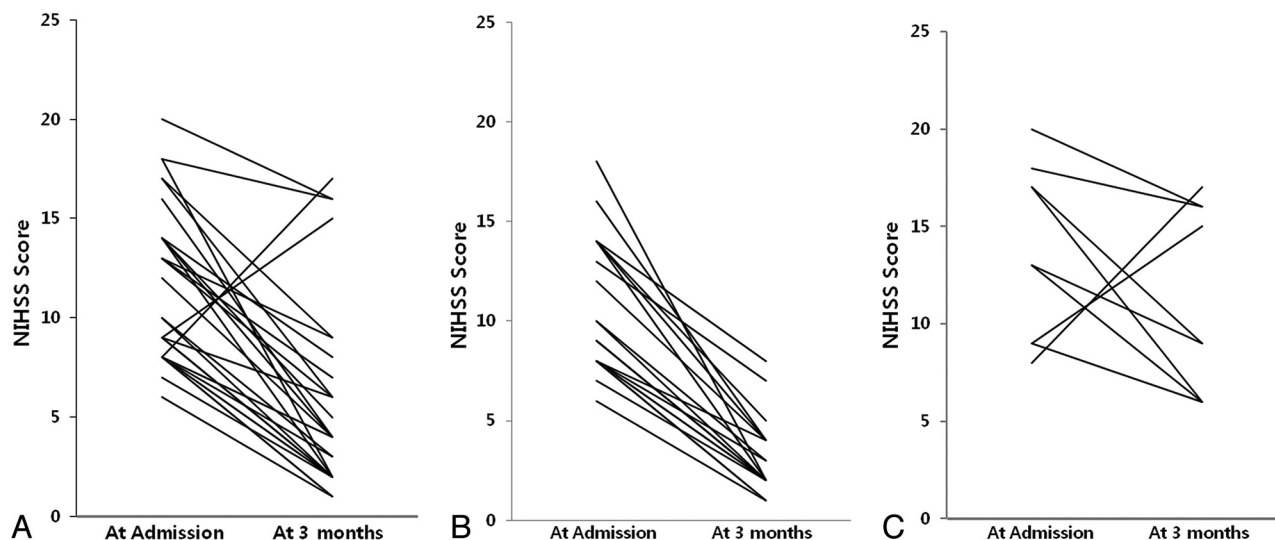


FIG 1. The NIHSS score on admission and at 3 months. *A*, NIHSS score of all patients ($n = 31$) excluding 4 patients who died. Median NIHSS scores were 12 on admission and 4 at 3 months (3 patients went from 9 to 2, three patients went from 8 to 1, and 2 patients went from 9 to 1). *B*, NIHSS scores of patients ($n = 22$) with favorable outcomes (mRS, 0–2) (3 patients went from 9 to 2, three patients went from 8 to 1, and 2 patients went from 9 to 1). Median NIHSS scores were 9 and 2. *C*, NIHSS scores of patients ($n = 9$) with unfavorable outcomes (mRS, 3–6). Median NIHSS scores were 17 and 9, respectively.

Another 2 patients who were neurologically stable after the procedure died 30 days later secondary to pneumonia and sepsis. Therefore, the overall mortality rate was 11.4%.

At 3 months, the median NIHSS score of the patients who did not die was 4 (range, 1–17) (Fig 1). All except 2 demonstrated improved NIHSS scores at 3 months. However, 13 patients (37.1%) had unfavorable functional outcomes (mRS > 2, including the 4 who died). Table 2 compares the patient demographics, procedural findings, and follow-up evaluations between those with favorable and unfavorable outcomes. On average, those with unfavorable outcomes tended to be older ($P = .040$), have higher initial NIHSS ($P = .003$) and mRS ($P = .005$) scores, and have a right-sided occlusion ($P = .032$) and a lower TICI grade ($P = .006$). They also had higher NIHSS scores at 3 months.

Multivariate logistic regression was used to identify independent predictors of unfavorable functional outcome. A backward-selection algorithm was applied to the variables with $P < .20$ during univariate analysis. NIHSS scores at admission, TICI grades, and the presence of a right-sided occlusion were all found to be independently associated with unfavorable outcome at 3 months (Table 3). While very large odds ratios were seen for the latter 2, the confidence intervals were also quite wide, indicating substantial uncertainty as to the true magnitudes of the associations.

DISCUSSION

Many authors have reported the clinical usefulness of stent-assisted thrombolysis in patients with acute occlusion of the extracranial ICA.^{4–9} Emergency carotid artery stent placement is expected to reopen an extracranial ICA occlusion with reduction in cerebral blood flow in the affected hemisphere. Also, early flow restoration across the tandem lesion in the MCA and/or distal ICA after extracranial ICA stent placement would aim to reverse the ischemic process by stopping the expansion of the ischemic core into the penumbra. Because the size of the ischemic core is

known to correlate with clinical outcome, this approach is expected to maximize the chances of a favorable outcome.¹⁰

Nedelchev et al⁵ reported on 25 patients with acute stroke and acute occlusion of the proximal carotid artery who had been treated by pharmacomechanical lysis and stent implantation into the ICA. They were compared with a group of patients ($n = 31$) who had received heparinization and antiplatelet medication but in whom no recanalization of the carotid artery had been attempted. In the stented group, 5 of 25 (20%) patients died, as did 5 of 31 in the medication group (16%). The authors reported a favorable outcome in 56% of those in the recanalization group and in only 26% of those in the medication group. Although there was a relatively short follow-up duration in our study, 22 of 35 patients (62.9%) patients showed favorable clinical outcomes (mRS ≤ 2).

Tandem obstruction of both the ICA and the MCA is frequently highly symptomatic, and only 20% of cases are associated with a good outcome (mRS ≤ 2) despite intravenous thrombolysis.¹⁰ Patients with tandem occlusion had worse short- and long-term clinical outcomes. Linfante et al¹¹ found a recanalization rate of 31% with intravenous thrombolysis in patients with ICA occlusion compared with 88% in patients with MCA occlusion. Jovin et al⁴ reported that patients without a tandem occlusion were more likely to show rapid neurologic improvement within the first 24 hours after carotid artery stent placement and an mRS ≤ 2 at follow-up. In our study, all patients had a tandem lesion in the MCA and/or distal ICA. Good outcomes (mRS ≤ 2 at 3 months) in our study were found in 62.9% of the patients compared with 56% of patients who reached an mRS score of ≤ 2 at 3 months in a previous study.⁵

Prognostic factors for outcomes in previous studies include the site of arterial occlusion, initial clinical status, time to thrombolysis, presence of symptomatic hemorrhage, or recanalization achievement.^{11–15} On the basis of the evaluation of predictors of

Table 2: Comparisons between patients who had favorable and unfavorable outcomes 3 months after recanalization

Patient Demographics	% or Median (IQR)		P
	Favorable Outcome (n = 22)	Unfavorable Outcome (n = 13)	
Age (yr)	64 (61–69)	73 (65–77)	.040
Male	90.9	84.6	.618
Medical history	–	–	–
Diabetes mellitus	22.7	15.4	.689
Hypertension	54.5	53.8	1.000
Hypercholesterolemia	27.3	30.8	1.000
Smoking	45.5	53.8	.733
Cardiac disease	18.2	7.7	.630
Prior stroke	9.1	30.8	.166
Preprocedural findings			
Time to hospital (min) ^a	180 (138–208)	180 (100–210)	.851
Time to IA therapy (min) ^a	255 (200–279)	280 (180–360)	.669
NIHSS score at admission	9 (8–14)	17 (13–18)	.003
Modified Rankin Scale score	4 (3–4)	4 (4–4)	.005
3	45.5	7.7	.027
4	54.5	69.2	.486
5	0.0	23.1	.044
Right-sided occlusion	27.3	69.2	.032
Tandem occlusion site	–	–	.247 ^b
M1	63.6	84.6	.259
M2	22.7	0.0	.134
Distal ICA thrombus	13.6	15.4	1.000
Received IV rtPA	18.2	30.8	.433
Periprocedural findings			
Procedure duration (min)	90 (66–128)	95 (70–110)	.891
Urokinase dose (×10 ⁴ U)	10 (10–30)	20 (10–20)	.648
TICI grade	–	–	.006 ^c
IIa	9.1	53.8	.006
IIb	22.7	15.4	.689
III	68.2	30.8	.043
Complications	0.0	15.4	.144
Symptomatic hemorrhage	0.0	7.7	.371
Brain swelling	0.0	7.7	.371
Follow-up evaluation at 3 months			
NIHSS score ^d	2 (2–4)	9 (6–16)	<.001

Note:—IQR indicates interquartile range; IA, intra-arterial.

^a From onset of symptoms.

^b Fisher exact test.

^c χ^2 test for trend. Favorable outcome was defined as a modified Rankin Scale score of ≤ 2 at 3 months.

^d Excluding the 4 patients who died within 3 months.

Table 3: Multivariate logistic regression results for independent predictors of an unfavorable outcome after 3 months^a

Predictor	Univariate		Multivariate	
	OR (95% CI)	P	OR (95% CI)	P
NIHSS score at admission (per unit change)	1.4 (1.1–1.7)	.003	1.8 (1.1–3.1)	.022
TICI grade IIa	11.7 (1.9–71.8)	.006	458 (3.4–627)	.015
Right-sided occlusion	6.0 (1.3–27.0)	.032	31.9 (1.1–9.1)	.043

Note:—OR indicates odds ratio; CI, confidence interval.

^a Variables were chosen by backward selection. Univariate columns show results for each variable fit separately. Multivariate columns show results from a single model fitting all variables simultaneously.

good outcome, our results indicate that better outcomes were related to younger age, lower initial NIHSS scores, left-sided occlusions, and TICI grades IIb or III after revascularization. The latter 3 were selected as independent predictors during multivariate analysis. Also, Suh et al¹⁴ reported that better short- and long-term outcomes were related to the degree of distal residual occlusion

after revascularization in acute symptomatic ICA occlusion. We suggest that adequate distal filling of cerebral arteries is a simple and critical predictor of good outcome in acute symptomatic ICA occlusion.

There were no serious procedure-related complications such as dissection or vessel rupture in our study. In 1 patient, a symptomatic intracerebral hemorrhage was observed on CT 24 hours after the procedure. Also, 1 patient underwent decompressive surgery due to brain swelling and edema. Most interesting, we observed a lower mortality rate of 11% in our series in contrast to the study by Nedeltchev et al (20%).⁵ We hypothesize that the use of new devices in our study and technical advances that have occurred since the time of the study of Nedeltchev et al, such as mechanical clot disruption and the mechanical thrombectomy device, most likely contributed to this rate.

The present study had a number of limitations. First, it was retrospective, so it was prone to selection and other biases. Second, we used multiple thrombectomy techniques for treatment of tandem occlusion, such as pharmacologic thrombolysis, mechanical clot disruption, or a mechanical thrombectomy device, making it difficult to determine the effect of the constituent techniques. Third, we did not have a control group with which to compare outcome rates. Last, we did not perform perfusion imaging in all patients before revascularization to quantify the ischemic area.

CONCLUSIONS

Our study showed that endovascular treatment by carotid artery stent placement and

IAT seems to improve outcome in patients with acute stroke caused by tandem occlusion of the MCA and/or distal ICA that results from ICA occlusion. Stroke severity, degree of successful revascularization, and the side of ischemia were found to independently predict functional outcomes at 3 months after treatment.

REFERENCES

1. Thanvi B, Robinson T. **Complete occlusion of extracranial internal carotid artery: clinical features, pathophysiology, diagnosis and management.** *Postgrad Med J* 2007;83:95–99
2. Meves SH, Muhs A, Federlein J, et al. **Recanalization of acute symptomatic occlusions of the internal carotid artery.** *J Neurol* 2002;249:188–92
3. Adams HP Jr, Bendixen BH, Leira E, et al. **Antithrombotic treatment of ischemic stroke among patients with occlusion or severe stenosis of the internal carotid artery: a report of the Trial of Org 10172 in Acute Stroke Treatment (TOAST).** *Neurology* 1999;53:122–25
4. Jovin TG, Gupta R, Uchino K, et al. **Emergent stenting of extracra-**

- nial internal carotid artery occlusion in acute stroke has a high revascularization rate. *Stroke* 2005;36:2426–30
5. Nedeltchev K, Brekenfeld C, Remonda L, et al. **Internal carotid artery stent implantation in 25 patients with acute stroke: preliminary results.** *Radiology* 2005;37:1029–37
 6. Imai K, Mori T, Izumoto H, et al. **Emergency carotid artery stent placement in patients with acute ischemic stroke.** *AJNR Am J Neuroradiol* 2005;26:1249–58
 7. Lee HO, Koh EJ, Choi HY. **Emergency carotid artery stent insertion for acute ICA occlusion.** *J Korean Neurosurg Soc* 2010;47:428–32
 8. Kao HL, Lin MS, Wang CS, et al. **Feasibility of endovascular recanalization for symptomatic cervical internal carotid artery occlusion.** *J Am Coll Cardiol* 2007;49:765–71
 9. Mourand I, Brunel H, Vendrell JF, et al. **Endovascular stent-assisted thrombolysis in acute occlusive carotid artery dissection.** *Neuroradiology* 2010;52:135–40
 10. Rubiera M, Ribo M, Delgado-Mederos R, et al. **Tandem internal carotid artery/middle cerebral artery occlusion: an independent predictor of poor outcome after systemic thrombolysis.** *Stroke* 2006;37:2301–05
 11. Linfante I, Linas RH, Selim M, et al. **Clinical and vascular outcome in internal carotid artery versus middle cerebral artery occlusions after intravenous tissue plasminogen activator.** *Stroke* 2002;33:2066–71
 12. Ernst R, Pancioli A, Tomsick K, et al. **Combined intravenous and intra-arterial recombinant tissue plasminogen activator in acute ischemic stroke.** *Stroke* 2000;31:2552–57
 13. Zaidat OO, Suarez JJ, Santillan C, et al. **Response to intra-arterial and combined intravenous and intra-arterial thrombolytic therapy in patients with distal internal carotid artery occlusion.** *Stroke* 2002;33:1821–26
 14. Suh DC, Kim JK, Choi CG, et al. **Prognostic factors for neurologic outcome after endovascular revascularization of acute symptomatic occlusion of the internal carotid artery.** *AJNR Am J Neuroradiol* 2007;28:1167–71
 15. Rha JH, Saver IL. **The impact of recanalization on ischemic stroke outcome: a meta-analysis.** *Stroke* 2007;38:967–73