

Are your MRI contrast agents cost-effective?

Learn more about generic Gadolinium-Based Contrast Agents.



FRESENIUS
KABI

caring for life

AJNR

Optic Canal Narrowing in Hunter Syndrome (Mucopolysaccharidosis II)

A. Sen

AJNR Am J Neuroradiol published online 31 January 2013
<http://www.ajnr.org/content/early/2013/01/31/ajnr.A3499.citation>

This information is current as
of April 23, 2024.

Optic Canal Narrowing in Hunter Syndrome (Mucopolysaccharidosis II)

I read with interest the article “Brain and Spinal MR Imaging Findings in Mucopolysaccharidoses: A Review”¹ and would like to illustrate optic canal narrowing in a patient with Hunter syndrome (mucopolysaccharidosis [MPS]-II).

A 6-year-old boy presented with significant loss of vision. He had been evaluated (at 3 years of age) for mucopolysaccharidosis; clinical phenotype, heparin sulfate in urine electrophoresis, and plasma enzyme levels (iduronate 2-sulfatase level: 4.2 nmol/h by fluorimetric assay by using 4-methyl umbelliferone; normal range: 167–475 nmol/h; control: 194.3) were suggestive of Hunter syndrome.

MR imaging of the brain showed periventricular white matter hyperintensities (Fig 1A–C), enlarged Virchow-Robin spaces (Fig 1A, -B), ventriculomegaly, and atrophy (Fig 1A–C, -E, -F), known features of mucopolysaccharidosis. The bilateral optic canals were symmetrically narrowed (Fig 1D–F), and hyperintensities were noted around both optic nerves (Fig 1C–F).

Hunter syndrome, or mucopolysaccharidosis II, is an X-linked progressive lysosomal storage disease due to deficiency of the lysosomal enzyme iduronate-2-sulfatase. Known ocular manifestations of Hunter syndrome include exophthalmos, hypertelorism, pigmentary retinopathy, uveal effusion, optic nerve

head swelling (disc edema,² possibly due to compression by scleral deposits), and optic atrophy.

Optic canal narrowing is a known feature of osteopetrosis,³ and fibrous dysplasia and has been described in familial hypophosphatemic rickets, carbonic anhydrase type 2 deficiency (which includes osteopetrosis), and MPS-4.⁴ It has not been previously reported in Hunter syndrome. Perhaps optic canal narrowing is underdiagnosed in Hunter syndrome because intellectually impaired children may not be able to describe visual loss.

REFERENCES

1. Zafeiriou DI, Batziou SP. **Brain and spinal MR imaging findings in mucopolysaccharidoses: a review.** *AJNR Am J Neuroradiol* 2012 Jul 12. [Epub ahead of print]
2. Beck M, Cole G. **Disc oedema in association with Hunter's syndrome: ocular histopathological findings.** *Br J Ophthalmol* 1984;68:590-94
3. Curé JK, Key LL, Goltra DD, et al. **Cranial MR imaging of osteopetrosis.** *AJNR Am J Neuroradiol* 2000;21:1110–15
4. Vougioukas VI, Berlis A, Kopp MV, et al. **Neurosurgical interventions in children with Maroteaux-Lamy syndrome: case report and review of the literature.** *Pediatr Neurosurg* 2001;35:35–38

A. Sen
Radiodiagnosis
Devi Scans
Kerala, India

<http://dx.doi.org/10.3174/ajnr.A3499>

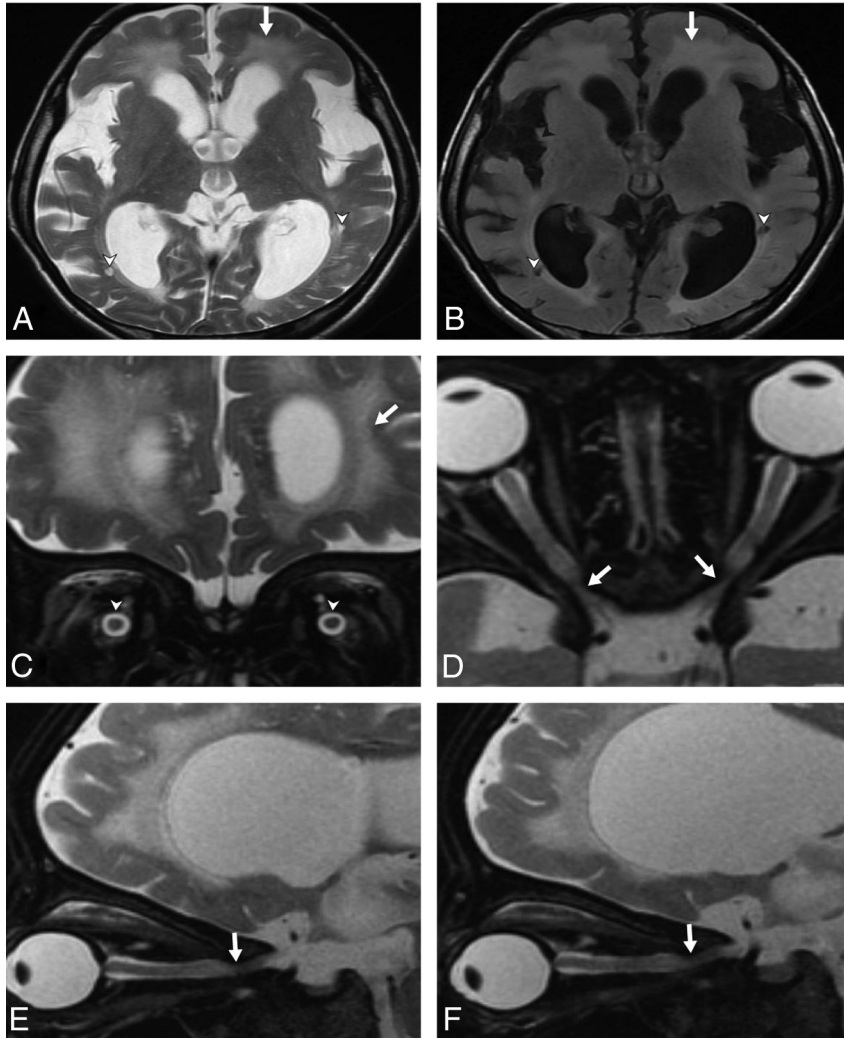


FIG 1. Axial T2 (A) and axial T2 FLAIR (B) images show periventricular white matter hyperintensities (*arrows*), prominent Virchow-Robin spaces (*arrowheads*), ventriculomegaly, and brain atrophy. C, Coronal T2 image shows hyperintensities in periventricular white matter (*arrows*) and perioptic spaces (*arrowheads*), ventriculomegaly, and brain atrophy. Axial T2 (D) and right (E) and left (F) sagittal T2 images show narrowing of the optic canals (*arrows*), hyperintensities in perioptic spaces, and brain atrophy.