

Are your MRI contrast agents cost-effective?

Learn more about generic Gadolinium-Based Contrast Agents.



FRESENIUS
KABI

caring for life

AJNR

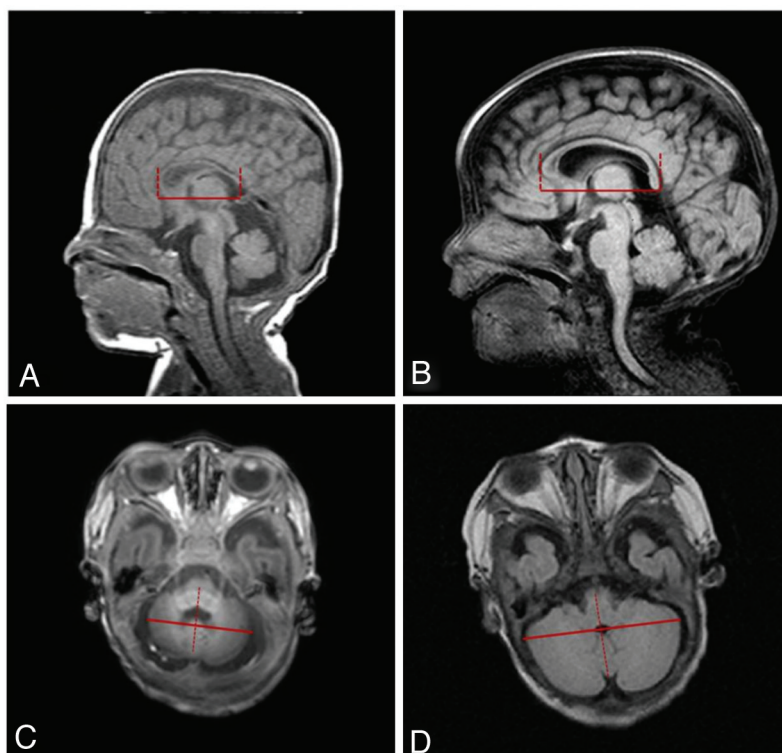
Erratum

AJNR Am J Neuroradiol published online 24 April 2014
<http://www.ajnr.org/content/early/2014/04/24/ajnr.A3963.citation>

This information is current as
of April 19, 2024.

Due to a print production error, Fig 1 in the article “Brain MRI Measurements at a Term-Equivalent Age and Their Relationship to Neurodevelopmental Outcomes” by H.W. Park, H.-K. Yoon, S.B. Han, B.S. Lee, I.Y. Sung, K.S. Kim, and E.A. Kim [*AJNR Am J Neuroradiol* 2014;35:599–603] did not contain tabular material that was part of the illustration. The correct image is displayed here.

<http://dx.doi.org/10.3174/ajnr.A3963>



Measurements	Intra-observer ICC [CI]	Inter-observer ICC [CI]
TCD	0.895 [0.831–0.933]	0.679 [0.479–0.811]
Length of corpus callosum	0.564 [0.404–0.690]	0.808 [0.595–0.903]

FIG 1. Linear measurements of anteroposterior length of corpus callosum (A and B) and transverse cerebellar diameter (C and D) and intraclass correlation coefficients (ICCs) for interobserver and intraobserver reliability. A, Short anteroposterior length of corpus callosum (34.1 mm); B, longer anteroposterior length of corpus callosum (44.4 mm); C, short transverse cerebellar diameter (36.2 mm); D, longer transverse cerebellar diameter (58.4 mm).