

Are your MRI contrast agents cost-effective?

Learn more about generic Gadolinium-Based Contrast Agents.



FRESENIUS
KABI

caring for life

AJNR

**Site and Rate of Occlusive Disease in
Cervicocerebral Arteries: A CT Angiography
Study of 2209 Patients with Acute Ischemic
Stroke**

D.C. Rotzinger, P.J. Mosimann, R.A. Meuli, P. Maeder and
P. Michel

This information is current as
of April 17, 2024.

AJNR Am J Neuroradiol published online 16 March 2017
<http://www.ajnr.org/content/early/2017/03/16/ajnr.A5123>

Site and Rate of Occlusive Disease in Cervicocerebral Arteries: A CT Angiography Study of 2209 Patients with Acute Ischemic Stroke

 D.C. Rotzinger,  P.J. Mosimann,  R.A. Meuli,  P. Maeder, and  P. Michel



ABSTRACT

BACKGROUND AND PURPOSE: CTA can rapidly and accurately detect and localize occlusive disease in patients with ischemic stroke. We have used CTA to assess arterial stenosis and occlusion in an ischemic stroke population arriving at a tertiary stroke center within 24 hours of symptom onset in order to obtain a comprehensive picture of occlusive disease pattern, and to determine the proportion of eligible candidates for endovascular treatment.

MATERIALS AND METHODS: Data from consecutive patients with acute ischemic stroke admitted to a single center between 2003 and 2012, collected in the Acute Stroke Registry and Analysis of Lausanne data base, were retrospectively analyzed. Patients with a diagnostic CTA within 24 hours of symptom onset were selected. Relevant extra- and intracranial pathology, defined as stenosis of $\geq 50\%$ and occlusions, were registered and classified into 21 prespecified segments.

RESULTS: Of the 2209 included patients (42.1% women; median age, 72 years), 1075 (48.7%) had pathology in and 308 (13.9%) had pathology outside the ischemic territory. In the 50,807 arterial segments available for revision, 1851 (3.6%) abnormal segments were in the ischemic (symptomatic) territory and another 408 (0.8%) were outside it (asymptomatic). In the 1211 patients with ischemic stroke imaged within 6 hours of symptom onset, 40.7% had symptomatic large, proximal occlusions potentially amenable to endovascular therapy.

CONCLUSIONS: CTA in patients with acute ischemic stroke shows large individual variations of occlusion sites and degrees. Approximately half of such patients have no visible occlusive disease, and 40% imaged within 6 hours show large, proximal segment occlusions amenable to endovascular therapy. These findings show the importance of early noninvasive imaging of extra- and intracranial arteries for identifying occlusive disease, planning recanalization strategies, and designing interventional trials.

ABBREVIATIONS: AIS = acute ischemic stroke; ASTRAL = Acute Stroke Registry and Analysis of Lausanne

More than 80% of strokes are ischemic, usually caused by large-artery atherosclerosis, cardiac embolism, or cerebral microangiopathy.¹ CTA or MR arterial neuroimaging is fre-

quently used at admission^{2,3} to determine occlusion sites and clot extent and to plan acute recanalization strategies.⁴⁻⁷ CTA is widely available and allows rapid assessment of the entire arterial vasculature from the aortic arch to the vertex. In addition, it accurately depicts arterial occlusive disease with good interrater agreement.⁸ Most clinically relevant arterial occlusive disease is found in the extra- and intracranial arteries, supporting aortic arch-to-vertex CTA for patients with acute ischemic stroke (AIS).⁹ Potential drawbacks of CTA are iodinated contrast allergy and radiation exposure.

The purpose of this study was to obtain a comprehensive picture of cerebrovascular occlusive disease in a representative AIS population, using admission CTA, to determine the proportion of eligible candidates for endovascular treatment. Such patients were identified by looking for symptomatic proximal arterial occlusions readily accessible with endovascular devices. Moreover, we aimed at determining the proportion


Received August 23, 2016; accepted after revision December 13.


From the Department of Diagnostic and Interventional Radiology (D.C.R., P.J.M., R.A.M., P. Maeder) and Neurology Service (P. Michel), Department of Clinical Neurosciences, Centre Hospitalier Universitaire Vaudois, Lausanne, Switzerland. David C. Rotzinger and Pascal J. Mosimann contributed equally to this work.


The Swiss Heart Foundation supported this project.

Paper previously presented at: The Joint annual meeting 2014 (Swiss Society of Intensive Care Medicine, 190th Annual Meeting of the Swiss Neurological Society, Swiss Society of Neuroradiology SSNR Educational Course 2014, Swiss Stroke Society, Swiss Society of Emergency Medicine), October 29–31, 2014; Congress Centre Kursaal Interlaken, Switzerland; and Annual Meeting of the Swiss Congress of Radiology, June 8–10, 2014; Davos, Switzerland.

Please address correspondence to David C. Rotzinger, MD, Department of Diagnostic and Interventional Radiology, Centre Hospitalier Universitaire Vaudois, Rue du Bugnon 46, 1011 Lausanne, Switzerland; e-mail: david.rotzinger@chuv.ch

 Indicates open access to non-subscribers at www.ajnr.org

 Indicates article with supplemental on-line tables.

 Indicates article with supplemental on-line photos.

<http://dx.doi.org/10.3174/ajnr.A5123>

of patients with abnormal segments in ischemic and nonischemic territories and describing the distribution of arterial occlusive disease in extra- versus intracranial vessels, anterior-versus-posterior circulation, and serial (tandem) pathologies.

MATERIALS AND METHODS

Patients

We used the patients admitted with AIS between January 2003 and December 2012 from the prospectively constructed Acute Stroke Registry and Analysis of Lausanne (ASTRAL), which collects information on all patients with AIS referred to the stroke center and/or intensive care unit of Lausanne University hospital (Centre Hospitalier Universitaire Vaudois) within 24 hours of the last-known-well time.¹ We included all consecutive patients who had a diagnostic CTA available for analysis. CTA studies were rated as diagnostic or nondiagnostic by at least 2 authors, and the latter studies were excluded when at least 1 author considered them nondiagnostic (On-line Fig 1). A diagnostic CTA provides a sharp delineation of head and neck vessels, allowing evaluation of partial or complete filling defects. Patients arriving later than 24 hours from symptom onset and presenting with transient ischemic attack, cerebral or subarachnoid hemorrhage, persistent retinal ischemia, amaurosis fugax, and spinal cord ischemia were excluded. Reasons for exclusion were collected.

CTA-based imaging information, demographic data, cardiovascular risk factors, and ischemic side and territory were extracted and analyzed retrospectively. Stroke was categorized according to the TOAST (Trial of ORG 10172 in Acute Stroke Treatment) classification,¹⁰ and we added dissection, likely patent foramen ovale–related stroke, and combinations of mechanisms.

Neuroimaging Protocol

All included patients underwent standard AIS imaging, including noncontrast head CT, cerebral perfusion CT, and cervicocerebral CT angiography. In patients undergoing thrombolysis, CTA was acquired immediately before or immediately after the rtPA bolus; therefore, this process made it unlikely that thrombolysis influenced the arterial occlusive pathology. Imaging was performed on a 16–detector row CT scanner (LightSpeed 16 Advantage; GE Healthcare, Milwaukee, Wisconsin) until November 2005 and afterwards on a 64–detector row CT scanner (LightSpeed VCT 64; GE Healthcare). Technical parameters for cerebral and extracranial CTA were the following: multidetector-array in a helical mode, 120 kV(peak), 150–300 mAs, section thickness = 1.25 mm before 2006 and 0.63 mm thereafter, pitch = 0.9:1. Image-acquisition delay depended on the arrival time of a 20-mL contrast bolus test (range, 15–20 seconds). Acquisition was then performed after intravenous administration of 50 mL of iohexol (300 mg/mL of iodine, Accupaque; GE Healthcare) at a rate of 5 mL per second with a power injector (Stellant D CT Injection System; Medrad, Indianola, Pennsylvania) in the arterial phase. Coverage extended from the origin of the aortic arch to the top of the corpus callosum. Delayed phase images were obtained on the brain only.

Image Interpretation

Only CTA images were used for this study. Raw CTA source images in the axial plane were analyzed for focal arterial occlusive

disease. Maximum intensity projections were then reconstructed in axial, sagittal, and coronal planes. Curvilinear reconstructions were obtained routinely.

A senior board-certified vascular neurologist (P. Michel) or neuroradiologists (R.A.M. or P. Maeder) with >10 years' experience analyzed the acute CTAs within 7 days after admission. In cases of discordance, images were reviewed by the vascular neurologist and at least 1 neuroradiologist to reach agreement. Inter-rater agreement was assessed on 100 consecutive patients in the data base by using κ statistics and comparing the CTA interpretations by 1 vascular neurologist (P. Michel) and 1 neuroradiologist (P.J.M.). Both independently assessed the presence or absence of extracranial and intracranial segmental occlusive disease in the proximal (carotid siphon, M1, basilar artery) and distal circulation in the ischemic territory.

Twenty-one arterial segments (counting left and right sides, listed below) were analyzed separately for each patient and graded as normal, stenotic, or occluded. Segments were the following: extracranial vertebral artery (V1–3 segments); intracranial vertebral artery (V4 segment); basilar artery; posterior cerebral artery, P1, P2, and P3 segments; extracranial internal carotid artery; intracranial carotid artery, noting whether T-occlusion was present or not; middle cerebral artery, M1, M2, M3 segments; and anterior cerebral artery, A1, A2, and A3 segments. Imaging data are continuously recorded in the ASTRAL data base.

The term “abnormal” was used for stenotic or occluded segments.

“Occlusion” was defined as the absence of contrast medium filling the examined arterial segment on initial acquisition.¹¹ For extracranial arteries, stenosis was defined by using the NASCET criteria: caliber reduction of $\geq 50\%$ for vertebral arteries and $\geq 70\%$ for carotid arteries.¹² For intracranial arteries, stenosis was defined by using the Warfarin-Aspirin Symptomatic Intracranial Disease method (ie, $\geq 50\%$ caliber reduction).¹³ “Tandem patterns” are defined as arterial occlusive disease affecting both the extra- and intracranial circulation in the same vascular axis. Abnormal segments on CTA were further categorized as symptomatic if the stenosis or occlusion was ipsilateral and proximal to the acute ischemic territory, or asymptomatic, if they were in the non-acute ischemic territory.

To evaluate the number of possible acute mechanical revascularization procedures in readily accessible large arteries, we subjected all occlusions in the extracranial and intracranial carotid arteries, V1–3, V4, basilar artery, P1, A1, M1, and M2 segments to a specific group analysis.

Data Processing and Statistical Analysis

Univariate analysis was performed to compare the characteristics of included and excluded patients by using the Wilcoxon 2-sample test for continuous variables and the χ^2 test for categorical variables. *P* values < .05 were considered significant. All data were processed by using STATA statistical software (Version 13.1, October 30 2013; StataCorp, College Station, Texas). Odds ratios were obtained by using an on-line calculator.¹⁴

ASTRAL was approved for scientific use by the institutional ethical commission, which did not require that individual informed consent be obtained.

RESULTS

Of 5022 patients with AIS symptoms who arrived at our institution during the observation period, 2209 patients were enrolled. Reasons for exclusion from ASTRAL were vascular diagnoses other than AIS ($n = 2370$). These and radiologic reasons for exclusion from the study ($n = 443$) are detailed in On-line Fig 1.

Baseline characteristics of the included ($n = 2209$) and excluded ($n = 443$) patients with AIS are described in Table 1. In

univariate comparison, patients with AIS excluded for radiologic reasons were older and more often women and tended to have more hypertension and atrial fibrillation and lower admission NIHSS scores. Stroke onset-to-CT and door-to-CT delays were longer, as expected in this group, because a main reason for study exclusion was a CTA performed after 24 hours of onset.

Cervicocerebral CTA analysis of the 2209 enrolled patients yielded 50,807 analyzable arterial segments.

Interrater agreement in the ischemic territory was almost perfect for intracranial proximal occlusive disease ($\kappa = 0.87$) and substantial for intracranial distal and extracranial occlusive disease ($\kappa = 0.61$ and 0.64 , respectively), similar to previously published data.⁸

One thousand two hundred twenty-six patients (55.5%) had any arterial occlusion or stenosis (ischemic and non-ischemic territories combined), while 983 patients (44.5%) did not show relevant occlusive disease (for details see Tables 2 and 3). One thousand seventy-five patients (48.7% of all patients) had such major abnormalities in the ischemic (ie, symptomatic) territory. Three hundred eight patients (13.9% of all patients) had stenosis or occlusion in territories not related to ischemia (ie, asymptomatic abnormalities) (see On-line Tables 1 and 2 for full details).

If one considered arterial segments, arterial occlusion or stenosis occurred in 2259 segments (4.5% of all segments) (for details, see Tables 2 and 3); 1851 segmental abnormalities (81.9% of all abnormal segments or 3.6% of all examined segments) were in the ischemic ter-

Table 1: Patient characteristics and univariate comparison with the patients excluded for radiologic reasons^a

	Study Population (N = 2209)		Excluded Patients (n = 443)		P Value
	No.	% or IQR	No.	% or IQR	
Female sex (%)	929	42.1	216	48.8	<.01
Age (yr) (IQR)	72	21	77	24	<.01
Risk factors					
Hypertension (%)	1268	66.9	318	71.8	.02
Heart valves (%)	61	3.2	11	2.5	.51
Coronary artery disease (%)	295	15.5	80	18.1	.20
Dyslipidemia (%)	1325	69.5	270	60.9	<.01
Diabetes (%)	331	17.4	82	18.5	.34
Atrial fibrillation (%)	480	25.2	141	31.8	<.01
Low ejection fraction (%)	91	4.7	24	5.4	.60
Smoking (%)	807	42.3	160	36.1	.06
Stroke mechanism					
Atherosclerosis (%)	304	13.8	99	22.3	.05
Undetermined (%)	553	25	92	20.8	.06
Cardiac (%)	641	29	145	32.7	.12
Lacunar/microangiopathic (%)	269	12.2	62	14.0	.19
Dissections (%)	107	4.8	14	3.2	.07
PFO/other determined/rare (%)	159	7.2	40	9.0	.07
Multiple/coexisting (%)	118	5.3	21	4.7	.48
NIHSS admission (IQR)	7	12	5	9	<.01
Onset-to-CT delay (IQR) (min)	275	565	420	667	<.01
Door-to-CT delay (IQR) (min)	183	469	380	771	<.01

Note:—IQR indicates interquartile range; PFO, patent foramen ovale.

^a Values are expressed as medians and IQR for continuous variables or absolute counts and percentage for categorical variables unless otherwise stated.

Table 2: Distribution of arterial occlusive disease in numbers and rates, given per patient (N = 2209)^a

Circulation	Ischemic Territory		Subtotal for Ischemic Territory		All Abnormalities (Related to Ischemia or Not)		No Relevant Abnormalities			
	Occlusion	Stenosis	Occlusion and/or Stenosis	Occlusion and/or Stenosis	Occlusion and/or Stenosis	Occlusion and/or Stenosis	No Relevant Abnormalities			
Extracranial abnormalities per segment										
Extracranial ICA or CCA	206	9.3%	165	7.5%	369	16.7%	437	19.8%	1772	80.2%
Extracranial vertebral	51	2.3%	26	1.2%	75	3.4%	139	6.3%	2070	93.7%
Subtotal extracranial abnormalities	257	11.6%	190	8.6%	442	20.0%	543	24.6%	1666	75.4%
Isolated extracranial abnormalities	35	1.6%	103	4.7%	136	6.2%	231	10.5%	1978	89.5%
Intracranial abnormalities per patient										
Anterior intracranial	429	19.4%	88	4.0%	508	23.0%	534	24.2%	1675	75.8%
Posterior intracranial	96	4.4%	51	2.3%	135	6.1%	174	7.9%	2035	92.1%
Subtotal intracranial abnormalities	523	23.7%	135	6.1%	633	28.7%	683	30.9%	1526	69.1%
Isolated intracranial abnormalities	519	23.5%	133	6.0%	627	28.4%	669	30.3%	1526	69.1%
Total extra- and intracranial circulation per patient	780	35.3%	325	14.7%	1075	48.7%	1226	55.5%	983	44.5%

Note:—CCA indicates common carotid artery.

^a The totals and subtotals may be smaller than the sum of the columns because patients may have arterial occlusive disease simultaneously in different segments or on different levels.

Table 3: Distribution of occlusive disease for each arterial segment^a

Circulation	Ischemic territory		Subtotal Ischemic		All Abnormalities (Related to Ischemia or Not)		No Relevant Abnormalities			
					Occlusion or Stenosis	Occlusion or Stenosis				
Segments	Occlusion	Stenosis	Occlusion or Stenosis	Occlusion or Stenosis	Occlusion or Stenosis	Occlusion or Stenosis	Occlusion or Stenosis	Occlusion or Stenosis	Occlusion or Stenosis	
Extracranial abnormalities per segment in 2209 patients (<i>n</i> = 50,807 segments)										
Extracranial ICA or CCA	207	4.7%	167	3.8%	374	8.5%	520	11.8%	3898	88.2%
VI–3	59	1.3%	29	0.7%	88	2.0%	160	3.6%	4258	96.4%
Subtotal extracranial	266	3.0%	196	2.2%	462	5.2%	680	7.7%	8156	92.3%
Intracranial abnormalities per segment										
Carotid siphon without T	85	1.9%	47	1.1%	132	3.0%	172	3.9%	4246	96.1%
Carotid siphon with T	124	2.8%	—	0.0%	124	2.8%	125	2.8%	4293	97.2%
MCA: M1	405	9.2%	54	1.2%	457	10.3%	480	10.9%	3938	89.1%
MCA: M2–3 only	226	5.1%	42	1.0%	268	6.1%	279	6.3%	4139	93.7%
ACA: A1	104	2.4%	11	0.3%	115	2.6%	130	2.9%	4288	97.1%
ACA: A2–3 only	9	0.2%	3	0.1%	12	0.3%	14	0.3%	4404	99.7%
Subtotal anterior intracranial	953	3.6%	157	0.6%	1108	4.2%	1200	4.5%	25,308	95.5%
PCA: P1	41	0.9%	10	0.2%	51	1.2%	71	1.6%	4347	98.4%
PCA: P2–3 only	33	0.8%	13	0.3%	46	1.0%	64	1.5%	4354	98.6%
V4	73	1.7%	30	0.7%	103	2.3%	148	3.4%	4270	96.7%
BA	55	2.5%	26	1.2%	81	3.7%	96	4.4%	2113	95.7%
Subtotal posterior intracranial	202	1.3%	79	0.5%	281	1.8%	379	2.5%	15,084	97.6%
Subtotal intracranial	1155	2.8%	236	0.7%	1389	3.3%	1579	3.8%	40,392	96.2%
Subtotal anterior circulation	1160	3.8%	324	1.0%	1482	4.8%	1720	5.6%	29,206	94.4%
Subtotal posterior circulation	261	1.3%	108	0.5%	369	1.9%	539	2.7%	19,342	97.3%
Total extra- and intracranial abnormalities per segment	1421	2.8%	432	0.9%	1851	3.6%	2259	4.5%	48,548	95.5%

Note:—ACA indicates anterior cerebral artery; PCA, posterior cerebral artery; BA, basilar artery; CCA, common carotid artery.

^a For each arterial segment, numbers and rates are given. Subtotal and total rates are calculated by dividing by all segments in the subtotal/total. A single patient may have several pathologic arterial segments.

ritory (ie, symptomatic). Four hundred eight segmental abnormalities (18.1% of all abnormalities or 0.8% of all examined segments) were in the nonischemic territory (ie, asymptomatic) (see On-line Tables 1 and 2 for full details).

Occlusive disease was most commonly seen in the anterior circulation (76.1% of all abnormal segments). This was more often intracranial than extracranial (30.9% versus 24.6% of all patients).

The proximal MCA (24.7% of all symptomatic abnormalities) was most frequently affected by symptomatic occlusive disease, followed by the extracranial ICA (20.2%) and then the distal MCA (14.5%).

As seen in the tables, occlusion was more frequent than stenosis. Symptomatic tandem patterns (On-line Table 3) were predominantly observed in the anterior circulation (82.1% in 302 patients (28.1% of all patients with symptomatic abnormalities, 13.7% of all patients in the study)). A graphic representation of observed occlusive disease per segment (symptomatic and asymptomatic stenosis or occlusions) is available in Fig 1. A column plot representation of arterial occlusive disease according to localization and type (stenosis versus occlusion) as defined in the “Materials and Methods” section is available in On-line Fig 2. Of patients having a symptomatic intracranial abnormality, 40% had a coexisting extracranial abnormality (tandem pattern). Only 34 of the tandem lesions (10.1% of all tandem lesions) were asymptomatic.

In 743 (33%) of the patients with AIS imaged within 24 hours

of symptom onset, we found at least 1 symptomatic occlusion in a large, proximal artery and therefore readily accessible to endovascular treatment. These numbers increased to 640 (38.1%) of the 1679 patients imaged within 12 hours, 531 (40.7%) of 1304 imaged within 6 hours, and 480 (42.0%) of 1143 patients imaged within 4.5 hours. Of the patients arriving within 6 hours, the following segments were found occluded on CTA: extracranial ICA (*n* = 150, 11.5% of patients); V1–V3 (*n* = 31, 2.4% of patients); intracranial ICA (*n* = 34, 2.6% of patients); M1 (*n* = 193, 14.8% of patients); M2 (*n* = 114, 8.7% of patients); A1 (*n* = 32, 2.5% of patients); P1 (*n* = 23, 1.8% of patients); V4 (*n* = 11, 0.8% of patients); basilar artery (*n* = 22, 1.7% of patients). This is a total of 610 segments, found in 531 patients.

DISCUSSION

In the largest series to date of patients with AIS undergoing CTA within 24 hours from symptom onset, we found relevant arterial abnormalities in 55.5% of patients, most of which were observed in the ischemic territory. Regarding individual cervical and cerebral arterial segments, only 4.5% were abnormal, again affecting predominantly the ischemic territory. Arterial segments with the highest blood supply (anterior > posterior circulation, larger > smaller arteries) had the most occlusive disease.

Approximately half of the patients with AIS did not have any visible arterial abnormalities on CTA, increasing the chances of a better outcome¹⁵ and making endovascular treatment unnecessary. The fact that an overwhelming proportion of arterial seg-

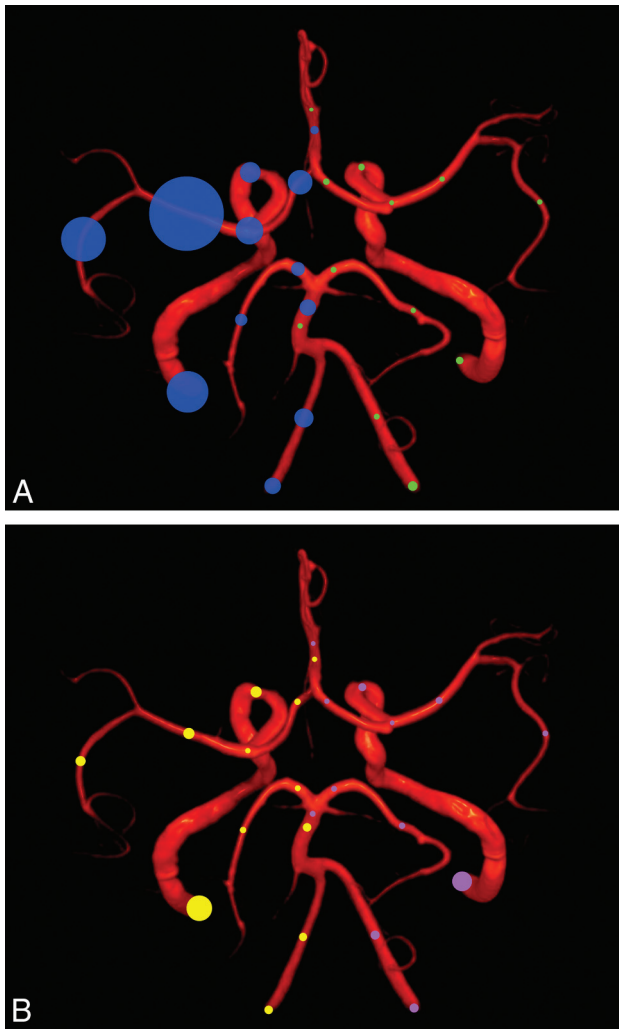


FIG 1. Graphic representation of observed occlusive disease per segment. The area of the circle is proportional to the observed rate. *A*, Rate of symptomatic (right patient side, blue circles) and asymptomatic arterial occlusions (left patient side, green circles). *B*, Rate of symptomatic (right patient side, yellow circles) and asymptomatic arterial stenoses (left patient side, pink circles).

ments are patent in AIS (95.5%) is a reminder that there is a great potential for collateral blood supply into the ischemic territory, potentially allowing access of thrombolytic or neuroprotective drugs to the acutely ischemic brain.

Symptomatic arterial abnormalities were more often found in the anterior circulation (76.1% of all abnormal segments, occurring in 81.6% of patients with symptomatic abnormalities), which is consistent with the proportion of blood flow being directed to this part of the cerebral circulation. In addition, there is significantly more arterial occlusive disease in patients with anterior-versus-posterior circulation stroke (see odds ratios in Table 4). This may be related to posterior circulation strokes being more often of microangiopathic origin,¹⁶ with less detectable arterial pathology on noninvasive imaging.

Patients more often had symptomatic arterial abnormalities in the intra- rather than the extracranial circulation (28.6% versus 20.0% of all patients). This may be because most emboli from the heart and proximal extracranial arteries are too small to occlude the cervical arteries and get blocked only in smaller, intracranial

Table 4: Localization of arterial occlusive disease in the ischemic territory^a

	Per Patient (Table 2)		Per Segment (Table 3)	
	OR	95% CI	OR	95% CI
Anterior vs posterior circulation strokes	6.7	5.6–7.9	2.8	2.5–3.1
Intracranial segments	4.6	3.7–5.6	2.5	2.2–2.8
Extracranial segments	5.8	4.5–7.4	4.6	3.7–5.9
Intracranial vs extracranial localization	1.6	1.4–1.8	0.6	0.6–0.8
Anterior circulation	1.5	1.3–1.7	0.5	0.4–0.5
Posterior circulation	1.8	1.4–2.4	0.9	0.7–1.2
Tandem pattern: anterior vs posterior circulation	5.0	3.7–6.7	–	–

^a Results are expressed as odds ratios plus 95% confidence intervals.

vessels. The finding that the proportion of abnormal arterial segments is lower intracranially (3.8% versus 7.7%, Table 3) is because the intracranial circulation is divided into subsegments. Our results, therefore, show that it is crucial to examine both the extracranial arteries and the circle of Willis in patients with AIS.

Not surprising, symptomatic abnormalities are usually occlusive, whereas asymptomatic abnormalities are typically stenotic, likely explained by a reduced-but-sufficient blood flow through the stenosis. We found a low overall rate (0.7%) of symptomatic intracranial stenosis in our cohort, likely consisting of a combination of atherosclerotic plaques and partially resorbed emboli. A higher rate of intracranial stenosis has been described in Asian patients with ischemic stroke.¹⁷

The 40% concurrent extracranial (tandem) pathology observed in patients with a symptomatic intracranial abnormality has practical implications because it may complicate endovascular access. This situation seems to be particularly frequent in the anterior circulation (odds ratio of 5.0 for anterior-versus-posterior tandem lesions in our population).

Rapid endovascular treatment by using predominantly stent retrievers has recently been shown to be more effective than IV thrombolysis alone in well-selected patients with proximal intracranial occlusions of the anterior circulation¹⁸ and is now considered the standard of care.^{19,20} This is because recanalization is one of the most important predictors of prognosis in AIS,^{21,22} and proximal occlusions insufficiently respond to IV thrombolysis in many cases.²³ Endovascular stroke trials have mostly excluded patients with posterior circulation strokes. Although large posterior circulation occlusions are also likely to benefit from endovascular treatment, this benefit has to first be proved by a randomized controlled trial such as the Basilar Artery International Cooperation Study trial.²⁴

The proportion of 40.7% of such patients in this tertiary care setting imaged within 6 hours provides an estimate of the number of patients who could benefit from such interventions. When adding clinical and other radiologic criteria as well as contraindications, this number may be reduced by half in the real world, however.²⁵ Still, improved prehospital identification and transport of patients with probable proximal intracranial occlusions²⁶ are likely to increase the number of endovascularly treatable patients in comprehensive stroke centers.²⁷

The spontaneous recanalization rate of proximal occlusions

between 4.5 and 24 hours from symptom onset is approximately 9% based on the aforementioned proportions of patients with such occlusions. In contrast, early digital subtraction studies reported an estimated 17% spontaneous recanalization at 6–8 hours from stroke onset.²⁸

Limitations are the retrospective, uncontrolled nature of the study with data from a single-center registry, which may not have a population representative of other settings for acute stroke care. We excluded a certain number of patients because acute CTA was not performed, mainly due to contrast contraindications. Images of head and neck vessels were analyzed in the arterial phase only, possibly overestimating the degree and extent of proximal occlusive disease. Also, the results are based on CTA, which is a reliable method for assessment of arterial pathology in AIS^{4,29,30} but may not be generalizable to other angiographic methods. We did not analyze associations among arterial imaging, clinical variables, and functional outcome because this was the purpose of recent publications.^{26,31}

On the other hand, the available data may represent the best possible approximation of a real-world AIS population, given that some patients will always be unable to undergo acute angiographic evaluations.

CONCLUSIONS

This study gives a comprehensive picture of the frequency and distribution of relevant arterial pathology on CTA obtained within 24 hours of symptom onset. Approximately half of patients had relevant arterial pathology in the ischemic territory, mostly in the intracranial anterior circulation; a significant number also had tandem pathology. The 40% of patients with AIS having proximal intracranial arterial occlusions in the first 6 hours give an estimate of the eligibility for acute endovascular therapy.

Disclosures: David Rotzinger—UNRELATED: Employment: Lausanne University Hospital (Centre Hospitalier Universitaire Vaudois), Comments: my employer since 2011. Patrik Michel—RELATED: Grant: Swiss Heart Foundation*; UNRELATED: Board Membership: Boehringer-Ingelheim, Bayer Healthcare, Pfizer*; Consultancy: Pierre-Fabre, AstraZeneca, Amgen*; Payment for Lectures Including Service on Speakers Bureaus: Boehringer-Ingelheim, Bayer Healthcare, Medtronic-Covidien, Stryker*; Travel/Accommodations/Meeting Expenses Unrelated to Activities Listed: Boehringer-Ingelheim, Bayer Healthcare.**Money paid to the institution.

REFERENCES

1. Michel P, Odier C, Rutgers M, et al. **The Acute STroke Registry and Analysis of Lausanne (ASTRAL): design and baseline analysis of an ischemic stroke registry including acute multimodal imaging.** *Stroke* 2010;41:2491–98 CrossRef Medline
2. González RG. **Current state of acute stroke imaging.** *Stroke* 2013;44:3260–64 CrossRef Medline
3. Schramm P, Schellinger PD, Klotz E, et al. **Comparison of perfusion computed tomography and computed tomography angiography source images with perfusion-weighted imaging and diffusion-weighted imaging in patients with acute stroke of less than 6 hours' duration.** *Stroke* 2004;35:1652–58 CrossRef Medline
4. Bash S, Villablanca JP, Jahan R, et al. **Intracranial vascular stenosis and occlusive disease: evaluation with CT angiography, MR angiography, and digital subtraction angiography.** *AJNR Am J Neuroradiol* 2005;26:1012–21 Medline
5. Josephson SA, Bryant SO, Mak HK, et al. **Evaluation of carotid stenosis using CT angiography in the initial evaluation of stroke and TIA.** *Neurology* 2004;63:457–60 CrossRef Medline
6. Obach V, Oleaga L, Urra X, et al. **Multimodal CT-assisted thrombolysis in patients with acute stroke: a cohort study.** *Stroke* 2011;42:1129–31 CrossRef Medline
7. Lansberg MG, Thijs VN, Bammer R, et al. **The MRA-DWI mismatch identifies patients with stroke who are likely to benefit from reperfusion.** *Stroke* 2008;39:2491–96 CrossRef Medline
8. Knauth M, von Kummer R, Jansen O, et al. **Potential of CT angiography in acute ischemic stroke.** *AJNR Am J Neuroradiol* 1997;18:1001–10 Medline
9. Deipolyi AR, Hamberg LM, González RG, et al. **Diagnostic yield of emergency department arch-to-vertex CT angiography in patients with suspected acute stroke.** *AJNR Am J Neuroradiol* 2015;36:265–68 CrossRef Medline
10. Adams HP Jr, Bendixen BH, Kappelle LJ, et al. **Classification of subtype of acute ischemic stroke.** *Stroke* 1993;23:35–41 Medline
11. Vanacker P, Lambrou D, Eskandari A, et al. **Improving prediction of recanalization in acute large-vessel occlusive stroke.** *J Thromb Haemost* 2014;12:814–21 CrossRef Medline
12. North American Symptomatic Carotid Endarterectomy Trial Collaborators. **Beneficial effect of carotid endarterectomy in symptomatic patients with high-grade carotid stenosis.** *N Engl J Med* 1991;325:445–53 CrossRef Medline
13. Chimowitz MI, Lynn MJ, Howlett-Smith H, et al; Warfarin-Aspirin Symptomatic Intracranial Disease Trial Investigators. **Comparison of warfarin and aspirin for symptomatic intracranial arterial stenosis.** *N Engl J Med* 2005;352:1305–16 CrossRef Medline
14. Calculator for confidence intervals of odds ratio in an unmatched case control study. <http://www.hutchon.net/confidor.htm>. Accessed June 18, 2013
15. Medlin F, Amiguet M, Vanacker P, et al. **Influence of arterial occlusion on outcome after intravenous thrombolysis for acute ischemic stroke.** *Stroke* 2015;46:126–31 CrossRef Medline
16. Libman R, Kwiatkowski T, Hansen MD, et al. **Differences between anterior and posterior circulation stroke in TOAST.** *Cerebrovasc Dis* 2001;11:311–16 CrossRef Medline
17. Wang Y, Zhao X, Liu L, et al; CICAS Study Group. **Prevalence and outcomes of symptomatic intracranial large artery stenoses and occlusions in China: the Chinese Intracranial Atherosclerosis (CICAS) study.** *Stroke* 2014;45:663–69 CrossRef Medline
18. Goyal M, Menon BK, Van Zwam WH, et al; HERMES collaborators. **Endovascular thrombectomy after large-vessel ischaemic stroke: a meta-analysis of individual patient data from five randomised trials.** *Lancet* 2016;387:1723–31 CrossRef Medline
19. Fiehler J, Cognard C, Gallitelli M, et al. **European recommendations on organisation of interventional care in acute stroke (EROICAS).** *Eur Stroke J* 2016;11:155–70 CrossRef Medline
20. Powers WJ, Derdeyn CP, Biller J, et al; American Heart Association Stroke Council. **2015 American Heart Association/American Stroke Association Focused Update of the 2013 Guidelines for the Early Management of Patients with Acute Ischemic Stroke Regarding Endovascular Treatment: A Guideline for Healthcare Professionals from the American Heart Association/American Stroke Association.** *Stroke* 2015;46:3020–35 CrossRef Medline
21. Vanacker P, Lambrou D, Eskandari A, et al. **Improving the prediction of spontaneous and post-thrombolytic recanalization in ischemic stroke patients.** *J Stroke Cerebrovasc Dis* 2015;24:1781–86 CrossRef Medline
22. Bill O, Zufferey P, Faouzi M, et al. **Severe stroke: patient profile and predictors of favorable outcome.** *J Thromb Haemost* 2013;11:92–99 CrossRef Medline
23. Vanacker P, Heldner MR, Seiffge D, et al. **ASTRAL-R score predicts non-recanalisation after intravenous thrombolysis in acute ischaemic stroke.** *Thromb Haemost* 2015;113:1121–26 CrossRef Medline
24. van der Hoeven EJ, Schonewille WJ, Vos JA, et al; BASICS Study Group. **The Basilar Artery International Cooperation Study (BASICS): study protocol for a randomised controlled trial.** *Trials* 2013;14:200 CrossRef Medline
25. Vanacker P, Lambrou D, Eskandari A, et al. **Eligibility and predictors**

- for acute revascularization procedures in a stroke center. *Stroke* 2016;47:1844–49 CrossRef Medline
26. Vanacker P, Heldner M, Amiguet M, et al. **Prediction of large vessel occlusions in acute stroke: National Institute of Health Stroke Scale is hard to beat.** *Crit Care Med* 2016;44:336–43 CrossRef Medline
27. Michel P. **Prehospital scales for large vessel occlusion: closing in on a moving target.** *Stroke* 2017 Jan 13. [Epub ahead of print] Medline
28. Kassem-Moussa H, Graffagnino C. **Nonocclusion and spontaneous recanalization rates in acute ischemic stroke: a review of cerebral angiography studies.** *Arch Neurol* 2002;59:1870–73 CrossRef Medline
29. Schramm P, Schellinger PD, Fiebach JB, et al. **Comparison of CT and CT angiography source images with diffusion-weighted imaging in patients with acute stroke within 6 hours after onset.** *Stroke* 2002;33:2426–32 CrossRef Medline
30. Nguyen-Huynh MN, Wintermark M, English J, et al. **How accurate is CT angiography in evaluating intracranial atherosclerotic disease?** *Stroke* 2008;39:1184–88 CrossRef Medline
31. Ntaios G, Papavasileiou V, Faouzi M, et al. **Acute imaging does not improve ASTRAL score's accuracy despite having a prognostic value.** *Int J Stroke* 2014;9:926–31 CrossRef Medline