

Are your **MRI contrast agents** cost-effective?

Learn more about generic **Gadolinium-Based Contrast Agents**.



**AJNR**

## **Distal Balloon Angioplasty of Cerebral Vasospasm Decreases the Risk of Delayed Cerebral Infarction**

M.-A. Labeyrie, S. Gaugain, G. Boulouis, A. Zetchi, J. Bami, J.-P. Saint-Maurice, V. Civelli, S. Froelich and E. Houdart

This information is current as of April 18, 2024.

*AJNR Am J Neuroradiol* published online 18 July 2019  
<http://www.ajnr.org/content/early/2019/07/18/ajnr.A6124>

# Distal Balloon Angioplasty of Cerebral Vasospasm Decreases the Risk of Delayed Cerebral Infarction

 M.-A. Labeyrie,  S. Gaugain,  G. Boulouis,  A. Zetchi,  J. Brami,  J.-P. Saint-Maurice,  V. Civelli,  S. Froelich, and  E. Houdart



## ABSTRACT

**BACKGROUND AND PURPOSE:** Conventional angioplasty of cerebral vasospasm combines proximal balloon angioplasty (up to the first segment of cerebral arteries) with chemical angioplasty for distal arteries. Distal balloon angioplasty (up to the second segment of cerebral arteries) has been used in our center instead of chemical angioplasty since January 2015. We aimed to assess the effect of this new approach in patients with aneurysmal SAH.

**MATERIALS AND METHODS:** The occurrence, date, territory, and cause of any cerebral infarction were retrospectively determined and correlated to angioplasty procedures. Delayed cerebral infarction, new angioplasty in the territory of a previous angioplasty, angioplasty complications, 1-month mortality, and 6- to 12-month modified Rankin Scale  $\leq 2$  were compared between 2 periods (before-versus-after January 2015, from 2012 to 2017) with adjustment for age, sex, World Federation of Neurosurgical Societies score, and the modified Fisher grade.

**RESULTS:** Three-hundred-ninety-two patients were analyzed (160 before versus 232 after January 2015). Distal balloon angioplasty was associated with the following: higher rates of angioplasty (43% versus 27%,  $P < .001$ ) and intravenous milrinone (31% versus 9%,  $P < .001$ ); lower rates of postangioplasty delayed cerebral infarction (2.2% versus 7.5%,  $P = .01$ ) and new angioplasty (8% versus 19%,  $P = .003$ ) independent of the rate of patients treated by angioplasty and milrinone; and the same rates of stroke related to angioplasty (3.6% versus 3.1%,  $P = .78$ ), delayed cerebral infarction (7.7% versus 12.5%,  $P = .12$ ), mortality (10% versus 11%,  $P = .81$ ), and favorable outcome (79% versus 73%,  $P = .21$ ).

**CONCLUSIONS:** Our study suggests that distal balloon angioplasty is safe and decreases the risk of delayed cerebral infarction and the recurrence of vasospasm compared with conventional angioplasty. It fails to show a clinical benefit possibly because of confounding changes in adjuvant therapies of vasospasm during the study period.

**ABBREVIATIONS:** aSAH = aneurysmal subarachnoid hemorrhage; DCIn = delayed cerebral infarction; WFNS = World Federation of Neurosurgical Societies

Angioplasty of cerebral vasospasm is broadly used in acute aneurysmal SAH (aSAH). Two main approaches to angioplasty are used alone or combined: the balloon angioplasty performed by most physicians up to the end of the first segment of cerebral arteries (ie, in the proximal and largest arterial segments)<sup>1-3</sup> and intra-arterial vasodilator infusion therapy (chemical angioplasty).<sup>4,5</sup> Their efficacy to treat the arterial narrowing

has been demonstrated, but their benefit to prevent delayed cerebral infarction (DCIn) remains controversial.<sup>6,7</sup> The feasibility of balloon angioplasty up to the end of the second segment of the cerebral arteries (distal balloon angioplasty) using an extracomppliant balloon has been recently reported.<sup>8</sup> On the basis of this report, our experience of poor efficacy of chemical angioplasty, and our preliminary experience with distal balloon angioplasty, we decided to replace chemical angioplasty with distal balloon angioplasty for distal vasospasm. The aim of this study was to compare historically the safety and efficacy of this new approach with the conventional approach using proximal balloon angioplasty and chemical angioplasty.

## MATERIALS AND METHODS


### Patients

Consecutive patients hospitalized in our center (Lariboisière Hospital, France) between January 2012 and December 2017 within 15 days of aSAH with a modified Fisher grade of  $\geq 1$  were in-

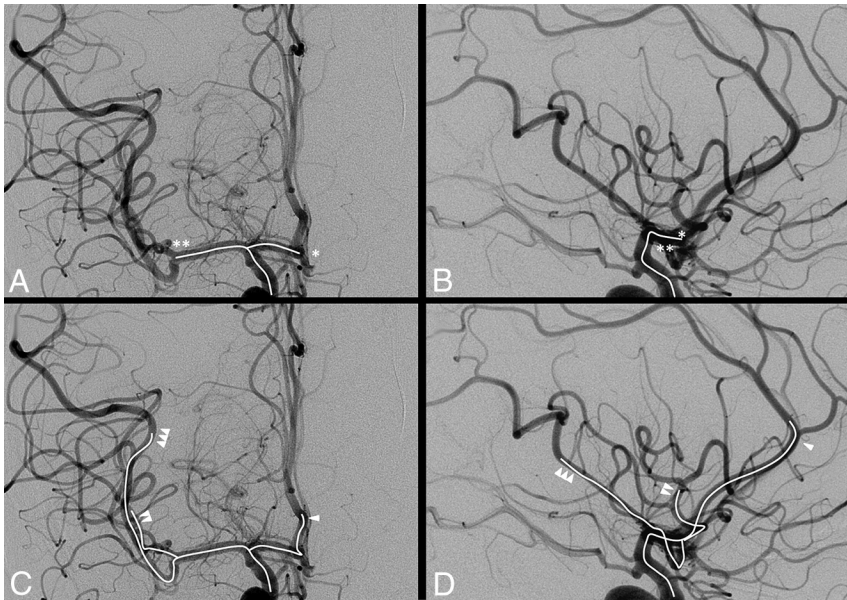
Received February 6, 2019; accepted after revision June 5.

From the Departments of Interventional Neuroradiology (M.-A.L., A.Z., J.B., J.-P.S.-M., V.C., E.H.) and Neurosurgery (S.F.) and Emergency Care Unit (S.G.), Hôpital Lariboisière, Paris, France; EA 7334 REMES (M.-A.L., E.H.), L'Université Paris Diderot, Paris, France; and Department of Radiology (G.B.), Centre Hospitalier Sainte-Anne, Paris, France.

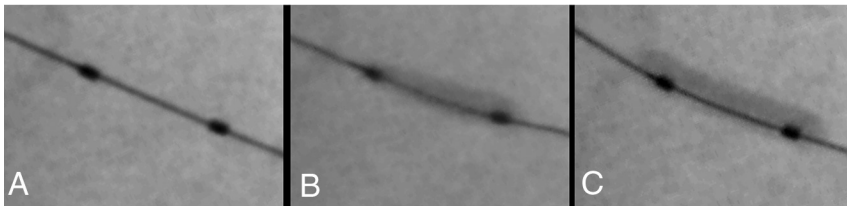
Please address correspondence to Marc-Antoine Labeyrie, MD, Service de Neuro-radiologie Interventionnelle, Hôpital Lariboisière, 2 rue Ambroise Paré, 75010 Paris, France; e-mail: marc-antoine.labeyrie@aphp.fr

 Indicates article with supplemental on-line appendix and table.

<http://dx.doi.org/10.3174/ajnr.A6124>



**FIG 1.** Anatomic definition of distal-versus-proximal balloon angioplasty. Frontal (A and C) and lateral (B and D) angiograms of the right internal carotid artery before cerebral vasospasm. Arterial segments treated using proximal balloon angioplasty are indicated in A and B (*intra-arterial white line*). They include the terminal internal carotid artery and the main segments of cerebral arteries up to the end of their first segment (*single star* for A1, *double star* for M1). Arterial segments treated using distal balloon angioplasty are shown in C and D (*intra-arterial white line*). They include the terminal internal carotid artery and the main segments of the cerebral arteries up to the end of their second segments (*single arrowhead* for pericallosal segment, *double arrowhead* for the anterior M2 branch, and *triple arrowhead* for the posterior M2 branch).



**FIG 2.** Distal balloon angioplasty in a 1.5-mm large M2 segment using an extracompliant 4-mm-large and 7-mm-long remodeling balloon. After we navigated in the distal M2 with a 0.010-inch guidewire, the balloon was positioned (A) and inflated progressively (B and C). The balloon has first a fusiform aspect (B) and then a tubular aspect and elongates (C) when it reaches the maximal diameter of the vessel. The balloon was immediately deflated. This maneuver was repeated within the entire segment from the proximal-to-distal M2.

cluded, except patients who died within the first 4 days after aSAH onset. All patients were hospitalized in an intensive care unit. Aneurysms were treated by embolization or clipping within 24 hours of admission. Acute hydrocephalus, neuroprotective measures, and primary prevention with oral nimodipine and detection of delayed cerebral ischemia were managed according to current guidelines.<sup>9</sup> Clinical and imaging data were reviewed by consensus from 2 neuroradiologists, including 1 who was independent of the procedures. The mRS was retrospectively determined within 6–12 months after aSAH by an independent clinical research associate with mRS certification and blinded to the patient's care and the historical design of the study. Patients or their relatives were informed and provided their consent for all clinical care. The study was approved by our institution ethics committee.

### Intensive Therapies of Vasospasm

Balloon angioplasty was performed using an extracompliant remodeling balloon, HyperForm 4–7 on an 0.010-inch Expedition

microwire (ev3, Irvine, California), or Scepter XC 412 (MicroVention, Tustin, California) on a 0.014-inch Transend microwire (Stryker, Kalamazoo, Michigan), inflated through a 3.5-mL syringe with a dilution of 50% Omnipaque (iohexol 300 mg I/mL; GE Healthcare, Piscataway, New Jersey). The anatomic definition of distal-versus-proximal balloon angioplasty is shown in Fig 1.

We performed balloon angioplasty using previously reported technique.<sup>8</sup> A test inflation of the balloon was performed in the cervical artery to ensure that it was plainly visible. The balloon was inflated to the supposed normal diameter of the artery and until the lateral border of the balloon became parallel and the balloon elongated (Fig 2). Angulation and the diameter of the arterial segments were the most important safety variables considered before balloon angioplasty. Proximal balloon angioplasty was performed for arteries with a diameter  $\geq 2.5$  mm and located proximal to the first angulation of the cerebral arteries (up to the end of the first segments) (Fig 1A, -B). Distal balloon angioplasty was performed for arteries with a diameter of  $\geq 1.5$  mm and located proximal to the second angulation of the cerebral arteries (up to the end of the second segment), also including the pericallosal segment of the anterior cerebral artery or up to the end of the second segment of the 2 (or rarely 3) major division branches of the middle cerebral artery (Fig 1C, -D). Hypoplastic segments were excluded on the basis of prevasospasm vascular imaging.

Small anterior temporal branches from the middle cerebral arteries or anterior frontal branches from the anterior cerebral arteries were usually not dilated because of their small diameter and their excessive angulation. The posterior cerebral arteries were treated in a few selected cases and only proximally because DCIs in this territory were infrequent in our practice. Segments with obvious collateral supply through the circle of Willis were usually not treated. The parent vessel of an aneurysm was treated when necessary (except around a recent surgical clip) by taking care that the balloon did not bulge inside the aneurysm. Balloon angioplasty around a surgical clip was usually not performed because aneurysmal ruptures have been described during balloon angioplasty or navigation despite the clip. When a severe stenosis persisted after a first dilation, a second dilation was usually performed by taking care that the balloon did not overexpand on either side of the stenosis (giving a “dog bone” appearance).

Chemical angioplasty consisted of single or, when necessary,

repeat daily intra-arterial infusions for 30 minutes of 3 mg of nimodipine + 8 mg of milrinone + 40 mL of physiologic serum, or 1 single continuous infusion for 3 days of 4 mg/h of milrinone. Before January 2015, chemical angioplasty was performed for vasospasm of distal arterial segments when balloon angioplasty was not considered feasible. After January 2015, chemical angioplasty was replaced by distal balloon angioplasty.

All angioplasty procedures were performed with the patient under general anesthesia by keeping a mean arterial pressure of  $\geq 90$  mm Hg and normocapnia. Intravenous heparin (35–70 IU/kg) was administered before angioplasty. Since January 2013, continuous intravenous infusion of a high dose of intravenous milrinone (1.5mcg/kg/min, then adapted to clinical tolerance for at least 5 days) has been systematically considered after angioplasty.<sup>10</sup> It was maintained when possible until the 14th day, and the patient was weaned as indicated.

### **Indications for Intensive Therapies for Vasospasm**

Intensive therapies were considered in patients with a high suspicion or high risk of delayed cerebral ischemia. A high suspicion of delayed cerebral ischemia was defined by the following: 1) a vasospasm of  $\geq 50\%$  on DSA, especially when it was associated with a delayed enhancement of distal cortical arteries; and 2) a decrease in the level of consciousness or deficit or cerebral infarction occurring between the fourth day and the 21st day unrelated to seizure, severe intracranial hypertension, hydrocephaly, hyponatremia, aneurysm occlusion complications, or severe sepsis with hypotension. In unconscious patients, a high risk of delayed cerebral ischemia was considered using only DSA criteria. The non-invasive screening for vasospasm of  $\geq 50\%$  is detailed in the On-line Appendix. An induced hypertension was begun in patients with a high suspicion or a high risk of delayed cerebral ischemia. Angioplasty was then considered consensually between the interventional neuroradiologists and the intensive care physicians. It was performed only for arterial segments with vasospasms of  $\geq 50\%$ . It was contraindicated when a cerebral infarction extended to the major part of the territory because of the risk of reperfusion injury.

### **Safety of Angioplasty**

Arterial embolism, dissection, perforation, and vasospasm worsening were retrospectively reviewed on postangioplasty DSA. Dissection was distinguished from embolism using previously reported criteria.<sup>11</sup> Vasospasm worsening was defined as worsening of arterial narrowing occurring after catheterization or balloon angioplasty, not related to embolism or dissection, which resolves spontaneously in most cases or after further angioplasty. Reperfusion syndromes after angioplasty including severe intracranial hypertension requiring a hypertonic solution and symptomatic intracerebral hematoma were also recorded. Chronic aneurysm formation or occlusions of the arteries treated with angioplasty were assessed on vascular imaging follow-up at 3–6 months.

### **Efficacy of Angioplasty**

The efficacy of angioplasty was first determined by the rate of patients with DCIn occurring in the territory of a previous angioplasty (postangioplasty DCIn). The determination of DCIn is de-

tailed in the On-line Appendix. To summarize, DCIn was defined as any cerebral infarction occurring within 3–21 days of presentation, not related to an iatrogenic infarction or early low-flow infarction.<sup>12</sup> Only DCIn occurring after aneurysm treatment (in-hospital DCIn) was taken into account in the current study. The time and arterial territory of the DCIn were retrospectively determined using all available coregistered MR imaging and CT and clinical data. Then, the time and arterial territory of DCIn was compared with the timing and the territory of each angioplasty to determine whether the DCIn occurred or extended into the territory of a previous angioplasty (postangioplasty DCIn). DCIn and angioplasty were blinded. We also analyzed the occurrence of DCIn in a territory without angioplasty (ie, occurring in the parenchyma of nontreated vessels and including patients without any angioplasty or with angioplasty in another territory) and whether any new angioplasty was performed in the same territory of a previous angioplasty (in a different session).

### **Statistical Analysis**

Continuous variables were described as medians and interquartile ranges and compared using the nonparametric Kruskal-Wallis test. Categorical variables were compared using the  $\chi^2$  or Fisher exact test (unilateral test) as appropriate (SPSS 19; IBM, Armonk, New York). A *P* value  $\leq .05$  was considered significant. Baseline characteristics, intensive therapies of cerebral vasospasm, and outcome were univariately compared in historical analysis between the 2 periods (before-versus-after January 2015). DCIn, new angioplasty, 1-month death, and 6- to 12-month favorable outcome (mRS  $\leq 2$ ) were also compared between the 2 periods after adjustment for age, sex, and World Federation of Neurosurgical Societies (WFNS) score  $\geq IV$  and a modified Fisher grade  $\geq 3$  using binary logistic regression. The main analysis included all patients with aSAH. Then, a sensitivity analysis was performed by including only patients treated with angioplasty and patients who did not receive intravenous milrinone or by comparing the angioplasty strategy used for each arterial territory rather than at the patient level.

## **RESULTS**

### **Population**

Four-hundred-eighteen consecutive patients were treated for acute aSAH in our center during the study period. We excluded 26 patients who died from early brain injury and before any angioplasty. A total of 392 patients were analyzed in the current study, including 232 patients treated after January 2015 (distal balloon angioplasty period) and 160 patients before that date (historical control). Clinical and imaging data were available for all patients. Follow-up MR imaging was available for 90% of them. Interobserver agreement for DCIn determination was 0.903. The baseline characteristics of the population are reported in Table 1.

### **Patients Treated by Distal Balloon Angioplasty**

The intensive therapies used to treat cerebral vasospasm are detailed in Table 2. We observed a higher rate of patients treated by such therapies after January 2015 (*P*  $\geq .001$ ). A total of 145 patients were treated by angioplasty including 109/145 (75%) by distal angioplasty in at least 1 arterial territory.



**Table 1: Baseline characteristics of patients with aSAH**

	Total (N = 392)	Period 1 (n = 160) <sup>a</sup>	Period 2 (n = 232) <sup>a</sup>	P Value
Age (range) (yr)	52 (44–61)	52 (44–62)	52 (46–61)	.9
Female (No.) (%)	254 (65%)	104 (65%)	150 (65%)	.5
Tobacco (No.) (%)	188 (48%)	75 (47%)	113 (49%)	.4
Chronic high blood pressure (No.) (%)	168 (43%)	76 (47%)	92 (40%)	.1
Dyslipidemia (No.) (%)	84 (21%)	36 (22%)	48 (21%)	.6
Diabetes mellitus (No.) (%)	19 (5%)	9 (6%)	10 (4%)	.3
Modified Fisher grade				
1, 2 (No.) (%)	73 (19%)	34 (21%)	39 (17%)	.3
3 (No.) (%)	103 (26%)	37 (23%)	66 (28%)	.2
4 (No.) (%)	216 (55%)	89 (56%)	127 (55%)	.8
WFNS				
I, II (No.) (%)	270 (69%)	105 (65%)	165 (71%)	.2
III (No.) (%)	22 (6%)	11 (7%)	13 (6%)	.6
IV (No.) (%)	56 (14%)	22 (14%)	32 (14%)	1
V (No.) (%)	44 (11%)	22 (14%)	22 (9%)	.2

<sup>a</sup> Period 1/period 2 (before/after January 2015) means chemical/balloon angioplasty as a first-line treatment of distal vasospasm.

**Table 2: Intensive therapies of vasospasm in patients with aSAH**

	Total (N = 392)	Period 1 (n = 160) <sup>a</sup>	Period 2 (n = 232) <sup>a</sup>	P Value
Intensive treatment of vasospasm (No.) (%)	155 (40%)	47 (29%)	108 (46%)	<.001
Angioplasty (No.) (%)	145 (37%)	44 (27%)	101 (43%)	.001
Distal angioplasty (No.) (%) <sup>b</sup>	109 (28%)	35 (22%)	74 (32%)	.029
Distal balloon angioplasty (No.) (%) <sup>c</sup>	87 (22%)	13 (8%)	74 (32%)	<.001
Proximal balloon angioplasty (No.) (%) <sup>d</sup>	91 (23%)	26 (16%)	65 (28%)	.004
Chemical angioplasty (No.) (%) <sup>d</sup>	36 (9%)	31 (19%)	5 (2%)	<.001
Intravenous milrinone (No.) (%)	86 (22%)	15 (9%)	71 (31%)	<.001

<sup>a</sup> Period 1/period 2 (see Table 1).

<sup>b</sup> Distal angioplasty means distal balloon angioplasty or chemical angioplasty.

<sup>c</sup> Distal balloon angioplasty was performed alone.

<sup>d</sup> Chemical and proximal balloon angioplasties were performed alone or combined.

Distal balloon angioplasty was attempted in 187 arterial segments (90% of them in patients treated after January 2015). Catheterization failed in 21/187 (11%) because of an excess angulation between the first and second segments of cerebral arteries. For these segments or for those without distal vasospasm, only proximal balloon angioplasty was performed. Distal balloon angioplasty was performed in 166 arterial segments: M2 = 92, A2 = 69, posterior communicating artery P1 or P2 = 5. An example of distal balloon angioplasty is shown in Fig 3.

### Safety of Distal Balloon Angioplasty

Complications of angioplasty are detailed in the On-line Table. Cerebral infarction related to embolism or arterial dissection or vasospasm worsening was observed in 5/87 (6%) patients after distal balloon angioplasty. This rate was similar after other angioplasty approaches ( $P = .75$ ). Symptomatic intracranial hemorrhages were observed in 3/87 (3.4%) after distal balloon angioplasty. All had a large infarction on imaging before the procedure. This rate was similar to that in other approaches ( $P = .32$ ). No malignant edema or arterial perforation was observed after distal balloon angioplasty. The historical comparison of the rate of complications after angioplasty is reported in Table 3. Whereas more patients had angioplasty in the second period, the rates of cerebral infarction or symptomatic intracranial hemorrhage related to angioplasty were similar between the 2 periods ( $P \geq .64$ ).

### Efficacy of Distal Balloon Angioplasty

Angioplasty efficacy and outcome are reported in Table 3. After adjustment for age, sex, and WFNS score  $\geq$  IV and a modified Fisher grade of  $\geq$ 3, the second period was associated with a lower rate of postangioplasty DCIn (OR= 0.26; 95% CI, .09–0.77;  $P = .015$ ) and new angioplasty (OR= 0.39; 95% CI, 0.21–0.72;  $P = .003$ ), without any significant association with DCIn ( $P = .12$ ), 1-month mortality ( $P = .81$ ), and 6- to 12-month favorable outcome ( $P = .21$ ).

After adjustment with intravenous milrinone, the second period remained associated with a lower rate of postangioplasty DCIn and new angioplasty and became significantly associated with a lower rate of DCIn ( $P \leq .001$ ).

By including only patients treated by angioplasty, the second period remained associated with a lower rate of postangioplasty DCIn and new angioplasty and became significantly associated with DCIn (OR= 0.25; 95% CI, 0.10–0.59;  $P = .002$ ) and 6- to 12-month favorable outcome (OR= 2.5; 95% CI, 1.1–5.7;  $P = .026$ ). Of note, in this population,

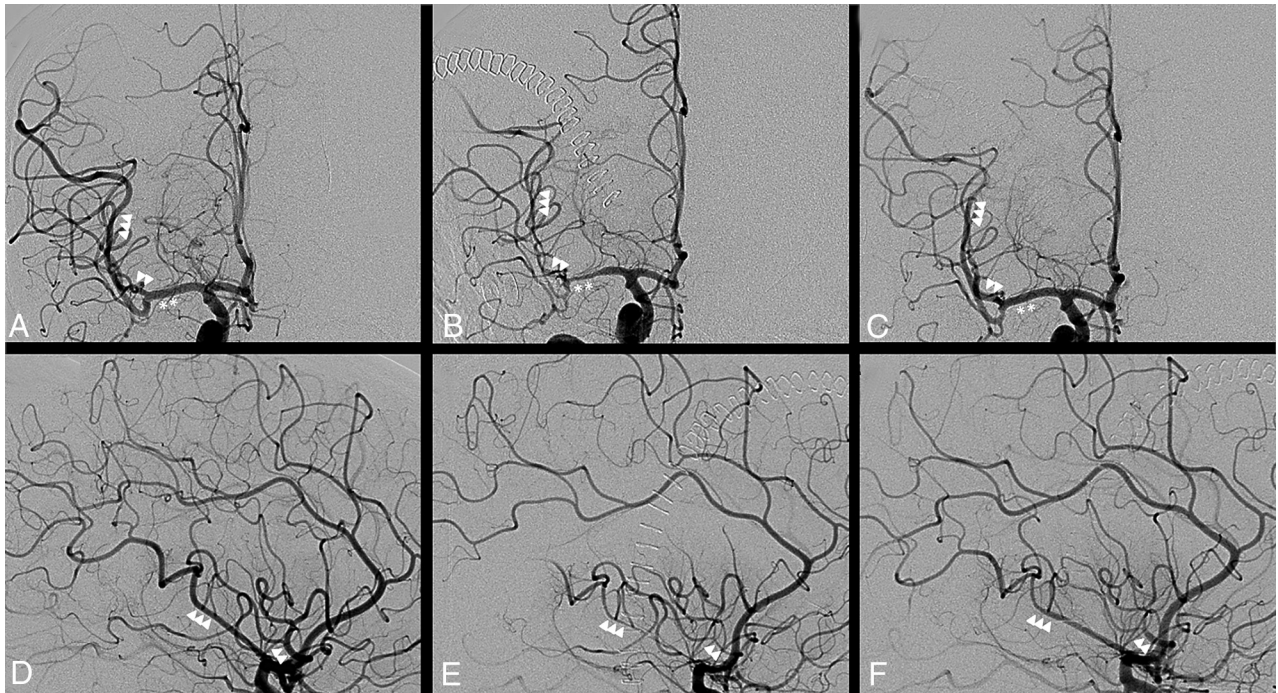
patients with a WFNS score  $\geq$  IV were less frequent in the second period (32% versus 50%,  $P = .02$ ).

When we compared the angioplasty strategy used for each arterial territory rather than at the patient level, the rate of postangioplasty DCIn after distal balloon angioplasty was similar with or without intravenous milrinone (respectively, 1/56 versus 0/31,  $P = 1$ ). It was lower than after other approaches (respectively, 41/87 versus 16/99,  $P < .001$ ) even by including only patients who received intravenous milrinone (respectively, 1/56 versus 10/53,  $P = .003$ ).

### DISCUSSION

Our study suggests that distal balloon angioplasty is more effective than and has the same safety as conventional angioplasty to prevent DCIn and vasospasm. It failed to give evidence of a clinical benefit of this new angioplasty strategy in patients with aSAH.

Angioplasty for vasospasm is broadly used in many centers, but its benefit is still unproven.<sup>13</sup> Conventional angioplasty combines balloon angioplasty for proximal vasospasm and chemical angioplasty for distal vasospasm.<sup>3</sup> Chemical angioplasty is effective for treating distal vasospasm, but its effect is not lasting, even with daily sessions because vasospasm frequently reappears after a few hours.<sup>3–5,14</sup> Continuous chemical angioplasty for several days may have a more lasting effect but is associated, in our experience, with a very high rate of cere-



**FIG 3.** An example of distal transluminal balloon angioplasty of the anterior and posterior M2 branches of the right middle cerebral artery (same patient as in Fig 1). Front (A–C) and lateral (D–F) angiograms of the right internal carotid artery. DSA before angioplasty (B and E) shows a severe vasospasm (60%) of M1 (double star) and the anterior (double arrowhead) and posterior (triple arrowhead) M2 branches, with distal delayed enhancement compared with DSA before vasospasm (A and D), which is cured after a distal balloon angioplasty procedure (C and F).

**Table 3: Outcome of patients with aSAH**

	Total (N = 392)	Period 1 (n = 160) <sup>a</sup>	Period 2 (n = 232) <sup>a</sup>	P Value
Complications of angioplasty				
Cerebral infarction (No.) (%)	10 (2.5%)	4 (2.5%)	6 (2.6%)	.1
Intracranial hemorrhage (No.) (%)	4 (0.7%)	1 (0.6%)	3 (1.3%)	.64
Malignant edema (No.) (%)	4 (1%)	4 (2.5%)	0 (0)	.02
DCIn				
DCIn (No.) (%)	38 (9.6%)	20 (12.5%)	18 (7.7%)	.11
Postangioplasty DCIn (No.) (%)	17 (4.3%)	12 (7.5%)	5 (2.2%)	.01
DCIn without angioplasty (No.) (%)	26 (6.6%)	12 (7.5%)	14 (6.0%)	.27
New angioplasty (No.) (%)	49 (12%)	30 (19%)	19 (8%)	.002
1-Month death (No.) (%)	42 (11%)	18 (11%)	24 (10%)	.45
6- to 12-Month mRS ≤ 2 (No.) (%)	300 (76%)	117 (73%)	183 (79%)	.12

<sup>a</sup>Period 1/period 2 (see Table 1).

bral embolism.<sup>4</sup> However, arterial ruptures have been reported using a compliant balloon, especially in small and distal arteries.<sup>15</sup> In that setting, most interventional neuroradiologists do not perform balloon angioplasty beyond the first segments of the cerebral arteries. Balloon angioplasty using noncompliant rather than compliant balloons has been suggested to prevent any overdistension and injury of the artery.<sup>16</sup> However, in our experience, this technique was associated with a higher rate of recurrent vasospasm or failure of angioplasty or dissection because of the difficulty of choosing the right diameter of the balloon and navigating with a more rigid balloon catheter.

The feasibility of distal balloon angioplasty using an extracompliant balloon has been recently reported. Our study is the first, to our knowledge, to report a better efficacy with the same safety of this approach compared with conventional angioplasty to prevent DCIn. Its efficacy may be explained by both the lasting and distal effects of distal balloon angioplasty on vasospasm. Kohama et al<sup>17</sup>

showed that symptomatic vasospasm is due, in 30% of patients, to isolated vasospasm of the second segment of the cerebral arteries. The vasospasm of these segments cannot be treated by proximal balloon angioplasty. The recent use of an extracompliant balloon for distal balloon angioplasty probably explains the excellent safety of this approach in our series and that of Santillan et al.<sup>8</sup> Extracompliant balloons navigate better than noncompliant balloons. When the balloon is inflated over the nominal diameter of the artery, it first tends to increase

its length rather than its diameter as shown in Fig 2. Thus, extracompliant balloons are commonly used for a remodeling technique to treat distal aneurysms.

Our study failed to prove the clinical benefit of distal balloon angioplasty in the aSAH population compared with the conventional approach, despite a lower rate of postangioplasty DCIn. We hypothesize that our study may have lacked power using the mRS scale, which underestimates cognitive impairment<sup>18</sup> or by including, in the analysis, patients with aSAH rather than only those with angioplasty (see Limitations below). We also speculate that the higher rate of patients treated by intravenous milrinone in the second period may have had adverse confounding effects on clinical outcome.<sup>10</sup> Comparison of our results with recent control groups of randomized trials is shown in Table 4.<sup>8,19,20</sup> Our cohort of patients during the second period tended to have a lower rate of DCIn and a better rate of favorable outcome, with quite similar

**Table 4: Comparative outcome with recent studies<sup>a</sup>**

	Fisher $\geq 3$	WFNS $< IV$	DCIn	Angioplasty/Approach	mRS $\geq 4$	Death
Our study (N = 232)	83%	77%	8%	42%/Distal balloon angioplasty	17%	10%
Matsuda et al 2016 <sup>20</sup> (N = 74)	NA	92%	11%	18%/Conventional	18%	NA
Macdonald et al 2012 <sup>19</sup> (N = 189)	>85%	84%	13%	21%/Conventional	24%	6%
Santillan et al 2011 <sup>8</sup> (N = 32) <sup>b</sup>	65%	60%	NA	100%/Distal balloon angioplasty	17%	0%

**Note:**—NA indicates not applicable.

<sup>a</sup> Our results during the second period (with distal balloon angioplasty) were compared with those in the series of Santillan et al<sup>8</sup> and control groups of recent randomized aSAH trials.

<sup>b</sup> Only patients who had an angioplasty of vasospasm were included.

baseline characteristics and a 2-times higher rate of angioplasty using a distal balloon rather than conventional angioplasty. Santillan et al<sup>8</sup> reported a similar rate of new angioplasty (7.5%), a lower rate of procedure-related symptomatic complications (0%), and a higher rate of mRS  $< 2$  outcome in a series of 32 patients treated by distal balloon angioplasty (82%). Better baseline characteristics may explain such differences in outcome compared with our series.

Our study reports complications with distal balloon angioplasty. The possible occurrence of arterial dissection, even if most are asymptomatic, underlines the importance of a careful technique of navigation and balloon inflation as described in the Materials and Methods. In our experience, arterial dissections occurred more often during catheterization of angulated arteries rather than during balloon inflation. No arterial rupture was observed in our study. Santillan et al<sup>8</sup> reported 1 rupture of a remnant clipped communicating aneurysm during navigation. A full dose of heparin should be given during the procedure to prevent embolism (except in the presence of a large infarction). Angioplasty should not be performed in territories with an extensive infarct, given the high risk of reperfusion injury. Navigation may fail in angled or distal branches. Finally, our study shows that most of DCIns occur before any angioplasty. Further studies are needed to better determine indications of angioplasty as a preventive approach.

### Limitations

Our study was retrospective and may have introduced interpretation biases. Safety and efficacy were assessed by 2 observers, including 1 independent of the treatment, to limit these biases. DCIn determination and angioplasty data were blinded, and clinical outcome was assessed by 1 independent observer.

The historical comparison may have introduced confounding factors. The higher rate of patients treated by intravenous vasodilators and angioplasty in the second period may have affected the DCIn rate (the higher the number of patients treated, the more likely it is that DCIn had been prevented). Some intravenous vasodilators such as clazosentan in the Conscious-3 (Clazosentan in Aneurysmal Subarachnoid Hemorrhage) trial are associated with a lower rate of DCIn.<sup>19</sup> However, there is still no evidence of the efficacy effect of intravenous milrinone in the literature. Some authors even question intravenous vasodilators possibly being associated with a higher risk of adverse effects.<sup>10,20,21</sup> We also analysed ‘postangioplasty DCIn’ and compared angioplasty strategy and subgroup of patient with and without intravenous milrinone. Actually, the rate of patient treated by angioplasty is more prone to have a bad confounding effect on ‘postangioplasty DCIn’ since

the higher the number of patients treated the more likely it is that DCIn had occurred rather after that without angioplasty.

The subgroup analysis of patients with high-grade vasospasm was not possible in the current study. Transcranial Doppler data were not available retrospectively for all the patients or for all the territories (including distal arteries). CTA and DSA data were available only in patients with high suspicion or high risk of delayed cerebral ischemia. By including only patients with angioplasty, we have shown a lower rate of DCIn and a higher rate of favorable outcome during the second period. However, these results are questionable because the higher rate of angioplasty during the second period, probably due to larger indication criteria, artificially decreases the ratio between DCIn or favorable outcome and angioplasty. Thus, all patients with aSAH (rather than only those with angioplasty or distal angioplasty) were included in the main analysis, even if this inclusion reduces the power of the study to show a benefit of distal balloon angioplasty.

### CONCLUSIONS

Our study suggests that distal balloon angioplasty decreases the risk of DCIn and recurrence of vasospasm after angioplasty compared with the conventional approach of angioplasty. Randomization of distal balloon angioplasty versus no angioplasty in patients with a high risk of DCIn is warranted to provide evidence of its clinical benefit.

### REFERENCES

1. Aburto-Murrieta Y, Marquez-Romero JM, Bonifacio-Delgadillo D, et al. **Endovascular treatment: balloon angioplasty versus nimodipine intra-arterial for medically refractory cerebral vasospasm following aneurysmal subarachnoid hemorrhage.** *Vasc Endovascular Surg* 2012;46:460–65 CrossRef Medline
2. Khatri R, Memon MZ, Zacharatos H, et al. **Impact of percutaneous transluminal angioplasty for treatment of cerebral vasospasm on subarachnoid hemorrhage patient outcomes.** *Neurocrit Care* 2011; 15:28–33 CrossRef Medline
3. Abruzzo T, Moran C, Blackham KA, et al. **Invasive interventional management of post-hemorrhagic cerebral vasospasm in patients with aneurysmal subarachnoid hemorrhage.** *J Neurointerv Surg* 2012;4:169–77 CrossRef Medline
4. Albanese E, Russo A, Quiroga M, et al. **Ultrahigh-dose intraarterial infusion of verapamil through an indwelling microcatheter for medically refractory severe vasospasm: initial experience—clinical article.** *J Neurosurg* 2010;113:913–22 CrossRef Medline
5. Anderegg L, Beck J, Z'Graggen WJ, et al. **Feasibility and safety of repeat instant endovascular interventions in patients with refractory cerebral vasospasms.** *AJNR Am J Neuroradiol* 2017;38:561–67 CrossRef Medline
6. Macdonald RL. **Delayed neurological deterioration after subarachnoid haemorrhage.** *Nat Rev Neurol* 2014;10:44–58 CrossRef Medline
7. Vergouwen MD. **Vasospasm versus delayed cerebral ischemia as an**



- outcome event in clinical trials and observational studies. *Neurocrit Care* 2011;15:308–11 CrossRef Medline**
8. Santillan A, Knopman J, Zink W, et al. **Transluminal balloon angioplasty for symptomatic distal vasospasm refractory to medical therapy in patients with aneurysmal subarachnoid hemorrhage.** *Neurosurgery* 2011;69:95–101; discussion 102 CrossRef Medline
  9. Connolly ES Jr, Rabinstein AA, Carhuapoma JR, et al; American Heart Association Stroke Council, Council on Cardiovascular Radiology and Intervention, Council on Cardiovascular Nursing, Council on Cardiovascular Surgery and Anesthesia, Council on Clinical Cardiology. **Guidelines for the management of aneurysmal subarachnoid hemorrhage: a guideline for healthcare professionals from the American Heart Association/American Stroke Association.** *Stroke* 2012;43:1711–37 CrossRef Medline
  10. Lannes M, Zeiler F, Guichon C, et al. **The use of milrinone in patients with delayed cerebral ischemia following subarachnoid hemorrhage: a systematic review.** *Can J Neurol Sci* 2017;44:152–60 CrossRef Medline
  11. Labeyrie MA, Civelli V, Reiner P, et al. **Prevalence and treatment of spontaneous intracranial artery dissections in patients with acute stroke due to intracranial large vessel occlusion.** *J Neurointerv Surg* 2018;10:761–64 CrossRef Medline
  12. Vergouwen MD, Vermeulen M, van Gijn J, et al. **Definition of delayed cerebral ischemia after aneurysmal subarachnoid hemorrhage as an outcome event in clinical trials and observational studies: proposal of a multidisciplinary research group.** *Stroke* 2010;41:2391–95 CrossRef Medline
  13. Boulouis G, Labeyrie MA, Raymond J, et al. **Treatment of cerebral vasospasm following aneurysmal subarachnoid haemorrhage: a systematic review and meta-analysis.** *Eur Radiol* 2017;27:3333–42 CrossRef Medline
  14. Linfante I, Delgado-Mederos R, Andreone V, et al. **Angiographic and hemodynamic effect of high concentration of intra-arterial nicardipine in cerebral vasospasm.** *Neurosurgery* 2008;63:1080–86; discussion 86–87 CrossRef Medline
  15. Zwienerberg-Lee M, Hartman J, Rudisill N, et al; Balloon Prophylaxis for Aneurysmal Vasospasm (BPAV) Study Group. **Effect of prophylactic transluminal balloon angioplasty on cerebral vasospasm and outcome in patients with Fisher grade III subarachnoid hemorrhage: results of a phase II multicenter, randomized, clinical trial.** *Stroke* 2008;39:1759–65 CrossRef Medline
  16. Eskridge JM, McAuliffe W, Song JK, et al. **Balloon angioplasty for the treatment of vasospasm: results of first 50 cases.** *Neurosurgery* 1998;42:510–16; discussion 16–17 CrossRef Medline
  17. Kohama M, Sugiyama S, Sato K, et al. **Difference in transcranial Doppler velocity and patient age between proximal and distal middle cerebral artery vasospasms after aneurysmal subarachnoid hemorrhage.** *Cerebrovasc Dis Extra* 2016;6:32–39 CrossRef Medline
  18. Eagles ME, Tso MK, Macdonald RL. **Cognitive impairment, functional outcome and delayed cerebral ischemia after aneurysmal subarachnoid hemorrhage.** *World Neurosurg* 2019 Jan 10. [Epub ahead of print] CrossRef Medline
  19. Macdonald RL, Higashida RT, Keller E, et al. **Randomized trial of clazosentan in patients with aneurysmal subarachnoid hemorrhage undergoing endovascular coiling.** *Stroke* 2012;43:1463–69 CrossRef Medline
  20. Matsuda N, Naraoka M, Ohkuma H, et al. **Effect of cilostazol on cerebral vasospasm and outcome in patients with aneurysmal subarachnoid hemorrhage: a randomized, double-blind, placebo-controlled trial.** *Cerebrovasc Dis* 2016;42:97–105 CrossRef Medline
  21. Shen J, Pan JW, Fan ZX, et al. **Dissociation of vasospasm-related morbidity and outcomes in patients with aneurysmal subarachnoid hemorrhage treated with clazosentan: a meta-analysis of randomized controlled trials.** *J Neurosurg* 2013;119:180–89 CrossRef Medline