

**Are your MRI contrast agents cost-effective?**  
Learn more about generic Gadolinium-Based Contrast Agents.



# AJNR

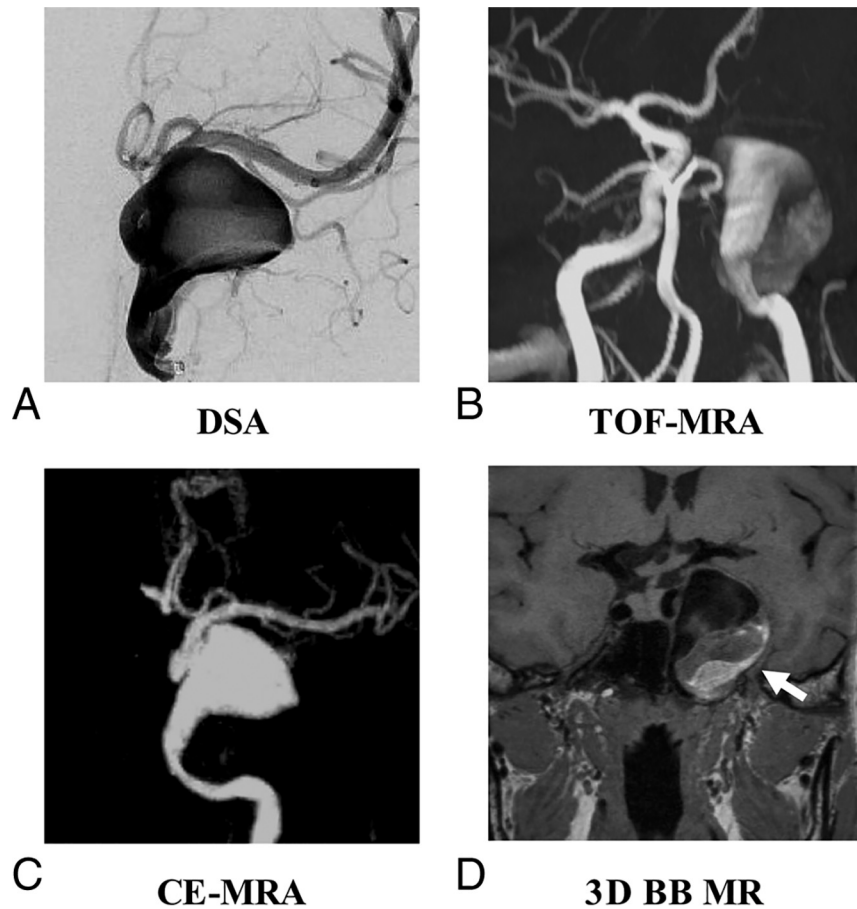
## Erratum

*AJNR Am J Neuroradiol* published online 5 September 2019  
<http://www.ajnr.org/content/early/2019/09/05/ajnr.A6206>

This information is current as  
of April 18, 2024.

The authors regret that in the article “Surveillance of Unruptured Intracranial Saccular Aneurysms Using Noncontrast 3D-Black-Blood MRI: Comparison of 3D-TOF and Contrast-Enhanced MRA with 3D-DSA” (*AJNR Am J Neuroradiol* 2019;40:960–66), the legend for Fig 4 did not match the figure. A corrected legend with the original figure is reproduced below.

<http://dx.doi.org/10.3174/ajnr.A6206>



AQ:fig

**FIG 4.** A, A 63-year-old woman with a right internal carotid artery aneurysm on DSA. 3D black-blood (BB) SPACE (D) can clearly visualize the sac and intraluminal thrombus of the aneurysm, which is superior to DSA (A), TOF-MRA (B), and contrast-enhanced (CE)-MRA (C).