

Are your MRI contrast agents cost-effective?

Learn more about generic Gadolinium-Based Contrast Agents.



**FRESENIUS
KABI**

caring for life

AJNR

Neuroradiologists, Be Mindful of the Neuroinvasive Potential of COVID-19

M. Morris and V.M. Zohrabian

AJNR Am J Neuroradiol published online 30 April 2020

<http://www.ajnr.org/content/early/2020/04/30/ajnr.A6551>

This information is current as
of April 17, 2024.

Neuroradiologists, Be Mindful of the Neuroinvasive Potential of COVID-19



The COVID-19 pandemic continues to have a far-reaching impact on nearly all aspects of society. First identified in December 2019 in Wuhan, the capital city of Hubei, China, COVID-19 is disseminated primarily via respiratory droplets and has the potential to cause severe respiratory distress in vulnerable patients, resulting in pneumonia, acute respiratory distress syndrome (ARDS), multiorgan dysfunction, and death.¹ Although recent literature on the virus has centered on the respiratory manifestations of the disease, a multitude of studies during the past few decades have shown that several respiratory viruses, including coronaviruses (CoVs), have neuroinvasive potential, demonstrating the ability to spread from the respiratory tract to the CNS to trigger or exacerbate neurologic pathology as a result of direct viral replication in the CNS or overactive host immune response.^{2,3} This information is of interest to neuroradiologists, given that as the pandemic rages on, they may encounter sequelae of disease in the brain and spinal cord as these patients are imaged for neurologic symptoms.

First isolated in the mid-1960s, 6 types of CoVs, large-enveloped nonsegment positive-sense RNA viruses, are known to infect humans: HCoV-229E, HCoV-OC43, HCoV-NL63, HCoV-HKU1, Severe Acute Respiratory Syndrome-CoV (SARS), Middle East Respiratory Syndrome-CoV (MERS), and now, SARS-CoV-2 (COVID-19), a close relative of SARS. Most of these CoVs result in mild disease, with the exception of SARS and MERS, and most recently COVID-19, which may be lethal. Moreover, HCoV-229E, HCoV-OC43, SARS, and MERS have demonstrated neurotropism, or the ability to infect resident cells of the CNS (neuronal and glial).⁴ MERS and SARS have demonstrated the ability to invade human neuronal cells in vitro. Moreover, SARS, among numerous other CoV strains, has been found in the CSF of patients, as well as in neurons in situ per postmortem studies.⁵⁻⁷ It is known that both SARS and COVID-19 leverage the angiotensin-converting enzyme 2 (ACE-2) receptor for entry into host cells, though there is debate as to whether there are sufficient concentrations of this receptor in the CNS to explain their neurotropic nature.^{8,9}

There are 2 main candidate mechanisms by which respiratory viruses may infect the CNS: hematogenous or neuronal retrograde.

In the hematogenous route, the virus may pass through the BBB by transcytosis across brain microvascular endothelial cells and pericytes by endocytic vesicles or, rather, directly infect endothelial or epithelial cells to pass across the BBB or blood-CSF barrier in the choroid plexus of the ventricular system, respectively. Alternatively, the virus could be transported intracellularly in a concealed manner by leukocytes. There is mixed evidence regarding the viability of the hematogenous route in the neuroinvasiveness of CoVs. On the one hand, it has been reported that SARS has the ability to directly infect the BBB epithelium, representing 1 avenue of hematogenous spread.³ Additionally, several strains of CoVs, including SARS, have shown the ability to infect multiple types of leukocytes both in vitro and in vivo.^{5,10,11} This feature represents a potential second avenue of hematogenous spread, akin to the “Trojan Horse” model exhibited by HIV, by which the virus is covertly introduced to the CNS by a host’s infected immune cells. However, evidence against the hematogenous route revolves around human postmortem in situ studies demonstrating the presence of SARS only in neurons and not other cell types of the brain, as was recently argued by Li et al.⁹

In the neuronal retrograde route of CNS entry, the virus invades neurons in the periphery, such as olfactory receptor neurons, those of the trigeminal nerve that reside in the nasal cavity, or sensory fibers of the vagus nerve in the brain stem, and leverages active transport mechanisms to gain access to the CNS.¹² The ability of SARS, MERS, and other CoVs to leverage this mechanism has been demonstrated in mouse models, via intranasal inoculation and subsequent infection of the olfactory bulb, as in Fig 1.¹³⁻¹⁶ Once in the CNS, some strains of CoVs have been shown to be able to propagate between neurons, possibly through synaptic transmission.³

Several CoVs have demonstrated the potential for neurovirulence in both children and adults.^{2,17} While no direct causal link has been established, multiple strains of CoVs have been associated with chronic CNS diseases, such as multiple sclerosis and neurodegeneration,^{2,3} in addition to acute processes, such as encephalitis,⁶ acute flaccid paralysis,¹⁸ Guillan-Barre syndrome,¹⁹ acute disseminated encephalomyelitis (ADEM),²⁰ focal seizures,²¹ and other neurologic syndromes, including hemorrhage and stroke.²²⁻²⁴ Clinical studies have begun to elucidate physiologic changes associated with acute CoV CNS infection, such as unique cytokine profiles;^{7,25} moreover, malfunction of the cardiorespiratory center in

Indicates open access to non-subscribers at www.ajnr.org

<http://dx.doi.org/10.3174/ajnr.A6551>

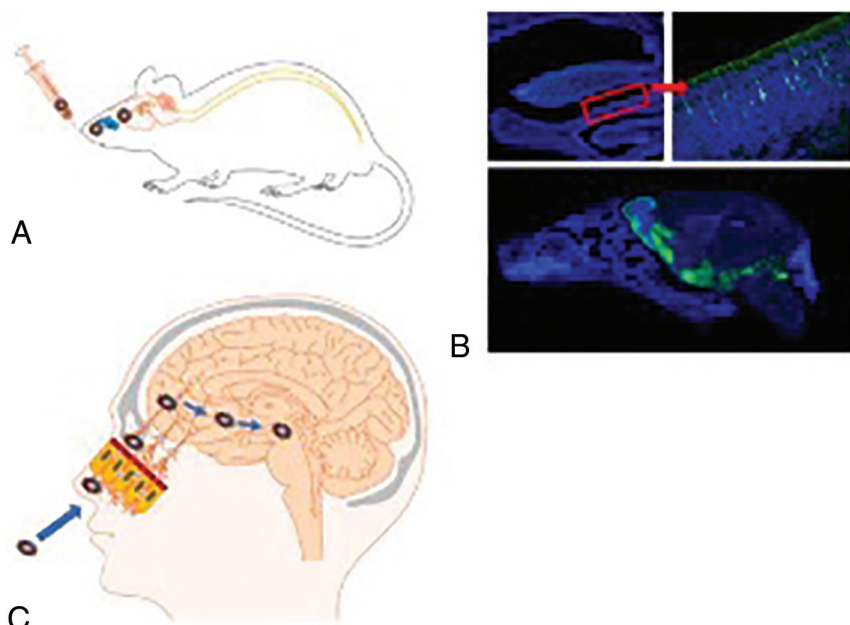


FIGURE. Representation of the neuronal retrograde method of CoV entry into the CNS. A, Upper left depicts a schematic of the experimental design allowing CoV infection in mouse experiments. The virus is introduced into the nasal cavity, traveling from the olfactory receptor neurons (ORN) to the olfactory bulb in the brain, and from there, to various areas in the brain stem. C, Lower left depicts the schematic for the same route in humans. B, Upper right depicts a decalcified murine nasal cavity from one such experiment. A close-up image denoted by a red arrow shows infected ORNs in green. The lower half of the panel shows dissemination of the virus through infected neurons, from the olfactory bulb to various areas of the brain stem. Reprinted with permission from Desforges et al.²

the brain stem has been hypothesized to play a potential role in respiratory distress in both humans⁹ and mouse models.¹⁵

Although it is still fairly early in the COVID-19 pandemic, there are already reports of neurologic symptoms. In a study published in February this year in hospitalized patients with COVID-19 in Wuhan, China, the authors found that around one-third of patients had neurologic manifestations, most commonly dizziness and headache, though peripheral nervous system symptoms, primarily hypogeusia and hyposmia, were also seen.²⁶ A small number of patients experienced acute cerebrovascular injury (ischemic stroke, cerebral hemorrhage), loss of consciousness, and muscle injury. It is interesting that some patients developed hypogeusia or hyposmia, perhaps in support of the retrograde neuronal route of CNS invasion in COVID-19 via the olfactory bulb or other sensory branches of cranial nerves.

Several older reports have incorporated imaging in the neurologic work-up of patients with CoV infections. In a 15-year-old previously healthy boy, CoV-OC43 was detected in the CSF and nasopharyngeal secretions by polymerase chain reaction, while MR imaging of the brain and spinal cord demonstrated findings characteristic of ADEM, with T2-weighted hyperintensities in white matter tracts of the brain, some of which enhanced after intravenous gadolinium administration, as well as some in the spinal cord, which were nonenhancing, with follow-up imaging demonstrating improvement in these lesions.²⁰ In a study of hospitalized children with CoV and acute encephalitis-like syndrome, half of patients who underwent MRI or CT showed abnormalities, such as in the

temporal lobes in patients with seizures, in the periventricular regions in patients with headaches, and in the basal ganglia and thalami in patients with fever and/or vomiting.⁷ Moreover, in a study that incorporated imaging in 3 patients with MERS, brain MRI revealed widespread, bilateral T2-weighted hyperintense lesions in white matter and subcortical areas of the frontal, temporal, and parietal lobes; the basal ganglia; and corpus callosum, none of which showed gadolinium enhancement, which investigators attributed to ADEM, anoxic injury, and encephalitis, respectively.^{22,24} Most interestingly, meningeal enhancement has not been shown in brain MRI of patients with CoV infection, arguing against a hematogenous method of entry into the CNS.^{22,24}

Neuroradiologists will undoubtedly encounter increasing numbers of patients with COVID-19 in the course of daily practice. Therefore, they should be cognizant of the potential for CNS injury, either directly as the virus replicates in cells, or indirectly as host immune responses wage an all-out war. Furthermore, neuroradiologists should be wary of secondary

impacts of COVID-19 on the CNS in severely ill patients, such as anoxic brain injury as a result of ARDS, cerebral hemorrhage as a result of thrombocytopenia, and disseminated intravascular coagulation, and air and fat emboli in patients with sepsis. As COVID-19 continues to spread across the globe, neuroradiologists should entertain this virus as a possible etiologic agent in patients with progressive or worsening CNS symptoms.

The possible imaging manifestations of CoV disease in the brain and spinal cord are varied, as shown by the aforementioned studies, and include injuries to both gray and white matter. In reading rooms, neuroimaging should be tailored to the clinical question while evaluating for complications such as ADEM, encephalitis, and Guillain-Barre syndrome, as reported in prior case series, whenever the clinical scenario can support such etiologies. Just as important, imaging should be reasonable and not excessive, keeping in mind that hospitalized patients with COVID-19 tend to be quite ill, so as to provide optimal patient care, preserve hospital resources, and minimize exposure of radiology staff, such as technologists and nurses, to the virus. With time and large-scale and rigorous investigations, hopefully the full spectrum of neuropathologies and exact mechanisms of injury in patients with COVID-19 will be uncovered.

REFERENCES

1. Guan WJ, Ni ZY, Hu Y, et al; China Medical Treatment Expert Group for Covid-19. **Clinical characteristics of coronavirus disease 2019 in China.** *N Engl J Med* 2020 Feb 28. [Epub ahead of print] CrossRef Medline

2. Desforbes M, Le Coupanec A, Dubeau P, et al. **Human coronaviruses and other respiratory viruses: underestimated opportunistic pathogens of the central nervous system?** *Viruses* 2019;12:14 [CrossRef Medline](#)
3. Desforbes M, Le Coupanec A, Brison E, et al. **Neuroinvasive and neurotropic human respiratory coronaviruses: potential neurovirulent agents in humans.** *Adv Exp Med Biol* 2014;807:75–96 [CrossRef Medline](#)
4. Arbour N, Day R, Newcombe J, et al. **Neuroinvasion by human respiratory coronaviruses.** *J Virol* 2000;74:8913–21 [CrossRef Medline](#)
5. Gu J, Gong E, Zhang B, et al. **Multiple organ infection and the pathogenesis of SARS.** *J Exp Med* 2005;202:415–24 [CrossRef Medline](#)
6. Morfopoulou S, Brown JR, Davies EG, et al. **Human coronavirus OC43 associated with fatal encephalitis.** *N Engl J Med* 2016;375:497–98 [CrossRef Medline](#)
7. Li Y, Li H, Fan R, et al. **Coronavirus infections in the central nervous system and respiratory tract show distinct features in hospitalized children.** *Intervirology* 2016;59:163–69 [CrossRef Medline](#)
8. Baig AM, Khaleeq A, Ali U, et al. **Evidence of the COVID-19 virus targeting the CNS: tissue distribution, host-virus interaction, and proposed neurotropic mechanisms.** *ACS Chem Neurosci* 2020. <https://doi.org/10.1021/acscchemneuro.0c00122>. Accessed March 25, 2020
9. Li YC, Bai WZ, Hashikawa T. **The neuroinvasive potential of SARS-CoV2 may play a role in the respiratory failure of COVID-19 patients.** *J Med Virol* 2020 <https://https://doi.org/10.1002/jmv.25728>. Accessed March 25, 2020
10. Collins AR. **In vitro detection of apoptosis in monocytes/macrophages infected with human coronavirus.** *Clin Diagn Lab Immunol* 2002;9:1392–95 [CrossRef Medline](#)
11. Nicholls JM, Butany J, Poon LM, et al. **Time course and cellular localization of SARS-CoV nucleoprotein and RNA in lungs from fatal cases of SARS.** *PLoS Med* 2006;3:e27 [CrossRef Medline](#)
12. Swanson II PA, McGavern D. **Portals of Viral Entry into the Central Nervous System.** In: Dorovine-Zis K, ed. *The Blood-Brain Barrier in Health and Disease Volume 2: Pathophysiology and Pathology*, 1st ed., Boca Raton, FL: CRC Press; 2016:23–47
13. McCray PB Jr, Pewe L, Wohlford-Lenane C, et al. **Lethal infection of K18-hACE2 mice infected with severe acute respiratory syndrome coronavirus.** *J Virol* 2007;81:813–21 [CrossRef Medline](#)
14. St-Jean JR, Jacomy H, Desforbes M, et al. **Human respiratory coronavirus OC43: genetic stability and neuroinvasion.** *J Virol* 2004;78:8824–34 [CrossRef Medline](#)
15. Netland J, Meyerholz DK, Moore S, et al. **Severe acute respiratory syndrome coronavirus infection causes neuronal death in the absence of encephalitis in mice transgenic for human ACE2.** *J Virol* 2008;82:7264–75 [CrossRef Medline](#)
16. Li K, Wohlford-Lenane C, Perlman S, et al. **Middle East Respiratory Syndrome coronavirus causes multiple organ damage and lethal disease in mice transgenic for human dipeptidyl peptidase 4.** *J Infect Dis* 2016;213:712–22 [CrossRef Medline](#)
17. Principi N, Bosis S, Esposito S. **Effects of coronavirus infections in children.** *Emerging Infect Dis* 2010;16:183–88 [CrossRef Medline](#)
18. Turgay C, Emine T, Ozlem K, et al. **A rare cause of acute flaccid paralysis: human coronaviruses.** *J Pediatr Neurosci* 2015;10:280–01 [CrossRef Medline](#)
19. Sharma K, Tengsupakul S, Sanchez O, et al. **Guillain-Barré syndrome with unilateral peripheral facial and bulbar palsy in a child: a case report.** *SAGE Open Med Case Rep* 2019;7:2050313X1983875 [CrossRef Medline](#)
20. Yeh EA, Collins A, Cohen ME, et al. **Detection of coronavirus in the central nervous system of a child with acute disseminated encephalomyelitis.** *Pediatrics* 2004;113:e73–76 [CrossRef Medline](#)
21. Lau KK, Yu WC, Chu CM, et al. **Possible central nervous system infection by SARS coronavirus.** *Emerging Infect Dis* 2004;10:342–44 [CrossRef Medline](#)
22. Algahtani H, Subahi A, Shirah B. **Neurological complications of Middle East Respiratory Syndrome coronavirus: a report of two cases and review of the literature.** *Case Rep Neurol Med* 2016;2016:3502683 [CrossRef Medline](#)
23. Bohmwald K, Gálvez NM, Rios M, et al. **Neurologic alterations due to respiratory virus infections.** *Front Cell Neurosci* 2018;12:386 [CrossRef Medline](#)
24. Arabi YM, Harthi A, Hussein J, et al. **Severe neurologic syndrome associated with Middle East Respiratory Syndrome corona virus (MERS-CoV).** *Infection* 2015;43:495–501 [CrossRef Medline](#)
25. Xu J, Zhong S, Liu J, et al. **Detection of severe acute respiratory syndrome coronavirus in the brain: potential role of the chemokine mlg in pathogenesis.** *Clin Infect Dis* 2005;41:1089–96 [CrossRef Medline](#)
26. Mao L, Wang M, Chen S, et al. **Neurological manifestations of hospitalized patients with COVID-19 in Wuhan, China: a retrospective case series study.** *MedRxiv* 2020. <https://doi.org/10.1101/2020.02.22.20026500>. Accessed March 25, 2020

 M. Morris
 V.M. Zohrabian

Department of Radiology and Biomedical Imaging
 Yale School of Medicine
 New Haven, Connecticut