

Are your MRI contrast agents cost-effective?

Learn more about generic Gadolinium-Based Contrast Agents.



FRESENIUS  
KABI

caring for life

**AJNR**

**Reply:**

M. Shapiro, K. Srivatanakul, E. Raz, M. Litao, E. Nossek  
and P.K. Nelson

*AJNR Am J Neuroradiol* published online 25 March 2021  
<http://www.ajnr.org/content/early/2021/03/25/ajnr.A7098>

This information is current as  
of April 19, 2024.

## REPLY:

We are extremely thankful to the Hannover group for forwarding to the Editor their deep insights and critique. We see the resulting exchange as an excellent opportunity for a substantive anatomic discussion and debate in the Journal.

It appears that we agree on most points. We agree that study of vascular dural anatomy requires gross pathology and histology material, as acknowledged in the Limitations section of our publication. We agree that the channels we both reported go by varied names, hindering a comprehensive literature search. We also agree that the distinction between dural venous channels and bridging veins traversing the dura is not semantic, and furthermore, we agree that from the perspective of surgical safety this distinction is immaterial. We have also observed, in a less structured setting than your group (during surgery), the appearance of bridging veins traversing the dura to join with the recipient dural sinus.

The question as to whether a venous structure, once inside the dura, retains anatomic characteristics of a vein or assumes those of a venous sinus is a histologic question and, in our opinion, cannot be answered for all structures in question by either imaging or gross examination. Where we disagree is that we believe, based on existing evidence, that the structures we illustrated are sinuses:

1. They are lens-shaped, not round. This morphology closely resembles undisputed venous sinuses that traverse the dural sheets such as duplicated superior sagittal, falcine, and occipital sinuses (Fig 1A–F, Fig 2A, -B).
2. We have observed what appear to be arachnoid granulations inside several of the channels we called “dural venous sinuses,” which are certainly not a structure expected in a bridging vein (Fig 2C,-D and Fig 6 in our original publication).
3. Existence of tentorial venous sinuses is generally accepted, which is no proof of truth, but a strong supporting argument for the presence of similar channels in the supratentorial compartment (Fig 1G).

We view the dura as a sort of arterial and venous “tabula rasa”—meaning any part of the dura can form a sinus when sufficient flow or other factors encourage it—both in utero and under pathologic circumstances such as a falcotentorial fistula. Indeed, we feel this

view is entirely consistent with Padgett’s investigations,<sup>1</sup> repeatedly emphasizing the plexiform nature of dural venous structures.

Regarding the relationship between dural venous channels and dural fistulas, we feel that the varied opinions held by multiple groups as to their etiology and vascular pathoanatomy, given the relative paucity of data, are such that a productive discussion on the matter at this stage may be premature.

In conclusion, we believe that both bridging veins traversing the dura and supratentorial dural venous channels exist, and both are common. We continue to prefer the term “dural venous channel,” unless new data disprove this view. Perhaps “intradural venous channel” would be more of a semantic compromise. Regardless of whether any name at all will “catch,” we feel confident that both our efforts in this arena will continue.

## ACKNOWLEDGMENTS

We thank Dr. Matthew G. Young (Department of Radiology, NYU Grossman School of Medicine, New York, New York) for generating the cinematic rendering images in Figure 1.

## REFERENCE

1. Padgett DH. The cranial venous system in man in reference to development, adult configuration, and relation to the arteries. *Am J Anat* 1956;98:307–55 [CrossRef Medline](#)

• M. Shapiro

Department of Radiology and Neurology  
NYU Grossman School of Medicine  
New York, New York

• K. Srivatanakul

Department of Neurosurgery  
Tokai University  
Kanagawa, Japan

• E. Raz

Department of Radiology  
NYU Grossman School of Medicine  
New York, New York

• M. Litao

Department of Radiology  
NYU Grossman School of Medicine  
New York, New York

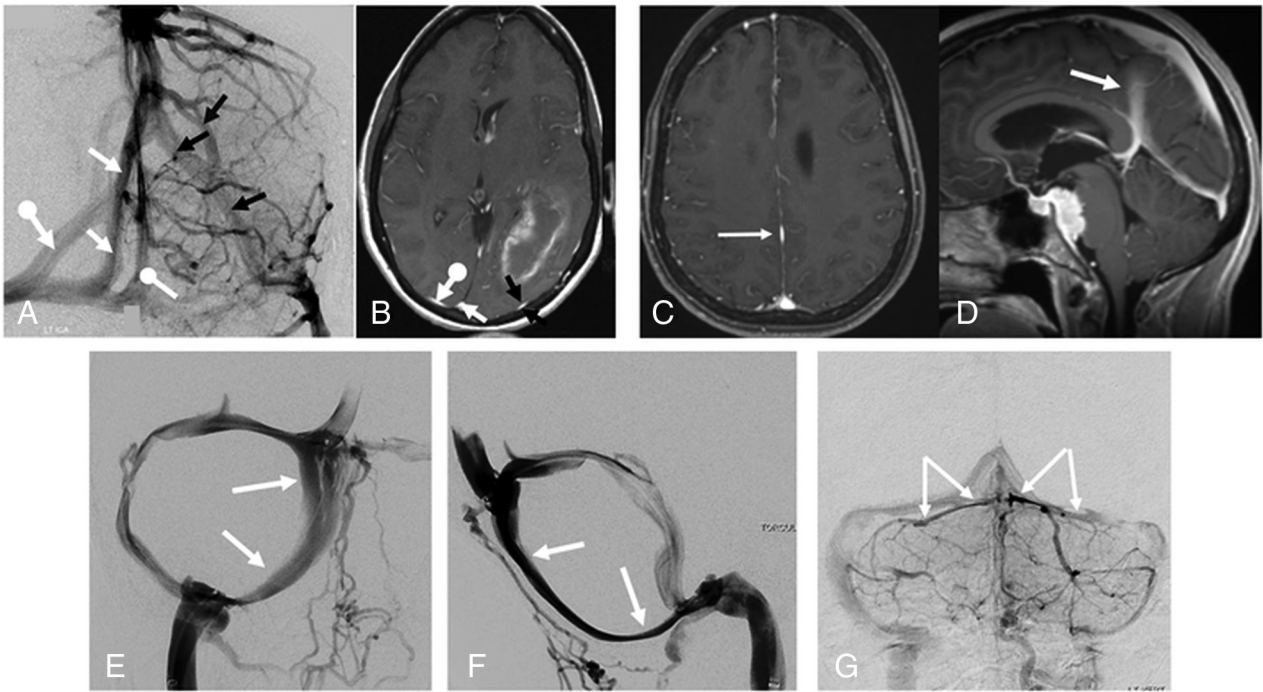
• E. Nossek

Department of Neurosurgery  
NYU Grossman School of Medicine  
New York, New York

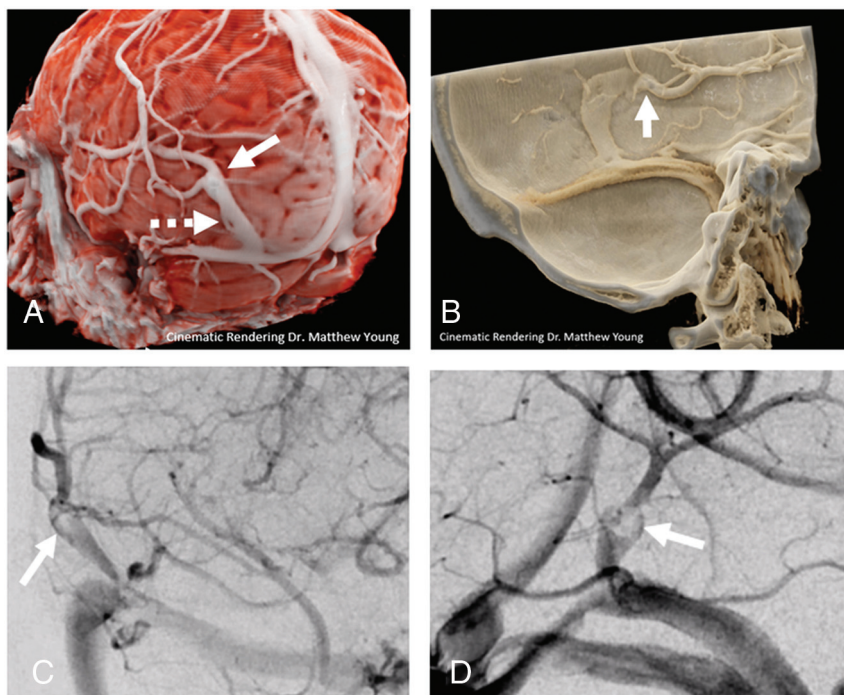
• P.K. Nelson

Department of Neurosurgery  
NYU Grossman School of Medicine  
New York, New York

<http://dx.doi.org/10.3174/ajnr.A7098>



**FIG 1.** Examples of dural venous sinuses/channels similar to those described in our index article. Angiography (A) and MR imaging (B) of same patient, with multiple dural channels in addition to the usual superior sagittal sinus. The additional channels, marked by similar *arrows* on both angiogram and MR image, are flattened, lens-shaped structures, just like the dural venous channels we describe. C and D, Axial and sagittal MR images of patient with a falcine sinus variant—the same flattened morphology as in A and B. E and F, Morphology of the occipital sinus on a venous digital subtraction injection. G, Typical flattened appearance of tentorial venous sinuses.



**FIG 2.** A and B, Cinematic renderings, highlighting transition points (*arrows*) between round bridging vein and flattened dural venous channel in 2 different cases. A small fenestration versus arachnoid granulation is present in A (*dashed arrow*); neither structure would be expected in a bridging vein. Frontal (C) and lateral (D) views of another arachnoid granulation inside a dural venous channel.