

Are your **MRI contrast agents** cost-effective?

Learn more about generic **Gadolinium-Based Contrast Agents**.



**FRESENIUS  
KABI**

caring for life

**AJNR**

## **Optimal Duration of MRI Follow-up to Safely Identify Middle Ear Residual Cholesteatoma**

A.-L. Fourez, M. Akkari, G. Gascou, P.-H. Lefevre, C. Duflos, A. Kaderbay, M. Mondain and F. Venail

*AJNR Am J Neuroradiol* published online 15 April 2021  
<http://www.ajnr.org/content/early/2021/04/15/ajnr.A7116>

This information is current as of April 18, 2024.

# Optimal Duration of MRI Follow-up to Safely Identify Middle Ear Residual Cholesteatoma

 A.-L. Fourez,  M. Akkari,  G. Gascou,  P.-H. Lefevre,  C. Duflos,  A. Kaderbay,  M. Mondain, and  F. Venail



## ABSTRACT

**BACKGROUND AND PURPOSE:** Previous studies have demonstrated the usefulness of non-EPI DWI for detection of residual cholesteatoma. However, limited data are available to determine the suitable duration of imaging follow-up after a first MR imaging with normal findings has been obtained. The present study aimed to determine the optimal duration of non-EPI DWI follow-up for residual cholesteatoma.

**MATERIALS AND METHODS:** A retrospective, monocentric study was performed between 2013 and 2019 and included all participants followed up after canal wall up tympanoplasty with at least 2 non-EPI DWI examinations performed on the same 1.5T MR imaging scanner. MR images were reviewed independently by 2 radiologists. Sensitivity and specificity values were calculated as a function of time after the operation. Receiver operating characteristic curves were analyzed to determine the optimal follow-up duration.

**RESULTS:** We analyzed 47 MRIs from 17 participants. At the end of the individual follow-up period, a residual cholesteatoma had been found in 41.1% of cases. The follow-up duration ranged from 20 to 198 months (mean, 65.9 [SD, 43.9] months). Participants underwent between 2 and 5 non-EPI DWI examinations. Analyses of the receiver operating characteristic curves revealed that the optimal diagnostic value of non-EPI DWI occurred 56 months after the operation when the first MR imaging performed a mean of 17.3 (SD, 6.8) months after the operation had normal findings (sensitivity = 0.71; specificity = 0.7, Youden index = 0.43).

**CONCLUSIONS:** Repeat non-EPI DWI is required to detect slow-growing middle ear residual cholesteatomas. We, therefore, recommend performing non-EPI DWI for at least the first 5 years after the initial operation.

The development of DWI has profoundly changed the management of middle ear cholesteatomas. An increasing number of surgeons no longer systematically perform second-look surgery, and MR imaging follow-up is performed if revision surgery is not needed to treat conductive hearing loss. Numerous studies have evaluated the sensitivity and specificity of EPI DWI and non-EPI DWI sequences for the detection of residual cholesteatoma. Non-EPI DWI sequences offer the best sensitivity and specificity and are suitable for the detection of residual cholesteatomas as small as 2 mm.<sup>1</sup> A recent meta-analysis of 26 studies concerning non-EPI DWI showed a pooled sensitivity and

specificity of 0.91 (95% CI, 0.87–0.95) and 0.92 (95% CI, 0.86–0.96), respectively.<sup>1</sup> Another meta-analysis reported a similar pooled sensitivity and specificity of 0.89 (95% CI, 0.52–0.99) and 0.93 (95% CI, 0.81–0.98), respectively.<sup>2</sup>


However, data on the diagnostic value of non-EPI DWI sequences regarding the optimal timing after the initial operation remain limited. Lingam et al<sup>3</sup> reported a sensitivity of 0.91 (95% CI, 0.79–0.97) and a specificity of 0.88 (95% CI, 0.69–0.97) with a median time to MR imaging of 5.4 months after the operation. Khemani et al<sup>4</sup> found a sensitivity of 0.82 (95% CI, 0.63–0.94) and a specificity of 0.90 (95% CI, 0.55–1.00) when MR imaging was performed 10–24 months after the operation.

Most authors agree that imaging follow-up should not start <12 months postsurgery,<sup>5–8</sup> to reduce the number of false-negatives due to residual cholesteatomas measuring <2 mm.<sup>9</sup> Nevertheless, the optimal duration of follow-up necessary to exclude the existence of a residual cholesteatoma if the findings of the first MR imaging are considered normal is unclear. In a recent retrospective series, follow-up non-EPI DWI detected residual cholesteatoma in 12 of 88 patients only after a mean interval of 3.8 years after the initial cholesteatoma surgery (median, 3.7 years; range, 1.6–7.9 years).<sup>10</sup> Pai et al<sup>10</sup> suggested that

Received June 11, 2020; accepted after revision February 15, 2021.

From the Departments of ENT and Head and Neck Surgery (A.-L.F., M.A., A.K., M.M., F.V.) and Neuroradiology (G.G., P.-H.L.), University Hospital Gui de Chaumié, and Department of Medical Information and Biostatistics (C.D.), University Hospital La Colombière, University of Montpellier, Montpellier, France; and Institute for Neurosciences de Montpellier (F.V.), Institut National de la Santé et de la Recherche Médicale U1051 and University of Montpellier, Montpellier, France.

Please address correspondence to Frederic Venail, MD, PhD, Department of ENT and Neck Surgery, University Hospital Gui de Chaumié, 80 Avenue Augustin Fliche, 34295 Montpellier Cedex 5, France; e-mail: f-venail@chu-montpellier.fr

 Indicates article with online supplemental data.

<http://dx.doi.org/10.3174/ajnr.A7116>

imaging follow-up should be performed for a minimum of 5 years postoperatively, without defining how this was calculated.

To provide more information on the optimal imaging follow-up duration, we describe the long-term follow-up imaging of participants with  $\geq 2$  non-EPI DWI examinations for residual middle ear cholesteatoma. The sensitivity and specificity values were calculated as a function of the duration of the follow-up, and the receiver operating characteristic curves were analyzed to determine the optimal follow-up time.

## MATERIALS AND METHODS

### Design and Settings

This retrospective, monocentric study was performed in the Ear, Nose, and Throat Department of University Hospital Gui de Chauillac tertiary referral center, with approval from the local ethics committee of our institution (IRB-MTP\_2020\_04\_202000448). Data were collected from participants regularly followed up between January 2003 and December 2019 in our department.

Participants assessed in this study were regularly followed up for middle ear cholesteatoma and underwent  $\geq 2$  non-EPI DWI examinations, which were performed with the same 1.5T MR imaging scanner. All participants underwent canal wall up tympanoplasty. Those with incomplete removal of the cholesteatoma during the first operation or congenital cholesteatomas, or those having undergone tympanoplasty with the canal wall down technique without reconstruction or in whom residual cholesteatoma was suspected on the first MR imaging follow-up were not considered for the study.

All MRIs were performed in the neuroradiology department using a 1.5T scanner with a standard head coil. We used the following protocols: axial TSE T2-weighted sequences (TR = 4.56 seconds; TE = 0.097 seconds; section thickness = 5 mm; matrix =  $426 \times 448$ ; FOV = 230 mm; total duration 1 minute 2.4 seconds); 3D CISS sequences (TR = 0.01 seconds; TE = 0.005 seconds; section thickness = 0.7 mm; matrix =  $350 \times 448$ ; FOV = 210 mm; total duration = 6 minutes 28.2 seconds); coronal spin-echo T1-weighted sequences (TR = 0.5 seconds; TE = 0.009 seconds; section thickness = 2 mm; matrix =  $128 \times 128$ ; FOV = 190 mm; total duration = 2 minutes 25.8 seconds); and axial HASTE DWI sequences (TR = 2.8 seconds; TE = 0.122 seconds; b factor = 0, 1000 s/mm<sup>2</sup>; section thickness = 2.5 mm; matrix =  $256 \times 256$ ; FOV = 300 mm; total duration = 1 minute 8.4 seconds).

The radiologist classified the images as “suspicion” or “no suspicion” of residual cholesteatoma based on all imaging sequences acquired. The surgeon then made a decision as to whether to perform revision surgery on the basis of the imaging diagnosis and/or clinical assessment.

In the event of revision surgery, MR imaging follow-up was interrupted. If not, additional MRIs could be performed if requested by the surgeon. Because no official recommendations are available, the decision regarding the number of MRIs and the interval between any 2 was left to the surgeon’s discretion.

Data were collected and analyzed 3–12 years after the initial operation. Non-EPI DWI sequences were retrieved and anonymized. Two senior neuroradiologists, blinded to the diagnosis, retrospectively and independently evaluated all sequences and

classified them as “no residual cholesteatoma” or “residual cholesteatoma.” In cases of disagreement, both neuroradiologists performed a third review of the images until consensus was reached.

Medical charts and surgical records were analyzed; when revision surgery occurred, any residual cholesteatoma was reported. If no revision surgery was performed and the imaging showed no residual cholesteatoma, the patient was considered disease-free.

The initial localization and staging of the cholesteatoma were assessed with the STAM classification.<sup>11</sup>

### Statistical Analyses

The interobserver agreement between the 2 radiologists was evaluated using the  $\kappa$  coefficient, computed on the 29 available MR imaging examinations (second, third, fourth, and fifth MRIs). Differences in staging and initial localization between residual and no residual cases were analyzed using the Fisher exact test.

Receiver operating characteristic curves were used to determine the cutoff of the optimal follow-up duration. This cutoff was then used to optimize the sensitivity and specificity of non-EPI DWI using the Youden index. The performance associated with residual cholesteatoma detection was reported in terms of sensitivity and specificity. Each MR imaging was considered a separate event and associated with a time point. Due to the reduction in analyzed participants each time follow-up was discontinued (revision surgery or end of MR imaging follow-up), the diagnostic values of sensitivity and specificity were recalculated for every new event. Using this method, we generated sensitivity and specificity values for censored data as a function of time.

## RESULTS

### Study Population

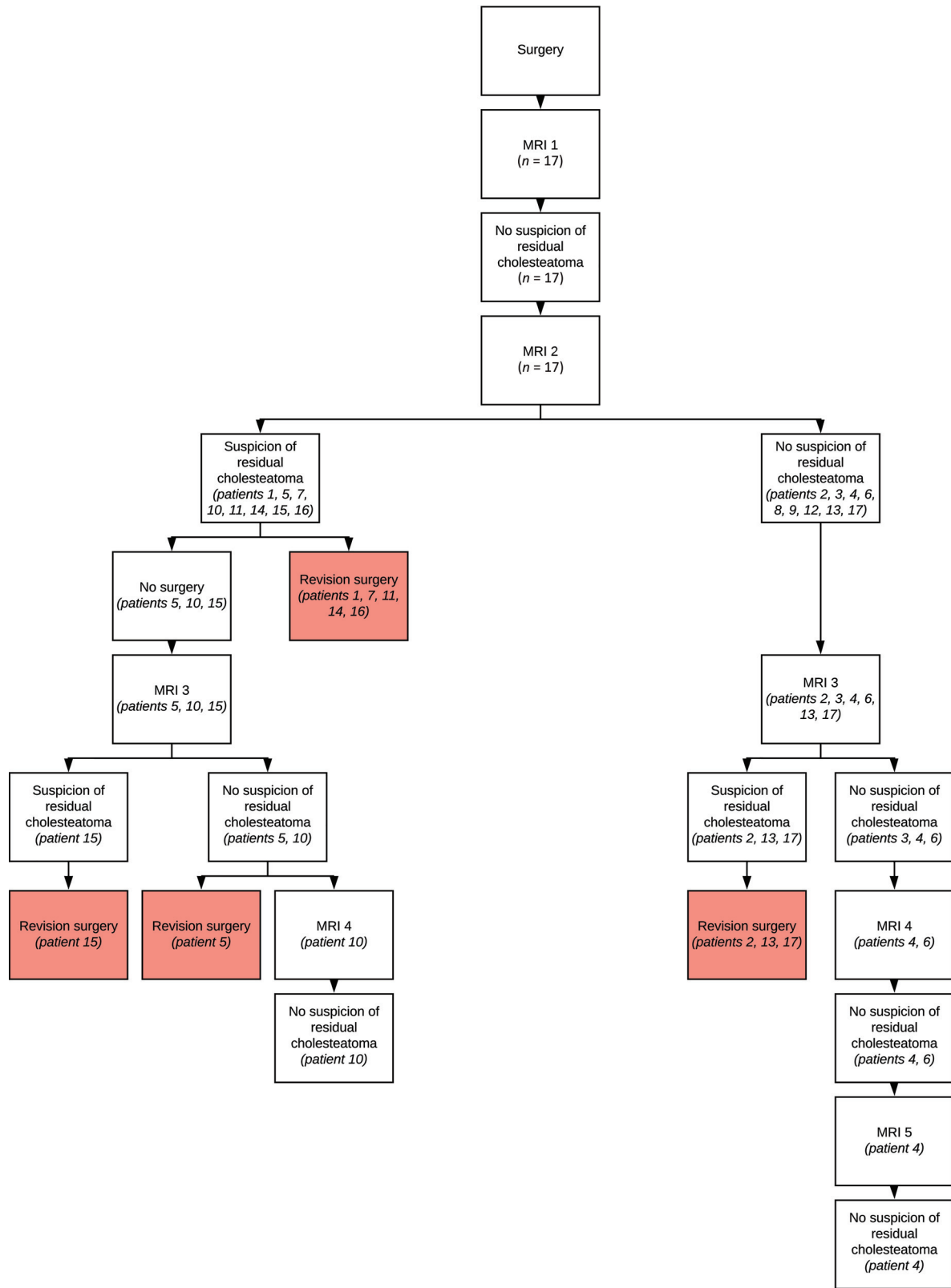
The study included 17 participants with a sex ratio of 7:10 (females/males) and a mean age of 30.2 (SD, 22.2) years (range, 6–79 years) at the time of the second MR imaging. Eight (47%) were pediatric cases. Ten (58.8%) presented with left-ear cholesteatoma, and 7 (41.2%), with right-ear cholesteatoma at the time of initial operation. The Online Supplemental Data present clinical, MR imaging, and surgical findings.

The mean time between the initial operation and the first MR imaging was 17.3 (SD, 6.8) months (range, 9–32 months). The mean time between the first and second MR imaging was 24.9 (SD, 20.2) months (range, 8–94 months). The mean time between the initial operation and the second MR imaging was 42.7 (SD, 22.9) months (range, 20–119 months).

### MR Imaging Follow-up and Revision Surgery Findings

We analyzed 47 non-EPI DWI MR images from all participants. Figure 1 presents the flowchart of participant inclusion and MR imaging follow-up. On the basis of the second MR imaging, 5 participants underwent revision surgery, 3 had residual cholesteatoma, and the other 2 participants had false-positive diagnoses. Imaging follow-up was discontinued after the second MR imaging for 3 other participants at 20, 45, and 68 months after the initial operation.

A third MR imaging was performed in 9 participants with a mean interval of 68.2 (SD, 32.6) months (range, 43–147 months)

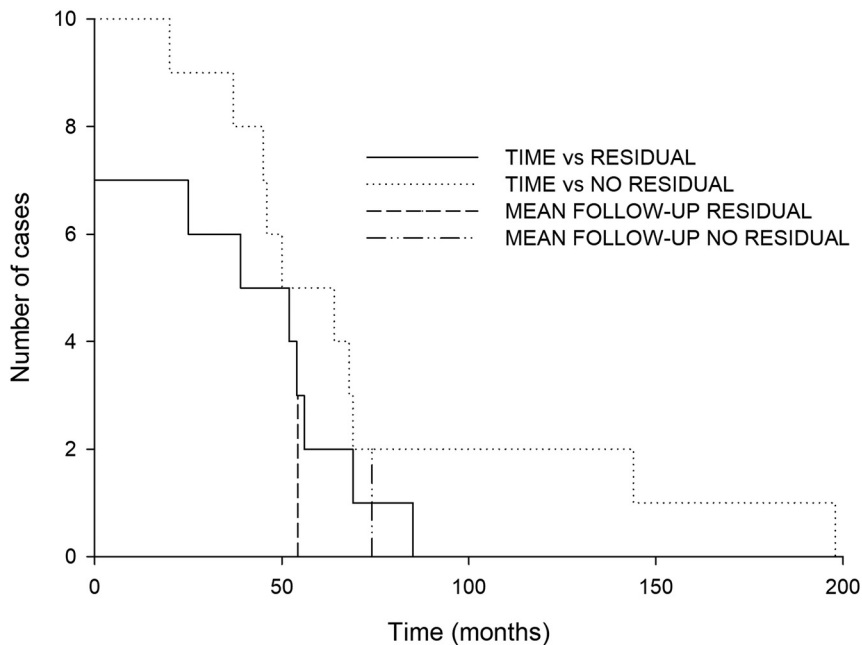


**FIG 1.** Flowchart of patient inclusion and follow-up imaging.

from the initial operation and 24.4 (SD, 12.3) months (range 11–44 months) between second and third MRIs. Five participants underwent revision surgery based on the third MR imaging. Four had residual cholesteatomas, and a fifth had an operation after

conductive hearing loss. One participant ended the follow-up after the findings of the third MR imaging were considered normal.

A fourth MR imaging was performed in the 3 remaining participants with a mean interval of 115 (SD, 72.5) months (range,



**FIG 2.** Duration of follow-up in participants with or without residual cholesteatoma. Solid and dotted lines depict participants with or without residual cholesteatoma, respectively, followed up across time in months. The mean duration of follow-up is 54.3 months in the residual cholesteatoma group and 74.1 months in the no residual cholesteatoma group.

64–198 months) from the initial operation and 36.7 (SD, 16.3) months (range, 19–51 months) between the third and fourth MRIs. No MR images from these participants indicated the need for revision surgery.

Finally, 1 participant underwent a fifth MR imaging 144 months after the initial operation and 60 months after the fourth MR imaging. No revision surgery was performed on this participant.

We detected a residual cholesteatoma in 41.1% of all participants (7/17) after the initial operation. The mean interval between the initial operation and the MR imaging classified as suspicious for residual cholesteatoma was 54.28 (SD, 19.4) months (median interval, 54 months). Among these, 43% were classified as stage I (1 location) and 57% were classified as stage II (2 locations) according to STAM classification. The location of the initial cholesteatoma was the attic in 85.7% of cases, mesotympanic in 42.8%, retrotympanic in 28.6%, and into the mastoid in 28.6% of cases. Participants with residual cholesteatomas were 14–74 years of age (mean, 32.3 years). Participants without residual cholesteatomas were 6–79 years of age (mean, 28.8 years). Follow-up duration ranged from 20 to 198 months (mean, 65.9 [SD, 43.9] months). The mean time between initial and revision surgery (when performed) was 53.8 (SD, 17.4) months (range, 28–85 months). Ten revision surgeries were performed (58.8%) for 7 residual cholesteatomas and 2 false-positives. The average follow-up duration from the initial operation to the last MR imaging was 65.9 (SD, 43.9) months (range, 20–198 months). The follow-up duration was longer in the group without a residual cholesteatoma (including false-positive cases with unnecessary surgery, 74.1 [SD, 54.7] months) than in the residual cholesteatoma group (54.3 [SD, 19.4] months) (Fig 2).

Three of 7 residual cholesteatomas were diagnosed on the second MR imaging (42.9%); the other 4 were discovered on the third MR imaging (57.1%). The residual cholesteatomas diagnosed on the second MR imaging were found 25, 39, and 52 months post-surgery. In those cases, the first MR imaging, considered to have normal findings, was performed 14, 12, and 20 months, respectively, after the initial operation. The residual cholesteatomas diagnosed during the third MR imaging were found at 54, 56, 69, and 85 months. In these cases, the second MR imaging, considered to have normal findings, was performed 29, 45, 37, and 40 months, respectively, after the initial operation. Their first MR imaging was performed 10, 24, 15, and 32 months, respectively, after the initial operation.

For the participants without identified residual cholesteatoma ( $n = 10$ ), 30% of initial cholesteatomas were classified as stage I and 70% were classified as stage II. Forty percent of the initial cholesteatomas were (fully or not) in the

attic; 80%, mesotympanic; 20%, retrotympanic; 20%, paratympanic; and 40%, located in the mastoid. No differences in stage or location were found between the residual and no residual groups ( $P > .05$ , Fisher exact test).

#### Diagnostic Value of Non-EPI DWI as a Function of Time

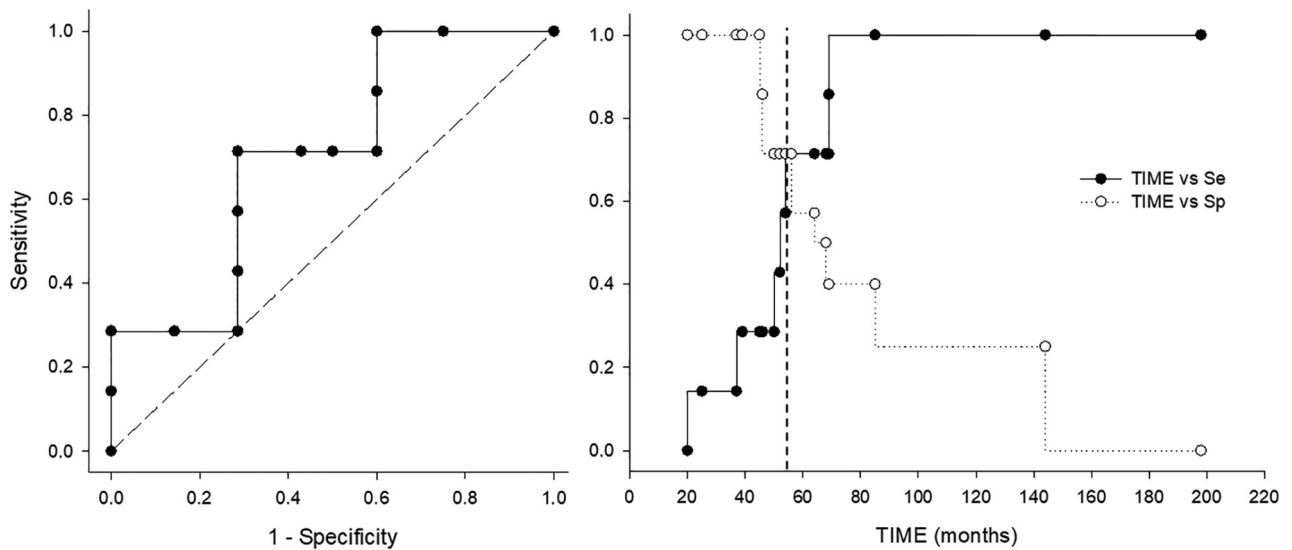
Interobserver agreement based on the evaluation of non-EPI DWI MR imaging was high between the 2 senior neuroradiologists with a  $\kappa$  of 1 (perfect agreement).

The sensitivity and specificity of MR imaging were calculated as a function of time to determine the time at which non-EPI DWI had the best diagnostic value for detecting residual cholesteatoma after a first MR imaging showing no sign of residual cholesteatoma (Fig 3). Thus, the calculation was performed from the second MR imaging, including all subsequent imaging.

The sensitivity increased from 0 to 1 by 85 months postoperatively. The specificity went from 1 for MRIs performed up to 45 months to 0 for those performed from 198 months after the operation. Analyses of receiver operating characteristic curves showed that non-EPI DWI had the best diagnostic value 56 months after the initial operation (sensitivity = 0.71, specificity = 0.71, Youden index = 0.43).

#### DISCUSSION

Our results suggest that the optimal diagnostic value of repeat non-EPI DWI (sensitivity = 0.71 and specificity = 0.71) is reached 56 months (4.7 years) after the initial operation when a first MR imaging examination performed a mean of 17.3 (SD, 6.8) months after the operation does not detect residual cholesteatoma. This recommendation is based on analysis of



**FIG 3.** Diagnostic value of non-EPI DWI as a function of time. The *left panel* shows the receiver operating characteristic curve of sensitivity according to 1-specificity. The best diagnostic values (sensitivity = 0.71, specificity = 0.71, Youden index = 0.43) are reached at 56 months postoperatively. The *right panel* shows the values of sensitivity and specificity as a function of time. Sensitivity increases from 0 to 1 by 85 months postoperatively. Specificity changes from 1 for MRIs performed up to 45 months to 0 for those performed from 198 months after the operation. Se indicates sensitivity; sp, specificity.

participants who underwent complete macroscopic removal during the first operation. A different follow-up may be relevant in cases of incomplete removal, but our study did not address this issue.

This proposal is consistent with that of Pai et al,<sup>10</sup> who reported residual cholesteatoma detection by non-EPI DWI 3.8 years after the initial operation (median, 3.7 years; range, 1.6–7.9 years) and 2.5 years after the first negative imaging findings (median, 2.0 years; range, 0.9–5.1 years). Similarly, in a cohort of 45, Steens et al<sup>12</sup> reported 8 cases of residual cholesteatoma detected a mean of 3 (SD, 1.1) years after the initial operation and 2 (SD, 1) years after the first MR imaging; 2 cases were detected after a third MR imaging. In our study, the mean time between the first and second MR imaging was 24.9 (SD, 20.2) months or 2.08 (SD, 1.68) years, and between the initial and revision operations, it was a mean of 53.8 (SD, 17.4) months or 4.5 (SD, 1.4) years.

Knowing the mean interval between the operation and detection of a residual cholesteatoma is interesting, but the question of when to start and finish performing repeat MRIs remains unsolved. Thus, we performed a longitudinal analysis of all participants' MRIs and calculated the sensitivity and specificity values to optimize the number and the time of repeat MR imaging. Indeed, our recommendation relies on sensitivity and specificity analyses that are more robust than calculating the average time of residual detection, which, by its nature, does not consider cases without residual cholesteatoma or false-positive cases.

Despite being concordant with other long-term follow-up imaging studies (Pai et al<sup>10</sup> and Steens et al<sup>12</sup>), our results ended with lower sensitivity and specificity values than most reported studies that considered non-EPI DWI performed only once shortly after the operation.

The difference between short-term studies (using 1.5T or 3T scanners) and long-term studies (1.5T for Pai et al<sup>10</sup> and Steens et

al<sup>12</sup> and our study) cannot be explained by the type of MR imaging scanner used. Indeed, Lincot et al,<sup>13</sup> in 2015, demonstrated that 1.5T and 3T scanners could be used with no implications for diagnostic accuracy during short-term follow-up. The sensitivity and specificity of non-EPI DWI sequences used alone were 90.5%–100% and 68.4%–100%, respectively, depending on the reader. Conversely and unexpectedly, Lips et al,<sup>14</sup> in 2020, concluded that the sensitivity and specificity were lower at 3T than at 1.5T for non-EPI DWI sequences, irrespective of whether additional T1- and T2-weighted sequences were used. For non-EPI DWI sequences used alone, expert readers had a sensitivity and specificity of 96% and 59% at 1.5T, and 80% and 46% at 3T, respectively.<sup>14</sup>

Thus, technical aspects cannot explain the differences in diagnostic values obtained in long-term follow-up studies, including ours, and 2 meta-analyses by Lingam et al<sup>1</sup> (26 studies including 1152 participants) and Bazzi et al<sup>2</sup> (10 studies including 141 participants), which demonstrated very high diagnostic values (sensitivity = 0.82–0.91 and specificity = 0.88–0.90). Considering that the size limit for MR imaging detection of cholesteatomas is 2 mm, One main limitation of most of these studies was the lack of systematic revision surgery to ensure that no small residual cholesteatoma was left in the middle ear but missed by imaging.

One hypothesis that could explain the differences in diagnostic values is the variable growth rates among residual cholesteatomas. In 1976, Gristwood and Venables<sup>15</sup> reported varying growth rates of residual cholesteatomas, depending on the site (epitympanic versus mastoid) and other parameters such as tubal function, vascularization, or size of initial cholesteatoma. Pai et al<sup>10</sup> reported growth rates of 0–18 mm/year, with a mean of 4 mm/year; data computed by Venail et al<sup>16</sup> showed a mean growth rate of 2.74 mm/year. Faster-growing residual cholesteatomas may be detected during early and first non-EPI DWI; hence, they explain the high diagnostic values reported in the short term while

supporting the notion that slow-growing lesions require prolonged follow-up imaging to be detected.

Our imaging strategy, like those of Pai et al<sup>10</sup> and Steens et al<sup>12</sup> (including participants for whom the first MR imaging findings were considered negative) allowed us to rule out including any residual cholesteatomas with a high growth rate. The population remaining after removing those with a fast-growing residual cholesteatoma identified on the first examination showed high rates of residual cholesteatomas (31% for Steens et al<sup>12</sup> and 41.1% in our study), even though absolute numbers were limited (12 residual cholesteatoma cases for Pai et al,<sup>10</sup> 8 cases for Steens et al,<sup>12</sup> and 7 cases in this study).

These data seem to support the need for long-term follow-up. Pai et al<sup>10</sup> and Geven et al<sup>17</sup> recommended imaging follow-up of 5 years. Because our participants were followed up with different numbers of MRIs performed at several timepoints, we were able to calculate sensitivity and specificity values according to the follow-up duration. Our receiver operating characteristic curve analysis suggests the need for follow-up for 5 years. Indeed, in our study, the best diagnostic values of non-EPI DWI occurred 4.7 years after the initial operation.

A main limitation of long-term follow-up studies, including ours, is the limited number of participants who have undergone repeat MR imaging. Another limitation of our study is the lack of systematic surgical revision, which did not allow the accurate determination of the true sensitivity of MR imaging because late cholesteatoma recurrence can occur and be missed by imaging. To reduce limitations relating to technical issues, we chose to include only those participants operated on in our tertiary care center (same surgical team) and to use only MR imaging performed on the same device at a tertiary referral center and images interpreted by the same radiologist team. While this practice effectively reduced potential technical bias, it also limited the number of participants eligible for the study. Even if the true sensitivity of non-EPI DWI cannot be calculated using such a study design, the mean follow-up in the group with no identified residual cholesteatoma (including false-positive cases with unnecessary revision surgery) was 74.1 (SD, 54.7) months (6.2 years). This duration is, thus, longer than the 5-year follow-up suggested on the basis of our analyses. It would have been interesting to compare initial localization and staging between residual and no residual groups and late and early residual disease, but our sample size was too small to address these points.

The cost of repeat MR imaging for cholesteatoma follow-up has not been considered here. Choi et al<sup>18</sup> compared second-look surgery with a single non-EPI DWI in Canada. The cost analysis favored non-EPI DWI (difference of CAD\$390.66 [95% CI, CAD\$381.52–\$399.80]) for a single MR imaging examination, but this analysis needs re-evaluating for repeat imaging assessments. As we showed, MR imaging 5 years after the initial operation provides the best diagnostic values, but the question of whether to add an intermediate MR imaging around 3 years after the operation remains. Our clinical experience was that a third MR imaging was performed around 3.5 years after the operation. The advantage is the potential to prevent excessive growth of a residual lesion between the first MR imaging and the 5-year MR imaging, but this additional MR imaging comes with an extra

cost and a risk of poor sensitivity (<0.3) in our study. Indeed, the MR imaging at 3.5 years was clearly not sufficient for optimal follow-up, and an MR imaging at 5 years was needed. Because no major complications related to residual cholesteatoma growth (labyrinthine fistula, meningitis) were observed during our prolonged follow-up study, the absolute need for an intermediate MR imaging before 5 years is questionable and deserves further investigation, including cost-utility analyses.

## CONCLUSIONS

Repeat non-EPI DWI is an effective method to detect middle ear residual cholesteatoma. Prolonged follow-up is needed to identify slowly growing lesions. On the basis of our results, we suggest performing non-EPI DWI at 18 months and 3.5 years after the initial operation. If the second non-EPI DWI shows no sign of cholesteatoma, a third and last MR imaging should be performed 5 years after the initial operation to safely exclude or identify residual tumors. Follow-up should be adapted depending on the initial localization and extent of the cholesteatoma and on the quality of the initial operation.

Disclosures: Pierre-Henri Lefevre—UNRELATED: Payment for Development of Educational Presentations: Medtronic. Frederic Venail—UNRELATED: Grants/Grants Pending: Cochlear SAS\*; Travel/Accommodations/Meeting Expenses Unrelated to Activities Listed: international and national ear, nose and throat meeting unrelated to the work submitted. \*Money paid to the institution.

## REFERENCES

1. Lingam RK, Bassett P. **A meta-analysis on the diagnostic performance of non-echoplanar diffusion-weighted imaging in detecting middle ear cholesteatoma: 10 years on.** *Otol Neurotol* 2017;38:521–28 [CrossRef Medline](#)
2. Bazzi K, Wong E, Jufas N, et al. **Diffusion-weighted magnetic resonance imaging in the detection of residual and recurrent cholesteatoma in children: a systematic review and meta-analysis.** *Int J Pediatr Otorhinolaryngol* 2019;118:90–96 [CrossRef Medline](#)
3. Lingam RK, Khatri P, Hughes J, et al. **Apparent diffusion coefficients for detection of postoperative middle ear cholesteatoma on non-echo-planar diffusion-weighted images.** *Radiology* 2013;269:504–10 [CrossRef Medline](#)
4. Khemani S, Lingam RK, Kalan A, et al. **The value of non-echo planar HASTE diffusion-weighted MR imaging in the detection, localisation and prediction of extent of postoperative cholesteatoma.** *Clin Otolaryngol* 2011;36:306–12 [CrossRef Medline](#)
5. Akkari M, Gabrillargues J, Saroul N, et al. **Contribution of magnetic resonance imaging to the diagnosis of middle ear cholesteatoma: analysis of a series of 97 cases.** *Eur Ann Otorhinolaryngol Head Neck Dis* 2014;131:153–58 [CrossRef Medline](#)
6. Gaillardin L, Lescanne E, Moriniere S, et al. **Residual cholesteatoma: prevalence and location: follow-up strategy in adults.** *Eur Ann Otorhinolaryngol Head Neck Dis* 2012;129:136–40 [CrossRef Medline](#)
7. Horn RJ, Gratama JW, van der Zaag-Loonen HJ, et al. **Negative predictive value of non-echo-planar diffusion weighted MR imaging for the detection of residual cholesteatoma done at 9 months after primary surgery is not high enough to omit second look surgery.** *Otol Neurotol* 2019;40:911–19 [CrossRef Medline](#)
8. Lecler A, Lenoir M, Peron J, et al. **Magnetic resonance imaging at one year for detection of postoperative residual cholesteatoma in children: is it too early?** *Int J Pediatr Otorhinolaryngol* 2015;79:1268–74 [CrossRef Medline](#)
9. De Foer B, Verduyck JP, Bernaerts A, et al. **Detection of postoperative residual cholesteatoma with non-echo-planar diffusion-weighted magnetic resonance imaging.** *Otol Neurotol* 2008;29:513–17 [CrossRef Medline](#)

10. Pai I, Crossley E, Lancer H, et al. **Growth and late detection of post-operative cholesteatoma on long term follow-up with diffusion weighted magnetic resonance imaging (DWI MRI): a retrospective analysis from a single UK centre.** *Otol Neurotol* 2019;40:638–44 [CrossRef Medline](#)
11. Yung M, Tono T, Olszewska E, et al. **EAONO/JOS joint consensus statements on the definitions, classification and staging of middle ear cholesteatoma.** *J Int Adv Otol* 2017;13:1–8 [CrossRef Medline](#)
12. Steens S, Venderink W, Kunst D, et al. **Repeated postoperative follow-up diffusion-weighted magnetic resonance imaging to detect residual or recurrent cholesteatoma.** *Otol Neurotol* 2016;37:356–61 [CrossRef Medline](#)
13. Lincot J, Veillon F, Riehm S, et al. **Middle ear cholesteatoma: compared diagnostic performances of two incremental MRI protocols including non-echo planar diffusion-weighted imaging acquired on 3T and 1.5T scanners.** *J Neuroradiol* 2015;42:193–201 [CrossRef Medline](#)
14. Lips LM, Nelemans PJ, Theunissen FM, et al. **The diagnostic accuracy of 1.5 T versus 3 T non-echo-planar diffusion-weighted imaging in the detection of residual or recurrent cholesteatoma in the middle ear and mastoid.** *J Neuroradiol* 2020;47:433–40 [CrossRef Medline](#)
15. Gristwood RE, Venables WN. **Growth rate and recurrence of residual epidermoid cholesteatoma after tympanoplasty.** *Clin Otolaryngol Allied Sci* 1976;1:169–82 [CrossRef Medline](#)
16. Venail F, Bonafe A, Poirrier V, et al. **Comparison of echo-planar diffusion-weighted imaging and delayed postcontrast T1-weighted MR imaging for the detection of residual cholesteatoma.** *AJNR Am J Neuroradiol* 2008;29:1363–68 [CrossRef Medline](#)
17. Geven LI, Mulder JJ, Graamans K. **Giant cholesteatoma: recommendations for follow-up.** *Skull Base* 2008;18:353–59 [CrossRef Medline](#)
18. Choi DL, Gupta MK, Rebello R, et al. **Cost-comparison analysis of diffusion weighted magnetic resonance imaging (DWMRI) versus second look surgery for the detection of residual and recurrent cholesteatoma.** *J Otolaryngol Head Neck Surg* 2019;48:58 [CrossRef Medline](#)