

Are your **MRI contrast agents** cost-effective?

Learn more about generic **Gadolinium-Based Contrast Agents**.



**FRESENIUS  
KABI**

caring for life

**AJNR**

## **Pulsatility Attenuation along the Carotid Siphon in Pseudoxanthoma Elasticum**

J.W. Bartstra, R.J. van Tuijl, P.A. de Jong, W.P.T.M. Mali, I.C. van der Schaaf, Y.M. Ruigrok, G.J.E. Rinkel, B.K. Velthuis, W. Spiering and J.J.M. Zwanenburg

This information is current as of April 19, 2024.

*AJNR Am J Neuroradiol* published online 24 September 2021

<http://www.ajnr.org/content/early/2021/09/23/ajnr.A7288>

# Pulsatility Attenuation along the Carotid Siphon in Pseudoxanthoma Elasticum

J.W. Bartstra,  R.J. van Tuijl,  P.A. de Jong, W.P.T.M. Mali,  I.C. van der Schaaf,  Y.M. Ruigrok,  G.J.E. Rinkel,  B.K. Velthuis,  W. Spiering, and  J.J.M. Zwanenburg

## ABSTRACT

**SUMMARY:** We compared velocity pulsatility, distensibility, and pulsatility attenuation along the intracranial ICA and MCA between 50 patients with pseudoxanthoma elasticum and 40 controls. Patients with pseudoxanthoma elasticum had higher pulsatility and lower distensibility at all measured locations, except for a similar distensibility at C4. The pulsatility attenuation over the siphon was similar between patients with pseudoxanthoma elasticum and controls. This finding suggests that other disease mechanisms are the main contributors to increased intracranial pulsatility in pseudoxanthoma elasticum.

**ABBREVIATIONS:** PI = pulsatility index; PXE = pseudoxanthoma elasticum; SVD = small-vessel disease; 2D-PC = 2D phase-contrast

The curved shape combined with distensibility of the carotid siphon attenuates arterial pulsatility and protects the cerebral vasculature.<sup>1,2</sup> Calcification and stiffening in the siphon may reduce pulsatility attenuation and cause increased intracranial arterial pulsatility. Arterial calcifications occur in atherosclerotic plaques in the intimal arterial wall.<sup>3</sup> Medial arterial calcifications in the medial layer and internal elastic lamina contribute to arterial stiffening.<sup>4</sup> Extracranial arterial stiffness increases intracranial pulsatility because it hampers attenuation of the pulse pressure to the microvascular bed,<sup>3</sup> but reduced attenuation along the siphon has been studied less.

Pseudoxanthoma elasticum (PXE) is a rare disorder with severe calcifications in the skin, eyes, and internal elastic lamina of the arteries of the arms, legs, and carotid siphon.<sup>5</sup> PXE results in increased arterial stiffness, peripheral arterial disease, stroke, and small-vessel disease (SVD).<sup>6,7</sup> Carotid siphon calcification is associated with increased arterial flow pulsatility, and both calcification and pulsatility are associated with SVD.

To investigate whether patients with PXE have reduced pulsatility attenuation along the carotid siphon, we compared velocity pulsatility and distensibility along the ICA and MCA and

pulsatility attenuation over the siphon between patients with PXE and controls.

## MATERIALS AND METHODS

### Data Availability

Anonymized data will be shared on reasonable request to the corresponding author.

### Participants

Fifty patients with PXE and 40 age- and sex-matched controls were included. Controls were either families or acquaintances of patients with PXE, excluding first-/second-degree relatives. Exclusion criteria were younger than 18 years of age, estimated glomerular filtration rate of  $<30$  mL/min/1.73m<sup>2</sup>, a cardiac device, or claustrophobia. The study was approved by University Medical Center Utrecht institutional review board. All participants gave written informed consent.

### MR Imaging Acquisition

All participants were scanned on a 3T MR imaging unit with a 32-channel head coil (Philips Healthcare). 2D phase-contrast (2D-PC) MR imaging with retrospective cardiac gating was acquired separately for both sides proximal to the cavernous segment (C4) and distal to the carotid siphon at the ophthalmic (C6)<sup>8</sup> and MCA M1 segment, using the following imaging parameters: FOV =  $250 \times 250$  mm<sup>2</sup>, reconstructed spatial resolution =  $0.25 \times 0.25 \times 3$  mm<sup>3</sup>, acquired temporal resolution = 64 ms, and unidirectional through-plane velocity encoding sensitivities of 100 cm/s for C4 and MCA and 150 cm/s for C6 to avoid phase wraps. The flow acquisitions provided time-resolved measurements of the blood

Received May 12, 2021; accepted after revision July 12.

From the Departments of Radiology (J.W.B., R.J.v.T., P.A.d.J., W.P.T.M.M., I.C.v.d.S., B.K.V., J.J.M.Z.), and Neurology and Neurosurgery (Y.M.R., G.J.E.R.), Rudolf Magnus Institute of Neuroscience, Utrecht, the Netherlands; and Department of Vascular Medicine (W.S.), University Medical Center Utrecht, Utrecht University, Utrecht, the Netherlands.

J.W. Bartstra and R.J. van Tuijl shared first authorship.

Please address correspondence to Rick J. van Tuijl, MSc, University Medical Center Utrecht, PO Box 85500, Heidelberglaan 100, 3584 CX Utrecht, The Netherlands; e-mail: r.j.vantuijl@umcutrecht.nl

<http://dx.doi.org/10.3174/ajnr.A7288>

**Baseline characteristics patients with PXE and controls<sup>a</sup>**

Characteristic	PXE (n = 49)	Controls (n = 40)	P Value
Age (yr)	57 (SD, 12)	58 (SD, 11)	.49
Male sex (No.) (%)	24 (49%)	20 (50%)	.92
Systolic BP (mm Hg)	136 (SD, 20)	133 (SD, 15)	.59
Diastolic BP (mm Hg)	77 (SD, 12)	79 (SD, 10)	.33
Statin use (No.) (%)	25 (51%)	5 (13%)	<.01
LDL cholesterol (mmol/L)	2.8 (SD, 0.91)	3.6 (SD, 0.83)	<.01
Hypercholesterolemia (No.) (%)	42 (86%)	37 (93%)	.31
Current smoking (No.) (%)	6 (12%)	4 (11%)	.84
Pulsatility measurements			
ICA C4 (No.)	93	79	
PI	1.12 (0.98–1.22)	0.94 (0.81–1.08)	<.01
Distensibility (mm Hg <sup>-1</sup> )	0.18 (0.16–0.24)	0.21 (0.17–0.25)	.14
Mean velocity (cm/s)	22.8 (17.9–29.5)	18.9 (15.4–23.7)	<.01
ICA C6 (No.)	70	34	
PI	0.96 (0.89–1.09)	0.83 (0.75–0.94)	<.01
Distensibility (mm Hg <sup>-1</sup> )	0.33 (0.27–0.43)	0.57 (0.45–0.63)	<.01
Mean velocity (cm/s)	32.5 (28.2–37.8)	29.7 (24.9–37.7)	.08
MCA (No.)	95	77	
PI	0.92 (0.82–1.05)	0.79 (0.67–0.87)	<.01
Distensibility (mm Hg <sup>-1</sup> )	0.30 (0.25–0.40)	0.48 (0.42–0.57)	<.01
Mean velocity (cm/s)	36.6 (32.0–42.2)	38.3 (33.8–48.7)	.05
Pulsatility attenuation			
C4 to C6	–0.09 (–0.13 to –0.06)	–0.11 (–0.16 to –0.08)	.03
C6 to MCA	–0.06 (–0.09 to –0.02)	–0.05 (–0.14–0.00)	.59
C4 to MCA	–0.16 (–0.21 to –0.11)	–0.16 (–0.24 to –0.11)	.48

**Note:**—BP indicates blood pressure; C4, cavernous ICA segment; C6, ophthalmic ICA segment; LDL, low-density lipoprotein.

<sup>a</sup> Data are means and median and interquartile range or No. (%).

flow velocity and volumetric flow rates over the cardiac cycle. Flow measurements of sufficient quality were included.<sup>1</sup>

### Data Processing

Semiautomated analysis of the 2D-PC acquisitions was performed with scanner software (software release R5.1.7; Philips Healthcare).<sup>1</sup> ROIs were automatically created with a mouse click without any manual correction. The automated ROI selection was repeated in 5 random subjects to test reproducibility. The velocity curve was obtained from mean ROI values of each cardiac phase. The minimum, maximum, and mean blood flow velocities from this curve ( $V_{\min}$ ,  $V_{\max}$ , and  $V_{\text{mean}}$ ) in centimeters/second were used to calculate the pulsatility index (PI) =  $(V_{\max} - V_{\min}) / V_{\text{mean}}$ . Arterial distensibility, defined as  $(A_{\max} - A_{\min}) / A_{\text{mean}} / \Delta P \times 100$ , was calculated from each area curve, where A indicates ROI areas and  $\Delta P$  is the systolic-diastolic pressure measured before MR imaging.<sup>2</sup> Pulsatility attenuation was calculated by subtracting the PI of the proximal from the distal segment.

### Statistical Analysis

Descriptive data were presented as mean for normal and median (interquartile range) for non-normally distributed variables and number (percentage) for categorical variables. Because PI measurements for the left and right were not significantly different, no stratification per side was performed. Differences between the PXE and control groups were tested with the Student *t* test, Mann-Whitney *U* test, or  $\chi^2$  test when appropriate. Analysis was performed in R Studio, Version 1.1.456 (<http://rstudio.org/>)

download/desktop). A *P* value < .05 was regarded as statistically significant.

## RESULTS

### Baseline

Fifty patients with PXE (57 [SD, 12] years of age, 49% men) and 40 controls (58 [SD, 11] years of age, 50% men) were enrolled between January 2017 and May 2018 (baseline characteristics are in the Table). One patient with PXE had an ophthalmic artery aneurysm and was excluded.

### Pulsatility Index, Distensibility, and Pulsatility Attenuation

Repeat automated ROI selection in 5 subjects demonstrated no changes in measurements. The PI decreased from C4 to C6 and from C6 to the MCA in both patients with PXE and controls (Table). Patients with PXE had a higher PI at all locations. Distensibility was significantly lower in PXE at C6 ( $P < .01$ ) and the MCA ( $P < .01$ ), but not at C4, where the ICA passes through the skull base (Table and Figure). In patients with PXE, pulsatility attenuation was

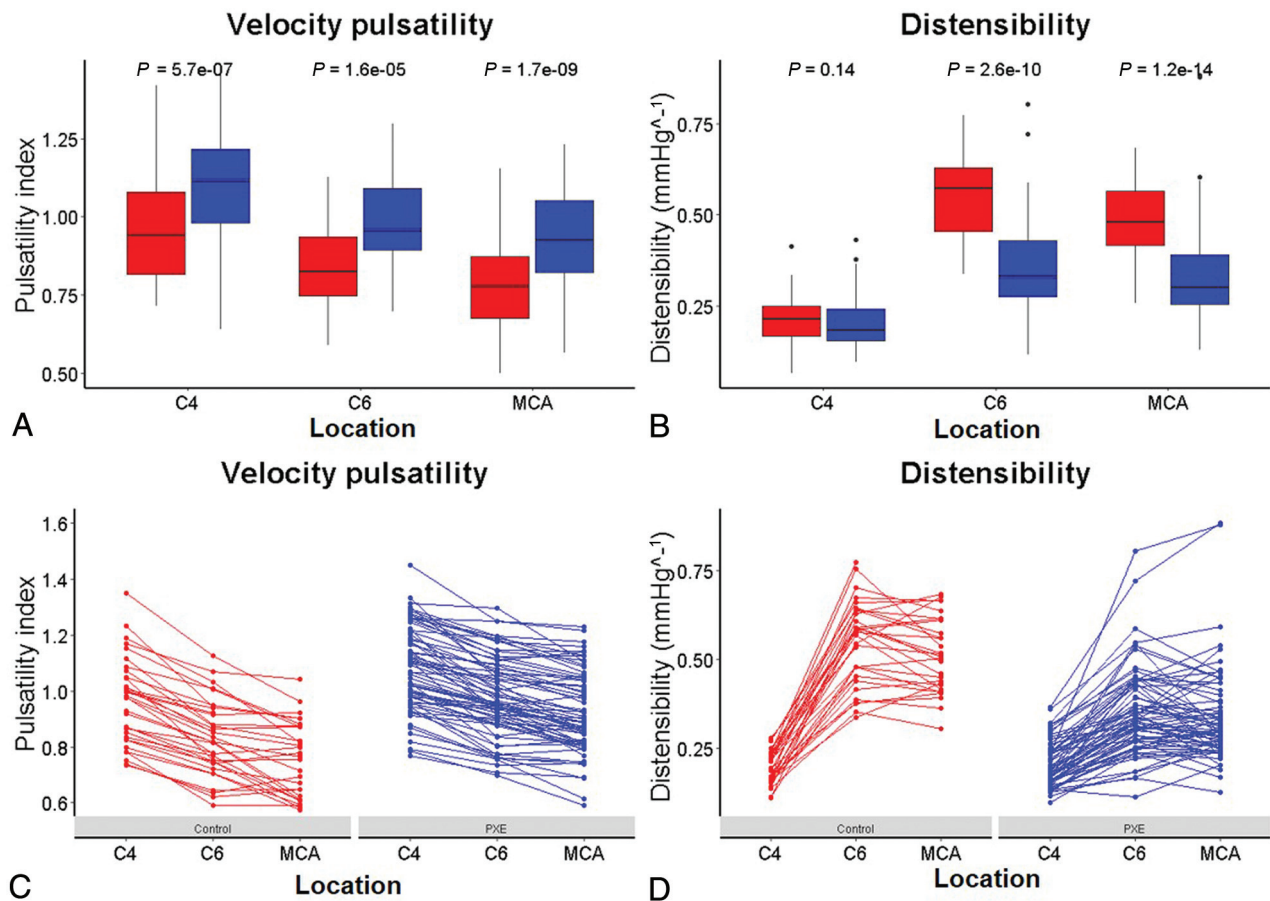
less between C4 and C6 than in controls ( $P = .03$ ), but the effective attenuation between C4 and the MCA was similar ( $P = .48$ ) (Table).

## DISCUSSION

This study shows that the siphon seems to function normally in PXE. Although patients with PXE have a higher PI and lower distensibility, pulsatility attenuation between C4 and MCA was similar compared with controls.

The current finding is different from that in patients with PXE with SVD, in whom pulsatility increased over the carotid siphon compared with a decrease in controls.<sup>9</sup> Although both small studies, these findings suggest that the hemodynamics in patients with SVD are not a representative model for the PXE phenotype. This possibility may be because patients with SVD have combined atherosclerotic intimal disease and medial arterial calcifications, whereas patients with PXE have relatively isolated medial arterial calcifications.<sup>6</sup>

Velocity pulsatility is affected by upstream arterial elasticity and downstream vascular or microvascular resistance.<sup>10</sup> Other factors include age, sex, and local constraints to arterial distensibility, such as the bony carotid canal and calcified lesions.<sup>1,11</sup> The distensibility proximal to the cavernous segment (C4) is affected by the skull base; therefore, no conclusion can be drawn regarding the distensibility or stiffness of the artery at this location. Variation in the configuration of the circle of Willis between C6 and the MCA may also affect pulsatility attenuation and blood flow.<sup>12</sup>



**FIGURE.** PI and distensibility in controls (red) and patients with PXE (blue). Differences in PI (A) and distensibility (B) in controls and patients with PXE at different locations (2 ICA segments and the MCA). Lower images show spaghetti plots of PI (C) and distensibility (D) to visualize consistency in behavior for the individual measurements.

A strong point is the relatively high number of patients for a rare disease such as PXE. A limitation is the high drop-out rate of measurements in the diverging C6 segments due to planning difficulties; however, the PI values are in the same range as described previously.<sup>1</sup> The order of the 2D-PC scans was the same for all patients. Although physiologic variations may occur during scanning (eg, blood pressure and heart rate fluctuation), they would be similar for both groups. We observed a similar pattern along the ICA in a study using 4D-phase conventional angiography, which does not have this physiologic variation.

Statin use is associated with increased calcification of atherosclerotic plaques in the coronary and carotid arteries.<sup>13</sup> Although the statin effect on medial artery calcifications in patients with PXE is unknown, we cannot exclude a possible role of statins in arterial calcification.<sup>9</sup>

### CONCLUSIONS

Despite lower distensibility and higher pulsatility in patients with PXE, there was no overall difference in pulsatility attenuation between patients with PXE and controls. This finding suggests that extracranial calcification and stiffness may contribute more to increased intracranial arterial pulsatility in PXE than carotid siphon dysfunction.

Disclosure forms provided by the authors are available with the full text and PDF of this article at [www.ajnr.org](http://www.ajnr.org).

### REFERENCES

- van Tuijl RJ, Ruigrok YM, Velthuis BK, et al. **Velocity pulsatility and arterial distensibility along the internal carotid artery.** *J Am Heart Assoc* 2020;9:e016883 [CrossRef Medline](#)
- O'Rourke MF, Staessen JA, Vlachopoulos C, et al. **Clinical applications of arterial stiffness; definitions and reference values.** *Am J Hypertens* 2002;15:426–44 [CrossRef Medline](#)
- Bartstra JW, van den Beukel TC, Van Hecke W, et al. **Intracranial arterial calcification: prevalence, risk factors, and consequences—JACC Review Topic of the Week.** *J Am Coll Cardiol* 2020;76:1595–1604 [CrossRef Medline](#)
- Lanzer P, Boehm M, Sorribas V, et al. **Medial vascular calcification revisited: review and perspectives.** *Eur Heart J* 2014;35:1515–25 [CrossRef Medline](#)
- Plomp AS, Toonstra J, Bergen AA, et al. **Proposal for updating the pseudoxanthoma elasticum classification system and a review of the clinical findings.** *Am J Med Genet A* 2010;152A:1049–58 [CrossRef Medline](#)
- Vos A, Kranenburg G, de Jong PA, et al. **The amount of calcifications in pseudoxanthoma elasticum patients is underestimated in computed tomographic imaging; a post-mortem correlation of histological and computed tomographic findings in two cases.** *Insights Imaging* 2018;9:493–98 [CrossRef Medline](#)
- Kauw F, Kranenburg G, Kappelle LJ, et al. **Cerebral disease in a nationwide Dutch pseudoxanthoma elasticum cohort with a**

- systematic review of the literature. *J Neurol Sci* 2017;373:167–72 [CrossRef Medline](#)
8. Bouthillier A, Van Loveren HR, Keller JT. **Segments of the internal carotid artery: a new classification.** *Neurosurgery* 1996;38:425–33 [CrossRef Medline](#)
  9. van Tuijl RJ, Ruigrok YM, Geurts LJ, et al. **Does the internal carotid artery attenuate blood-flow pulsatility in small vessel disease? A 7T 4D-flow MRI study.** In: *Proceedings of the Annual Meeting & Exhibition of the International Society for Magnetic Resonance in Medicine and the Society for MR Radiographers & Technologists*, May 15–20, 2021; Virtual. Abstract No. 2930
  10. Mitchell GF, Van Buchem MA, Sigurdsson S, et al. **Arterial stiffness, pressure and flow pulsatility and brain structure and function: the Age, Gene/Environment Susceptibility-Reykjavik Study.** *Brain* 2011;134:3398–3407 [CrossRef Medline](#)
  11. Lefferts WK, DeBlois JP, Augustine JA, et al. **Age, sex, and the vascular contributors to cerebral pulsatility and pulsatile damping.** *J Appl Physiol* 2020;129:1092–1101 [CrossRef Medline](#)
  12. Vrselja Z, Brkic H, Curic G. **Penetrating arteries of the cerebral white matter: the importance of vascular territories of delivering arteries and completeness of circle of Willis.** *Int J Stroke* 2016;11:NP36–37 [CrossRef Medline](#)
  13. Mujaj B, Bos D, Selwaness M, et al. **Statin use is associated with carotid plaque composition: the Rotterdam Study.** *Int J Cardiol* 2018;260:213–18 [CrossRef Medline](#)