

Are your **MRI contrast agents** cost-effective?

Learn more about generic **Gadolinium-Based Contrast Agents**.



**FRESENIUS  
KABI**

caring for life

**AJNR**

**Fine, Vascular Network Formation in  
Patients with Vein of Galen Aneurysmal  
Malformation**

T. Shigematsu, M.J. Bazil, J.T. Fifi and A. Berenstein

*AJNR Am J Neuroradiol* published online 22 September  
2022

<http://www.ajnr.org/content/early/2022/09/22/ajnr.A7649>

This information is current as  
of April 18, 2024.

# Fine, Vascular Network Formation in Patients with Vein of Galen Aneurysmal Malformation

 T. Shigematsu,  M.J. Bazil,  J.T. Fifi, and  A. Berenstein



## ABSTRACT

**BACKGROUND AND PURPOSE:** A vein of Galen aneurysmal malformation is known to present with recruitment of dural feeders and, in our cohort, a fine, vascular network formation. The vessels we have observed differ from dural vascular recruitment in that they produce a hairlike, collateral network of vessels. We reviewed treatment courses of vein of Galen aneurysmal malformation treatments in a series of 36 cases that displayed a fine, vascular network formation.

**MATERIALS AND METHODS:** We retrospectively analyzed 36 cases of vein of Galen aneurysmal malformation, including tectal/thalamic AVMs, treated at our center from January 2004 to September 2021, and reviewed fine, vascular network formations in the subarachnoid space and subependymal zone alongside the vein of Galen aneurysmal malformation.

**RESULTS:** Patients at first endovascular treatment ranged from neonates to 157 months (median age, 4.3 months). Patients with preinterventional fine, vascular network formations were significantly older at the initial angiogram than patients with postinterventional fine, vascular network formations ( $P < .05$ ). On average, for 20 control choroidal/mural vein of Galen aneurysmal malformations whose treatment course had been completed and in which no plexiform network was visualized, a mean of 2.63 (SD, 1.64) treatments were required to achieve a radiographic cure. For the 36 choroidal/mural vein of Galen aneurysmal malformations whose treatment course had been completed and in which a fine, vascular network formation was visualized, a mean of 5.94 (SD, 2.73) treatments were required to achieve a radiographic cure ( $P < .01$ ).

**CONCLUSIONS:** Development of a fine, vascular network formation is an acquired and reversible phenomenon that differs from typical dural vessel recruitment, given the hairlike nature of the network and its rapid onset postinterventionally. It typically resolves after completion of treatment, and this resolution correlates with closure of the vein. We recommend that neurointerventionalists avoid delays in treatment wherever possible to reduce the likelihood of a fine, vascular network formation.

**ABBREVIATIONS:** FVN = fine, vascular network; FVNF = fine, vascular network formation; SAS = subarachnoid space; SEZ = subependymal zone; TAE = transarterial embolization; TVE = transvenous embolization; VGAM = vein of Galen aneurysmal malformation; VOG = vein of Galen

Vein of Galen aneurysmal malformation (VGAM) occurs in early embryonic development and accounts for a minor fraction of all vascular malformations, but a far greater portion of neonatal and pediatric vascular malformations.<sup>1-3</sup> A VGAM develops between 6 and 11 weeks of gestation. While most VGAMs are diagnosed antenatally or as neonates, some patients survive to adulthood relatively asymptomatic and present with hemorrhage or other manifestations.<sup>4-8</sup> VGAMs entail a dilated vein of Galen


(VOG), but the true fistula occurs between the persistent prosencephalic vein of Markowski (the mature VOG precursor) and the arterial limbic system (pericallosal arcade and anterior-posterior choroidal arteries).

A VGAM is characterized as either choroidal and mural.<sup>9-11</sup> Choroidal VGAMs are more common in the neonatal period and are more complex, with a larger number of high-flow fistulas; in our experience, they are more likely to produce medically untreatable, high-cardiac-output failure. Additionally, Lasjaunias et al<sup>11</sup> reported that a choroidal-type VGAM “is encountered in most neonates with low clinical scores.” It is supplied by numerous feeder vessels from the limbic system (pericallosal arcade, choroidal arteries, and occasionally thalamoperforating/transmesencephalic arteries).<sup>12</sup> These vessels mostly converge at the anterior portion of the median prosencephalic vein. Mural VGAMs contain fistulas at the inferolateral margin in the wall of the median prosencephalic

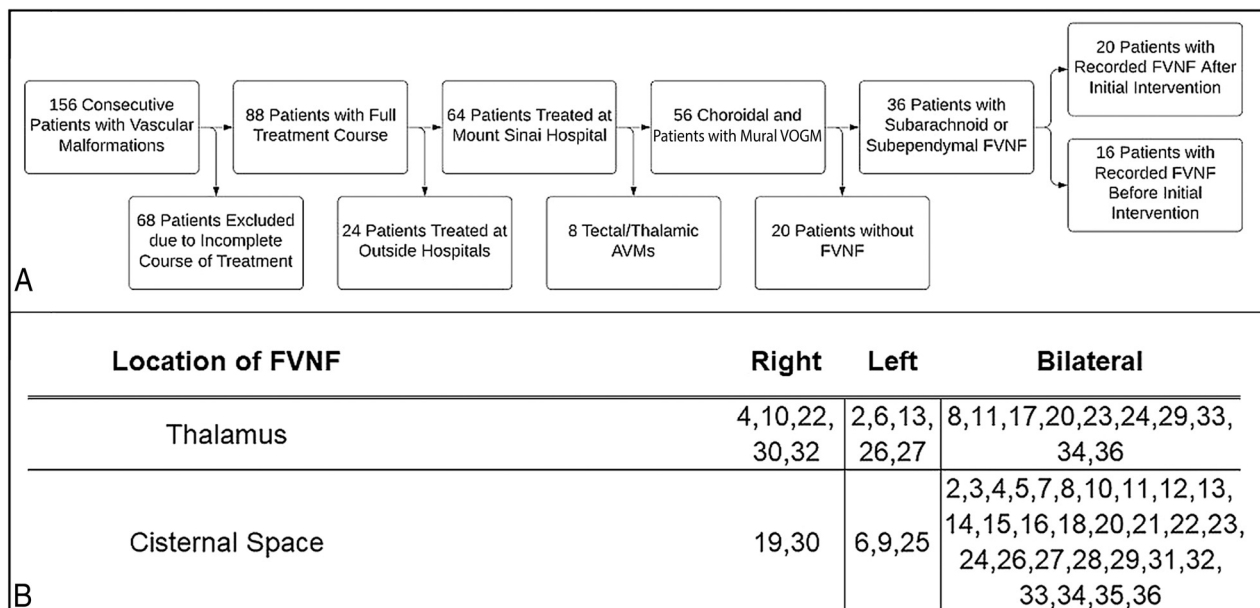
Received March 30, 2022; accepted after revision July 27.

From the Departments of Neurosurgery (T.S., M.J.B., J.T.F., A.B.) and Neurology (J.T.F.), Icahn School of Medicine at Mount Sinai, New York, New York.

Please address correspondence to Maximilian J. Bazil, BS, Icahn School of Medicine at Mount Sinai, 1 Gustave Levy Place, Annenberg 20-225, New York, NY 10029; e-mail: maximilian.bazil@mountsinai.org; @SciMaximilian

 Indicates article with online supplemental data.

<http://dx.doi.org/10.3174/ajnr.A7649>



**FIG 1.** Patient inclusion flow chart and FVNF geography. Patients were considered if they presented to our practice with an AVM between January 2004 and August 2021. Exclusion criteria included incomplete courses of treatment, treatment at centers outside our practice, tectal/thalamic AVM, or no observable FVNF. A, An FVNF was generalized as being present in either the thalamus, the cisternal space surrounding the VOG, or both with a description of laterality (B). VOGM indicates vein of galen malformation.

vein.<sup>5</sup> Mural VGAMs manifest later in infancy as macrocephaly, hydrocephalus, or delayed cognitive development (especially if associated with venous occlusions/thrombosis). A smaller number of feeders and greater outflow obstruction has often led to a more drastic dilation of the median prosencephalic vein in our experience. Cardiac failure is milder than in the choroidal subtype, and cardiomegaly may be asymptomatic.<sup>9,11</sup>

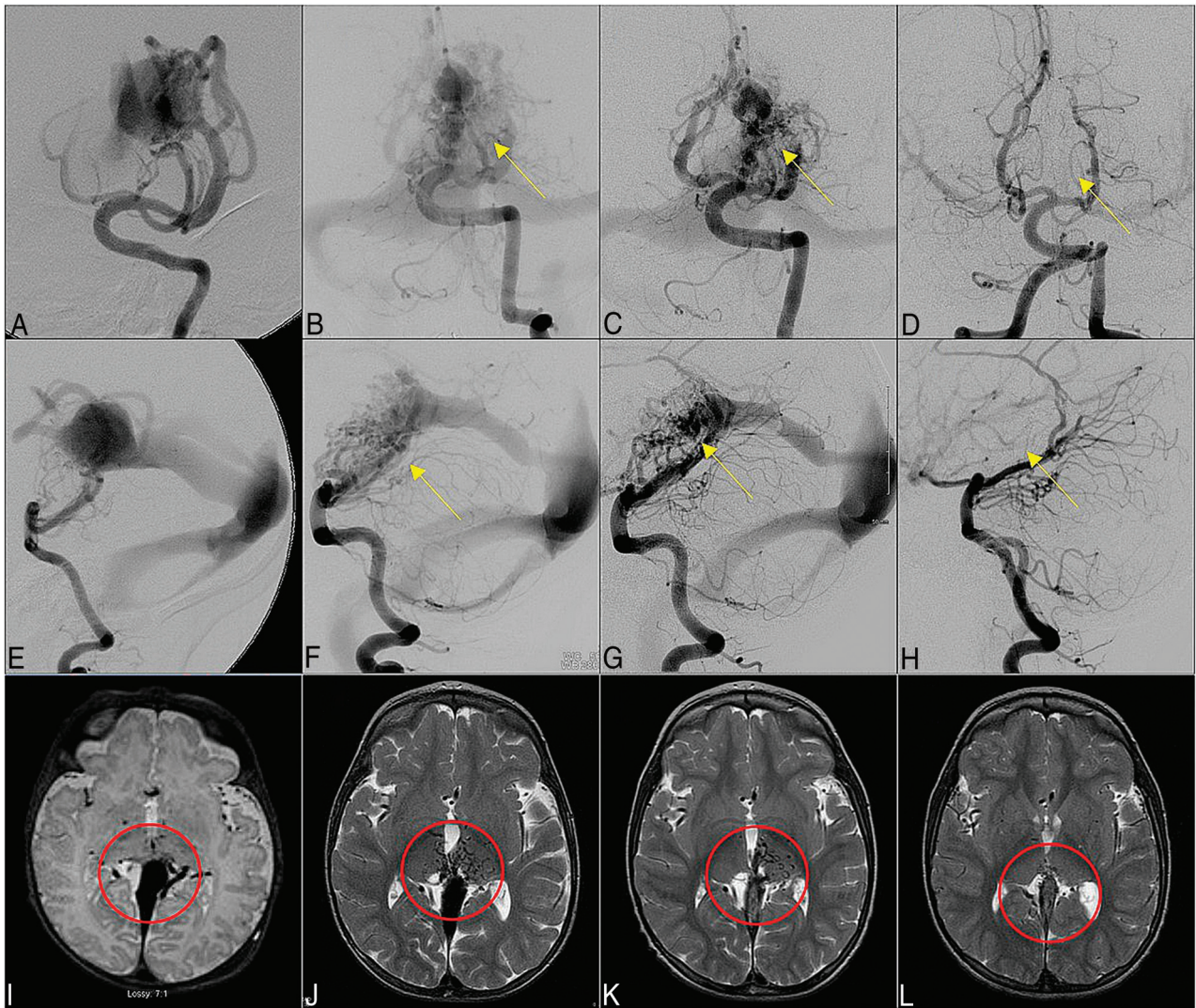
Endovascular embolization is a criterion standard treatment for VGAM.<sup>2,13-16</sup> Embolization is generally staged during several sessions. Embolization aims to safely reduce the risk of cardiac failure, venous hypertension, and hydrocephalus by closing AVFs at the arteriovenous junction, contributing to the lesion. If untreated or if arterial feeders are closed without closing the venous shunt, dramatic remodeling can occur, such as the formation of a “fine,” vascular network that reaches the arteriovenous shunts, which further supply the lesion. This finding has been noted as recruitment of dural feeders and a general, collateral network in other publications.<sup>17-21</sup> We describe a dynamic progression of feeders in the subependymal zone (SEZ) and the subarachnoid space (SAS) as a reversible, physiologic phenomenon dependent on flow demand, low venous pressure, and/or tissue ischemia.

A previous study from our practice assessed dural recruitment and contribution to VGAM fistulas.<sup>22</sup> We built on these findings with a further analysis of a larger cohort to assess a fine, vascular network formation (FVNF) in the SAS/SEZ. The vessels we have observed accompanying initial imaging or arising with time in cases of a VGAM differ from dural recruitment in that they produce a hairlike, collateral network of vessels. We reviewed treatment courses of patients with VGAMs in a series of 36 cases that had FVNF shunting into the lesion. Some of these cases presented with an FVNF in pretreatment imaging. In these cases, the FVNF may cause confusion by resembling a “true” thalamic AVM

(Online Supplemental Data). In some cases, initial imaging in the neonate period shows high-flow AVFs; then at 3-month follow-up, it shows an FVNF. We also observed this phenomenon after coil embolization of feeders that failed to close the AVF and on follow-up after the primary stage of embolization with liquid embolic agents (*n*-BCA), with incomplete closure of these AVFs. We have seen regression of the FVNF after proper closure of the arteriovenous shunt without embolization of the FVNF itself. This represents a delayed anatomic change related to the hemodynamic demands of the high flow. We discuss the significance of these observations, their influence on the treatment paradigm our practice uses for incidences of VGAMs with visible FVNFs, the various presentations that our practice has encountered, the locations of FVNF feeders, and correlations with resolution of the VGAM and FVNF therein.

## MATERIALS AND METHODS

This study was approved by the appropriate institutional review board. All imaging was reviewed by neuroendovascular surgery attending physicians (T.S., J.T.F., A.B.). We retrospectively analyzed 156 consecutive cases of all VGAMs, including tectal/thalamic AVMs, treated at our center from January 2004 to September 2021 (Fig 1A). We selected patients whose treatment course was completed and ended in complete or near-complete occlusion (>95%) for a total of 88 patients. We included only patients whose treatment course and imaging series were complete, to demonstrate the difference between closure of the malformation and amelioration of the FVNF. Of these, we extracted 64 cases whose complete treatment course was performed at our practice rather than at multiple institutions. We defined tectal or thalamic AVMs as those without obvious large feeders or fistulas (which often resemble but are distinctly not a VGAM) to ensure



**FIG 2.** Angiogram. Anterior-posterior (A–D) and lateral (E–H) views of the angiogram and T2-weighted MR imaging (I–L) of case 4. We show a progressive diminution of the FVNF at the thalamus and quadrigeminal cistern (B–D, F and G, J–L) observed after initial treatment (A, E, I). This reduction was achieved through staged embolization of feeder vessels to the VGAM from 4.2 to 10 to 20 to 40 months. The *yellow arrows* indicate location of FVNF on AP and Lateral view of cerebral angiography sections. The *red circle* indicates the location of FVNF on axial MRI plane.

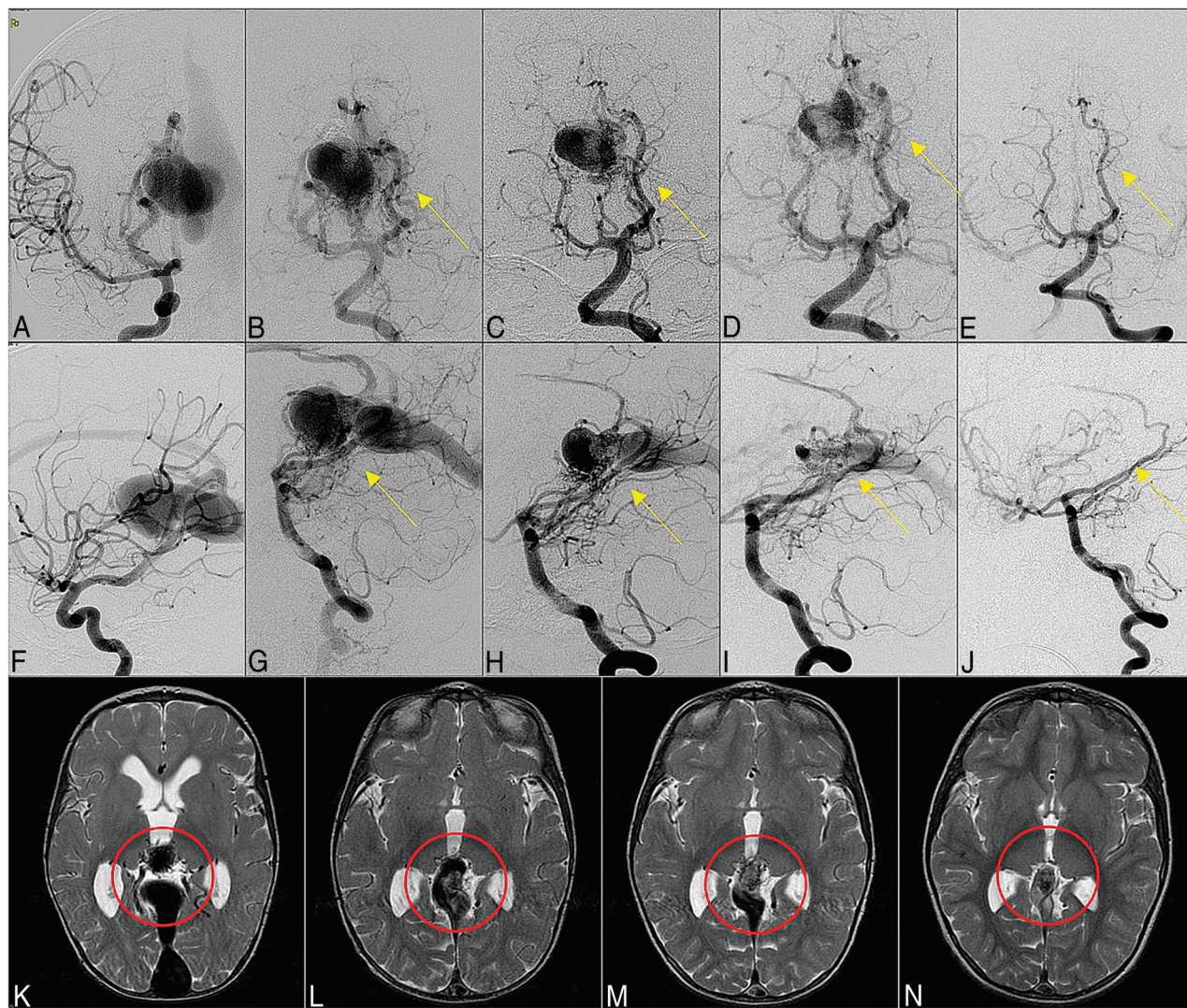
that no VGAMs were excluded. We excluded tectal/thalamic AVMs for a total of 56 choroidal or mural-type VGAMs. We gathered information from clinical case records and MR imaging/angiography on presentation and during follow-up. We recorded patient demographics, presentation, and the patient’s timeline to cure. MR imaging was used to identify anatomic locations of the FVNF. A FVNF was defined as the hairlike, hypervascular, collateral network around the VGAM on angiography and T2 MR imaging. The findings were analyzed to aid discussion of the FVNF in the SAS/SEZ alongside the VGAM.

## RESULTS

Among the 56 cases selected for detailed review, we identified 36 patients with SAS/SEZ FVNFs (Fig 1). We present 36 cases of VGAMs that we evaluated on the basis of the FVNF, a classification, treatment strategy, anatomic location, patient demographics, and procedure quantity required to achieve complete obliteration of the malformation.

### Overall FVNF Cohort

Ages at the time of the first endovascular treatment ranged from neonate to 157 months (mean age, 12.1 months; median age, 4.3 months). In 16 patients (44.4%), the vascular network was identified on the initial angiogram and drained into the VOG (Figs 2A and 3A). In 20 patients (55.6%), the FVNF was observed after the initial angiogram (Fig 4A, Online Supplemental Data). The cohort of patients with FVNFs before intervention was significantly older at the initial angiogram compared with the patients who developed these networks after  $\geq 1$  session of endovascular embolization (mean, 12 [SD, 40.1] months versus 4.0 [SD, 5.4] months;  $P < .05$ ). We compared the 20 VGAMs for which no FVNF had been visualized (Fig 1) with our FVNF cohort on the basis of the treatment number. On average, for the 20 choroidal/mural VGAMs whose treatment course had been completed and in which no plexiform network was visualized, a mean of 2.63 (SD, 1.64) treatments were required to achieve a radiographic cure. For the 36 choroidal/mural VGAMs whose treatment course had been completed and in which



**FIG 3.** Angiogram. Anterior-posterior (A–E) and lateral (F–J) views of the angiogram and T2-weighted MR imaging (K–N) of case 23. We show a progressive diminution of the FVNF bilaterally at the thalamus with a bias for the right side (B–E, G–J, K–M) observed after initial treatment (A and F). This reduction was achieved through staged embolization of feeder vessels to the VGAM staged from 0.5 to 3 to 20 to 72 months.

an FVNF was visualized, a mean of 5.94 (SD, 2.73) treatments were required to achieve a radiographic cure ( $P < .01$ ).

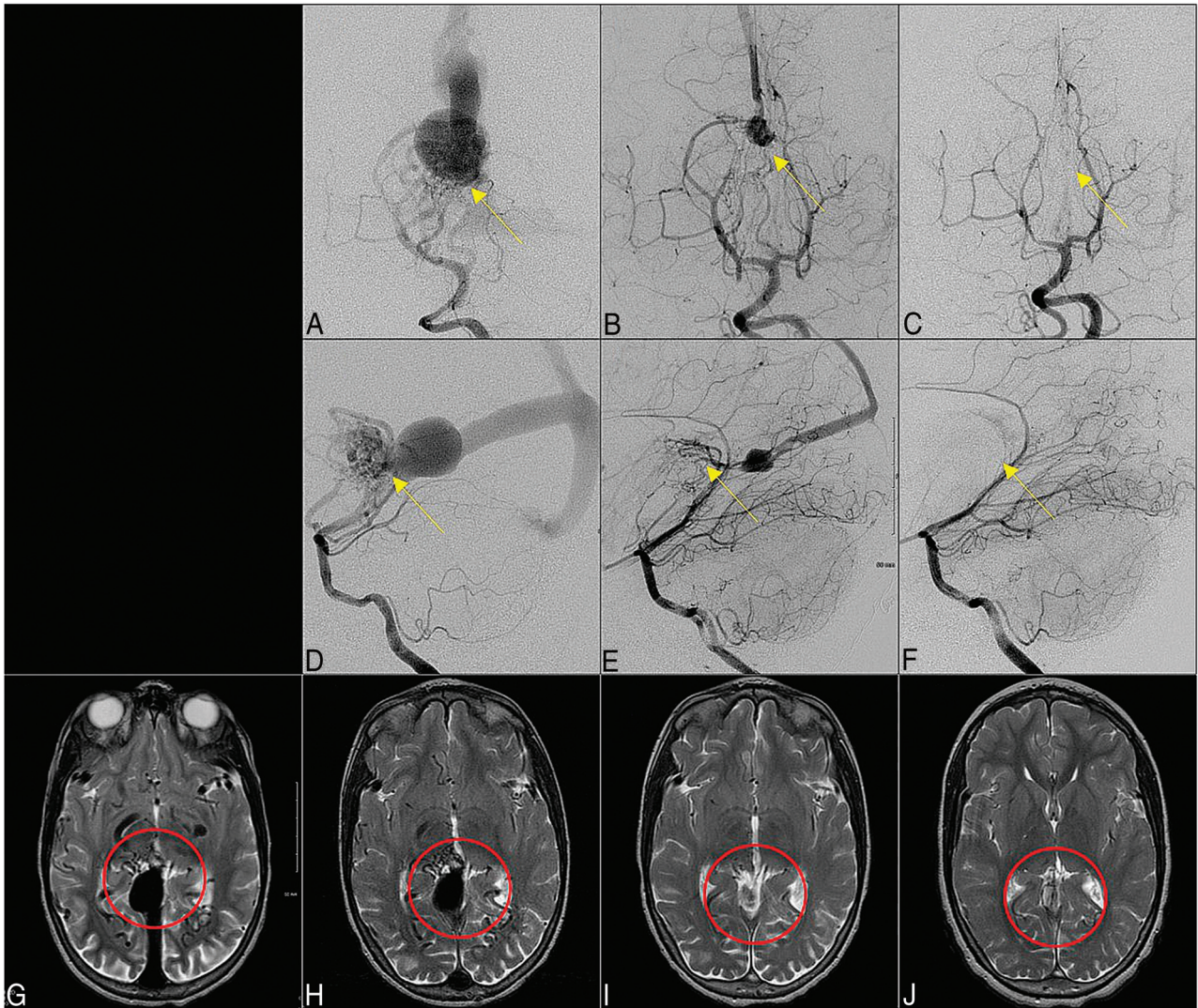
Patients were categorized into left, right, or bilateral subarachnoid/thalamic fine, vascular networks (FVNs) (Fig 1B). The FVNF was localized to either the left, right, or bilateral thalamus in 2 cases, the cisternal space surrounding the VOG in 16 cases, and both for 18 cases. We also noted 3 patterns of FVN expansion/regression during the treatment course of our cohort: 1) progressive decrease in the FVNF after initial presentation (20/36; 55.56%), 2) an original increase in the FVNF after initial presentation followed by progressive decrease (7/36; 19.44%), and 3) cycling of increases and decreases in the FVNF after initial presentation followed by eventual cure (9/36; 25%).

#### Demonstrative Cases

Subject 4, who was first imaged via cerebral angiography at 4.2 months and was found to have a mural VGAM, underwent staged embolization therapy (Fig 2). No FVNF was initially

observed around the dilated VOG (Fig 2A, -E, -I). Six months following this initial imaging and subsequent embolization, we discovered an obvious, novel FVN in the right thalamus and quadrigeminal cistern (Fig 2B, -F, -J). We were able to successfully regress this FVN through staged, transarterial embolization, and we observed continuing regression at the 19-month follow-up (Fig 2C, -G, -K). After complete obliteration of the fistulas dilating the VOG (cured), we no longer found visible FVNs as evidenced by images obtained at a 40-month follow-up (Fig 2D, -H, -L).

Subject 23, initially imaged at 16.4 months and found to have a choroidal VGAM, presented with an observable FVNF on the initial imaging series (Fig 3A, -F, -K). On the angiography/MR imaging at 3 months (Fig 3B, -C, -G, -H, -L) and 15 months (Fig 3D, -I, -M) after the first procedure, during the staged embolization that followed, the FVN receded little by little. After the complete obliteration of the VGAM had been achieved, no FVN was seen at the final follow-up at 6 years of age (Fig 3E, -J, -N).



**FIG 4.** Angiogram. Anterior-posterior (A–C) and lateral (D–F) views of the angiogram and T2-weighted MR imaging (G–J) of case 22. We show an up-regulation (H) and waning (B and C, E and F, I and J) of a plexiform network centered around the right hypothalamus and quadrigeminal cistern. The FVNF observed at 4 months post-initial consultation was rectified with staged embolization and obliterated by the 6-year follow-up (C, F, J).

Subject 22 presented to our practice with a choroidal VGAM and a nascent FVNF on initial screening (Fig 4G). This patient presented to our practice at 5 years of age with an FVNF localized to the posterior right hypothalamus and quadrigeminal cistern. The diagnostic angiogram and MR imaging that preceded the initial embolization revealed an FVNF. The first session of embolization treatment was planned for only 4 months following the original consultation, yet the imaging performed on arrival to the angi-suite revealed an up-regulation of the FVNF (Fig 4A, -D, -H). Fortunately, it seemed that the observed FVNF regressed after 2 stages of transarterial embolization at 10 months (Fig 4B, -E, -I) and was completely absent after total occlusion of the VGAM fistulas (Fig 4C, 4F, 4J) at 6 years post-initial imaging.

Subject 30 presented to our practice as a neonate, imaged via CT 1 day postnatal, with a choroidal VGAM without observable FVNF (Online Supplemental Data). At 5 months of age, after a single embolization, we identified an FVNF in the right thalamus and SAS (Online Supplemental Data). After 4 embolization treatments,

we found an initial regression of the plexiform network (Online Supplemental Data), which had abated entirely by the tenth treatment, at which point closure of the vein had been achieved (Online Supplemental Data).

## DISCUSSION

### Summary of Findings

Most of our cohort had FVNFs identified on a follow-up angiogram following a stage or multiple stages of embolization therapy. Those who presented with an FVNF at the initial angiography were significantly older at presentation than those whose FVNF was identified during a follow-up angiography. Even after removal of a large outlier (case 31) from the initial FVNF presentation group, we still observed a significantly higher mean age at presentation compared with the postinterventional group. We reasoned that this finding may be due to the “secondary” nature of the FVNF. Case 31 experienced a delay in treatment until just older than 13 years of age because the VGAM diagnosis occurred in a

work-up to determine the cause of headaches. This was the first of our findings that suggested that one should not delay treatment, particularly considering the greater treatment burden identified in the cohort with FVNF at initial presentation. The importance of this observation can be seen in cases 4 and 30 (Fig 2 and Online Supplemental Data) in which the MR imaging/MRA in the neonatal period clearly showed an AVF angioarchitecture, whereas the MR imaging and angiography at 6 and 5 months of age, respectively, clearly showed the acquired FVNF in the thalamic region. We found that those with an FVNF required more treatment to achieve cure than those without an FVNF. Unsurprisingly, a significant association was observed between the choroidal VGAM subtype and presentation of the FVNF relative to a mural VGAM (4/14 mural versus 32/42 choroidal;  $P < .01$ ). The anatomic locations of the observed FVNFs were mainly centered around the thalamus, surrounding the SAS and/or the quadrigeminal cistern; they were usually attached or very close to the dilated the venous sac of the VOG.

### **VGAM Treatments**

A FVNF poses a number of challenges to diagnosis and treatment of VGAMs, specifically, due to the difficulty of differentiating a tectal/thalamic or traditional VGAM surrounded by an FVN (Online Supplemental Data). On identification of an FVNF, our strategy is still to embolize the fistulous connections where feeders communicate with the vein. Focus is placed on penetrating the embolic material through to the vein to ensure closure of the fistula; occasionally, multiple fistulas may be targeted through 1 injection rather than each individual abnormal feeder vessel. The ideal strategy in our practice is cannulation of the primary feeder of the malformation, as close to the fistula as possible, and injection of highly concentrated *n*-BCA glue (70%–90%). After multiple rounds of staged embolization, remaining feeders become considerably less dilated and are difficult to distinguish from the observed FVNF. In this pattern, we use low-concentrate *n*-BCA (40%–50%) from an identifiable, proximal feeder and occlude the venous component of the fistula. SEZ/SAS FVNFs cause no symptoms in our patients; subsequently, we describe a clinical focus on embolization of major feeders rather than FVNFs. Most important, the expansion of the FVNF after beginning staged transarterial embolization (TAE) leaves only transvenous embolization (TVE) or TAE through the fine vasculature as endovascular treatment options. These are both technically difficult options and, in areas such as the thalamus, carry a higher risk of stroke. While our practice has begun to favor a TVE approach using the Chapot pressure cooker technique after multiple rounds of TAE, a large FVNF can lead us to decide against this otherwise effective approach due to the possible increased risk of hemorrhage.<sup>23</sup> Indeed, a member of our TVE cohort with extensive FVNFs at the time of treatment experienced a hemorrhage in the SAS surrounding the malformation adjacent to the FVNF (Online Supplemental Data).

### **FVNF and Shunt Formation**

Members of our research group published a case series on dural arteriovenous shunt formation secondary to VGAM.<sup>22</sup> They noted that the FVNF occurred in 26/87 patients in 3 distinct patterns: 1) feeders arising predominantly from pial vessels, 2) feeders arising from both pial and dural vessels, and 3) feeders

arising predominantly from the dural vessels. In the 2 latter cases, they posited that “angiogenic stimuli from the partially thrombosed Galenic venous pouch located in the SAS and in near direct contact with the dura baring the thin arachnoid results in an angiogenic response from the dura.” We suspect that proangiogenic stimuli from the local vascular environment may play a role in recruiting vessels to the malformation, which should be investigated further. We are pursuing this hypothesis further by organizing a large-scale, multiomics analysis of the VGAM at our practice. Contrary to our observations, in other forms of AVM, it is often observed that increased vascularization occurs as a result of incomplete or staged embolization.<sup>1</sup> As a result, we believe that the physiology of VGAM may be unique among AVMs and should be examined further in the form of a multiomics analysis.

### **Patterns of FVNF**

We chiefly observed 2 patterns of FVNF with VGAM: 1) an FVNF that was present at the initial diagnostic angiogram and MR imaging, diminishing with time as the shunts are closed, and 2) an FVNF that developed during the staged embolization treatment course of the patient. We believe the latter to be due likely to incomplete shunt occlusion or shunt increase. It may also be related to increases in flow and/or tissue ischemia secondary to arterial insufficiency or venous hypertension, resulting in tissue hypoperfusion. If properly treated, this FVNF will diminish with time and regress with closure of the malformation.

### **CONCLUSIONS**

Development of an SEZ/SAS FVNF is common during the multi-session treatment of the VGAM. We believe this is an acquired and reversible phenomenon that differs from typical dural vessel recruitment, given the hairlike nature of the network and its rapid onset in cases in which it is not observed at initial imaging post-interventionally. This finding is limited by the resolution of currently available imaging modalities and will require a future pathologic study to validate. These networks regress and progress as we treat the VGAM, targeting the venous side of the fistula. It typically resolves after completion of treatment, and this resolution correlates with closure of the vein. We recommend that neurointerventionalists avoid delays in treatment wherever possible to lower the likelihood of an FVNF. In cases in which an FVNF appears spontaneously, we recommend treating the VGAM with staged TAE without embolizing individual FVNF feeders, which tend to resolve after closure of the vein.

### **Ethics Approval**

This study was approved by the Mount Sinai Hospital institutional review board with a consent waiver under IRB STUDY 21–00749.

Disclosure forms provided by the authors are available with the full text and PDF of this article at [www.ajnr.org](http://www.ajnr.org).

### **REFERENCES**

1. Buell TJ, Ding D, Starke RM, et al. **Embolization-induced angiogenesis in cerebral arteriovenous malformations.** *J Clin Neurosci* 2014;21:1866–71 [CrossRef Medline](#)

2. Khullar D, Andeepjani AM, Bulsara KR. **Evolution of treatment options for vein of Galen malformations: a review.** *J Neurosurg Pediatr* 2010;6:444–51 [CrossRef Medline](#)
3. Nuñez FB, Dohna-Schwake C. **Epidemiology, diagnostics, and management of vein of Galen malformation.** *Pediatr Neurol* 2021;119:50–55 [CrossRef Medline](#)
4. Pareek K, Shrivastava T, Sinha VD. **Choroidal type of vein of Galen aneurysmal malformation in adult patient with unusual presentation of orthostatic headache.** *Asian J Neurosurg* 2018;13:418–20 [CrossRef Medline](#)
5. Ribeiro, Valentina T, et al. **Choroidal type aneurysmal malformation of the vein of Galen associated with Dandy-Walker malformation in an adult** (in Portuguese). *Acta Med Port* 2003;16.3:217–20 [Medline](#)
6. Xu DS, Usman AA, Hurley MC, et al. **Adult presentation of a familial-associated vein of Galen aneurysmal malformation: case report.** *Neurosurgery* 2010;67:E1845–51; discussion 1851 [CrossRef Medline](#)
7. Muquit S, Shah M, Bassi S. **Vein of Galen malformation presenting in adulthood.** *Br J Neurosurg* 2008;22:692–94 [CrossRef Medline](#)
8. Marques RM, Lobão CA, Sasaki VS, et al. **Vein of Galen aneurysm in an adult: case report.** *Arq Neuropsiquiatr* 2006;64:862–64 [CrossRef Medline](#)
9. Berenstein A, Niimi Y. Vein of Galen aneurysmal malformation. In: Winn HR, ed. *Youmans Neurological Surgery*. Vol 2. 6th ed. Elsevier/Saunders; 2011;2150–65
10. Lasjaunias PL. *Vascular Diseases in Neonates, Infants and Children: Interventional Neuroradiology Management*. Springer; 1997
11. Lasjaunias PL, Chng SM, Sachet M, et al. **The management of vein of Galen aneurysmal malformations.** *Neurosurgery* 2006;59(5 Suppl 3):S184–94; discussion S3–13 [CrossRef Medline](#)
12. Lasjaunias P, ter Brugge KG, Berenstein A. *Surgical Neuroangiography: Clinical and Interventional Aspects in Children*. Vol 3. Springer; 2007
13. Bhatia K, Mendes Pereira V, Krings T, et al. **Factors contributing to major neurological complications from vein of Galen malformation embolization.** *JAMA Neurol* 2020;77:992–99 [CrossRef Medline](#)
14. Sivasankar R, Limaye V, Wappalapati S, et al. **Endovascular management of vein of Galen aneurysmal malformations: a retrospective analysis over a 15-year period.** *J Vasc Interv Neurol* 2019;10:23–29 [Medline](#)
15. Berenstein A, Fifi JT, Niimi Y, et al. **Vein of Galen malformations in neonates: new management paradigms for improving outcomes.** *Neurosurgery* 2012;70:1207–14 [CrossRef Medline](#)
16. Berenstein A, Paramasivam S, Sorscher M, et al. **Vein of Galen aneurysmal malformation: advances in management and endovascular treatment.** *Neurosurgery* 2019;84:469–78 [CrossRef Medline](#)
17. Agarwal H, Sebastian LJ, Gaikwad SB, et al. **Vein of Galen aneurysmal malformation: clinical and angiographic spectrum with management perspective—an institutional experience.** *J Neurointerv Surg* 2017;9:159–64 [CrossRef Medline](#)
18. Brinjikji W, Krings T, Murad MH, et al. **Endovascular treatment of vein of Galen malformations: a systematic review and meta-analysis.** *AJNR Am J Neuroradiol* 2017;38:2308–14 [CrossRef Medline](#)
19. Adair TH, Montani JP. Angiogenesis. *Colloquium Series on Integrated Systems Physiology: from Molecule to Function* 2010;2:1–84 [CrossRef](#)
20. Sato S, Kodama N, Sasaki T, et al. **Perinidal dilated capillary networks in cerebral arteriovenous malformations.** *Neurosurgery* 2004;54:163–70 [CrossRef Medline](#)
21. Takemae T, Kobayashi S, Sugita K. **Perinidal hypervascular network on immediate postoperative angiogram after removal of large arteriovenous malformations located distant from the arterial circle of Willis.** *Neurosurgery* 1993;33:400–06 [Medline](#)
22. Paramasivam S, Niimi Y, Meila D, et al. **Dural arteriovenous shunt development in patients with vein of Galen malformation.** *Interv Neuroradiol* 2014;20:781–89 [CrossRef Medline](#)
23. Shigematsu T, Bazil MJ, Matsoukas S, et al. **Transvenous embolization of vein of Galen aneurysmal malformations using the “Chapot pressure cooker” technique.** *Interv Neuroradiol* 2021 Dec 23. [Epub ahead of print] [CrossRef Medline](#)