

Are your MRI contrast agents cost-effective?

Learn more about generic Gadolinium-Based Contrast Agents.



FRESENIUS
KABI

caring for life

AJNR

A Comparison of Angiographic CT and Multisection CT in Lumbar Myelographic Imaging

J.-H. Buhk, E. Elolf, D. Jacob, H.-H. Rustenbeck, A. Mohr
and M. Knauth

This information is current as
of April 19, 2024.

AJNR Am J Neuroradiol published online 7 December 2007
<http://www.ajnr.org/content/early/2007/12/07/ajnr.A0853.citation>

ORIGINAL
RESEARCH

J.-H. Buhk
E. Eloff
D. Jacob
H.-H. Rustenbeck
A. Mohr
M. Knauth

A Comparison of Angiographic CT and Multisection CT in Lumbar Myelographic Imaging

BACKGROUND AND PURPOSE: The purpose of this work was to provide an intraindividual comparison of angiographic CT (ACT) and multisection CT (MSCT) in lumbar myelographic imaging and to evaluate possible benefits of ACT, which is a further development of rotational angiography providing image data of high spatial and CT-like contrast resolution.

MATERIALS AND METHODS: In 26 patients with degenerative lumbar spine disease a lumbar ACT was performed in combination with conventional lumbar myelography and followed by postmyelographic MSCT. Conventional lumbar myelography and lumbar ACT were performed with a flat panel detector-equipped angiographic device. Postmyelographic MSCT was performed with a 16-section CT scanner. Three experienced neuroradiologists rated anonymized sets of multiplanar reformatted CT and ACT images regarding diagnostic and technical parameters. The ratings were repeated after 2 months. Weighted κ statistics were calculated to describe the levels of intraobserver and interobserver agreement.

RESULTS: The analysis shows that MSCT achieves higher ratings than ACT in all of the parameters asked. An adequate diagnostic quality was only assigned to 80% of the ACT acquisitions compared with 97% of the MSCT acquisitions. All of the mean κ values were above 0.60, demonstrating a substantial intraobserver and interobserver agreement for MSCT, as well as for ACT.

CONCLUSION: Using ACT, radiographic myelography and myelographic CT can be performed at the same imaging system. However, the results of our study show that the current myelographic ACT image quality fails to apply diagnostic standards. We, therefore, cannot recommend ACT as a general alternative to postmyelographic MSCT.

Radiographic myelography and postmyelographic CT using multisection CT (MSCT) scanners are well-established diagnostic procedures in degenerative or traumatic lumbar spine disease. Especially when the diagnostic evaluation of the thecal sac and single nerve roots in degenerative spine disease is required, myelography and postmyelographic CT are considered to be even more sensitive and more specific than MR imaging or MR myelography.¹ In addition, degenerative osseous changes are better examined by radiography or CT.²⁻⁵

From the neuroradiologic point of view, 3D rotational angiography is primarily a technique to visualize intracranial vessels, particularly aneurysms, in a 3D surface-shaded or volume-rendered reconstruction. It has already been demonstrated that 3D rotational myelographic imaging with image intensifier equipped systems is possible and provides multiplanar reconstructed (MPR) images of good quality.⁶ In comparison with the image intensifier-equipped systems, the latest flat panel detector-equipped angiographic devices provide a much higher acquisition speed and image information attenuation.⁷ These features are combined with a large rectangular field of view. Rotational acquisitions by such detectors provide an almost CT-like contrast resolution allowing a differentiation of objects down to 10 Hounsfield units of attenuation difference. This can be of great importance during neurointerventional

procedures.⁸⁻¹⁰ The spatial resolution is higher than in current helical CT: angiographic CT (ACT) provides an isotropic resolution of less than 0.2 mm in comparison with approximately 0.5 mm of minimal CT resolution.^{11,12} The ACT volume dataset (~20-cm width and 25-cm height) can be used for 3D and multiplanar reconstructions in the same fashion as a spiral CT dataset.

The purpose of the study presented here was to test the practicability and the diagnostic features of myelographic section imaging by ACT in comparison with MSCT to verify a possible added diagnostic value of ACT and to provide first evidence about the feasibility of substituting myelographic MSCT with ACT.

Methods

Patients

Between November 2005 and March 2006, 26 consecutive patients with degenerative lumbar spine disease of different degrees (11 women and 15 men; median age, 61 years; range, 51–74 years) underwent a diagnostic myelography in our department. ACT was additionally performed to obtain images with a very high spatial resolution and to reduce fluoroscopy time by planning radiographic projections on the 3D ACT reconstructions. Approval of the local ethics committee and informed patient consent were obtained.

Image Acquisition

Rotational and conventional lumbar myelographies were performed on an AXIOM Artis dBA biplane angiography system equipped with flat panel detectors (Siemens Medical Solutions, Forchheim, Germany). The unit is certified to be used in whole body examinations according to the current ionizing radiation regulations (“CE” mark).

Received June 26, 2007; accepted after revision September 9.

From the Department of Neuroradiology, University of Goettingen, Goettingen, Germany. Drs Buhk and Knauth received grants for travel expenses from Siemens Medical Systems (Forchheim, Germany).

Please address correspondence to Jan-Hendrik Buhk, Department of Neuroradiology, University of Goettingen, Robert-Koch-Str 40, D-37075 Goettingen, Germany; e-mail: jbhk@gwdg.de

DOI 10.3174/ajnr.A0853

Table 1: Cumulative results after all ratings

Variable		Very Good, n (%)	Good, n (%)	Moderate, n (%)	Poor, n (%)	Very Poor, n (%)	Total, n (%)
Overall impression	ACT	46 (28.8)	79 (49.4)	7 (4.4)	27 (16.9)	1 (0.6)	160 (100)
	MSCT	90 (58.1)	47 (30.3)	4 (2.6)	11 (7.1)	3 (1.94)	155 (100)
Contrast media distribution	ACT	49 (30.6)	80 (50.0)	13 (8.1)	18 (11.3)	0 (0.0)	160 (100)
	MSCT	90 (58.1)	46 (29.7)	5 (3.2)	11 (7.1)	3 (1.9)	155 (100)
Perceptibility of intervertebral disks	ACT	22 (13.8)	17 (10.7)	9 (5.7)	77 (48.4)	35 (22.0)	160 (100)
	MSCT	55 (35.3)	60 (38.5)	15 (9.6)	25 (16.0)	0 (0.0)	155 (100)
Perceptibility of bone structure	ACT	26 (16.3)	71 (44.4)	10 (6.3)	50 (31.3)	3 (1.9)	160 (100)
	MSCT	117 (74.5)	34 (21.9)	2 (1.3)	2 (1.3)	0 (0.0)	155 (100)
Delineation of the spinal canal	ACT	71 (44.4)	76 (47.5)	3 (1.9)	10 (6.3)	0 (0.0)	160 (100)
	MSCT	128 (82.6)	26 (16.8)	0 (0.0)	1 (0.7)	0 (0.0)	155 (100)
Delineation of spinal nerve roots	ACT	35 (22.0)	60 (37.5)	13 (8.1)	46 (28.8)	6 (3.8)	160 (100)
	MSCT	87 (56.1)	50 (32.3)	8 (5.2)	10 (6.5)	0 (0.0)	155 (100)
Diagnostic applicability	ACT	30 (37.0)	36 (44.4)	4 (4.9)	10 (12.4)	1 (1.2)	81 (100)
	MSCT	48 (61.6)	28 (35.9)	1 (1.3)	1 (1.3)	0 (0.0)	78 (100)

Note:—ACT indicates angiographic CT; MSCT, multisection CT.

First, intrathecal contrast media application was performed, commonly in between L3 and L4 (15–20 mL of Isovist 300; Schering, Berlin, Germany). In prone position and with breath hold, the rotational acquisitions (1 per patient) were performed with the following parameters: 20 seconds of rotation, 538 projections, 220° total angle (30 cm × 40 cm detector size), and weighted CT dose index at ~22 mGy (manufacturer information). On the same system and in prone position, as well, myelograms were acquired in standard projections (anteroposterior, right and left posterior oblique, and lateral). Because the table of the angiographic device can only be tilted to 15°, lateral projections in anteflexion and retroflexion out of the erect position were performed with a conventional radiographic device (MPG 80; GE Healthcare, Chalfont St Giles, United Kingdom), when requested by the neurosurgeon concerned. Those views are not routinely acquired in our department. Conventional myelographic MSCT scans were performed in supine position on a 16-section CT scanner (Aquilion; Toshiba Medical Systems, Tokyo, Japan).

Image Postprocessing

Postprocessing of the rotational image data to a volume dataset (ACT) was performed using dedicated commercial software on a “Leonardo” medical workstation (DynaCT, InSpace 3D; Siemens Medical Solutions). The software includes the application of system-specific filter algorithms to correct for beam hardening, scattered radiation, truncated projections, and ring artifacts. Postprocessing resulted in a volume dataset defined by a batch of 400–500 sections in a 256 × 256 matrix. Single-section thickness was 0.2–0.3 mm (isotropic). Postprocessing in a higher-resolution matrix was performed in some cases but not used for the study because of a limited reconstruction volume size that did not provide coverage of the whole lumbar spine.

For retrospective evaluation ACT and MSCT data were further processed into MPR sections in sagittal and transversal directions: of all of the examinations, 2 stacks of transversal sections (8 sections each; single section thickness, 2 mm) covering 2 lumbar segments, mostly L4/5 and L5/S1, were prepared. A second stack of 4 midsagittal sections was additionally prepared (single section thickness, 2 mm). Window levels were not standardized; a typical window level for ACT was (length/width) 1500/4000 and for MSCT was 1000/2500. The images were anonymized and printed on x-ray films to be viewed under realistic diagnostic conditions.

Statistical Analysis

Three experienced neuroradiologists (E.E., A.M., H.-H.R.), blinded for the history, clinical symptoms, and acquisition technique, performed the film viewing. They were asked to rate the value of the documented reconstructions according to the following categories in a 5-step ordinal scale (“very good” versus “good” versus “moderate” versus “poor” versus “very poor”): “overall impression,” “contrast media distribution,” “perceptibility of intervertebral disks,” “perceptibility of bone structures,” “delineation of the spinal canal,” “delineation of spinal nerve roots,” and “diagnostic applicability.” Film viewing was repeated after a 3-month interval, and the term “diagnostic applicability” was only asked in the second ranking, to allow a familiarization with the different visual impression provided by the ACT. Weighted κ statistics were calculated to assess intraobserver and interobserver variabilities, and a value above $\kappa = 0.60$ was assumed to represent substantial agreement.¹³

Results

Ratings

Both methods achieved predominantly positive results in all of the diagnostic categories evaluated. Table 1 shows the cumulative results of all of the ratings. Total numbers differ a little due to loss of 1 of the pseudonomized films during the first rating session. Combining the categories “very good” and “good” to form the positive side of the test leads to the following results: “overall impression”: ACT at 78.2% versus MSCT at 88.4% (Fisher exact test, 2-tailed, $P = .016$); “contrast media distribution”: ACT at 80.6% versus MSCT at 87.8% ($P = .091$); “perceptibility of intervertebral disks”: ACT at 24.5% versus MSCT at 73.8% ($P < .001$); “perceptibility of bone structure”: ACT at 60.7% versus MSCT at 96.4% ($P < .001$); “delineation of the spinal canal”: ACT at 91.9% versus MSCT at 99.4% ($P = .001$); “delineation of spinal nerve roots”: ACT at 59.5% versus MSCT at 88.4% ($P < .001$); and “diagnostic applicability”: ACT at 81.4% versus MSCT at 97.5% ($P = .001$).

κ Statistics

The mean results of the κ statistics for interobserver agreement are presented in Table 2 (2 ratings and 3 observers: $n =$

Table 2: Interobserver agreement

Variable	ACT, Mean κ Values \pm SD	MSCT, Mean κ Values \pm SD	<i>P</i>
Overall impression	0.73 \pm 0.06	0.78 \pm 0.04	.117
Contrast media distribution	0.74 \pm 0.05	0.65 \pm 0.09	.059
Perceptibility of intervertebral disks	0.65 \pm 0.22	0.69 \pm 0.09	.689
Perceptibility of bone structure	0.64 \pm 0.12	0.78 \pm 0.05	.030
Delineation of the spinal canal	0.75 \pm 0.05	0.78 \pm 0.03	.172
Delineation of spinal nerve roots	0.66 \pm 0.09	0.72 \pm 0.03	.193
Diagnostic applicability	0.74 \pm 0.06	0.75 \pm 0.03	.826

Note:—ACT indicates angiographic CT; MSCT, multisection CT. Data are $n = 6$, except for “diagnostic applicability,” where $n = 3$ by Student *t* test.

Table 3: Intraobserver agreement

Variable	ACT, Mean κ Values \pm SD	MSCT, Mean κ Values \pm SD	<i>P</i>
Overall impression	0.81 \pm 0.05	0.73 \pm 0.15	.454
Contrast media distribution	0.75 \pm 0.02	0.79 \pm 0.08	.533
Perceptibility of intervertebral disks	0.65 \pm 0.26	0.68 \pm 0.17	.875
Perceptibility of bone structure	0.74 \pm 0.02	0.78 \pm 0.02	.068
Delineation of the spinal canal	0.75 \pm 0.08	0.78 \pm 0.02	.659
Delineation of spinal nerve roots	0.74 \pm 0.04	0.78 \pm 0.03	.256

Note:—ACT indicates angiographic CT; MSCT, multisection CT. Data are $n = 3$ by Student *t* test.

6, paired; apart from “diagnostic applicability”: $n = 3$). A substantial level of agreement results in testing each observer against the others for ACT, as well as for MSCT.¹⁴ Performing a 2-tailed Student *t* test (95% confidence interval), a significant difference in agreement only appears in the category “perceptibility of bone structure.” Here, the agreement between the observers is relatively low for the ACT data in comparison with MSCT. In the category “contrast media distribution,” statistical significance is just missed. Here, the level of agreement is much higher for ACT. The κ values obtained for the category “diagnostic applicability” are very similar between the observers (ACT, 0.74 \pm 0.06 versus MSCT, 0.75 \pm 0.03; $P = .8261$).

The results of the κ statistics for intraobserver agreement are presented in Table 3. Again, substantial agreement is obtained for both methods in all of the categories.¹⁴ Almost perfect agreement emerges for ACT in the category “overall impression.”¹⁴

Discussion

This is the first study comparing the diagnostic value of ACT versus MSCT in lumbar myelographic imaging. Single case reports have shown previously that the method itself is feasible and that an acceptable image quality is achievable.^{6,15} A similar application has already been described in a small case series: an intraoperative C-arm system with capability of rotational acquisition was used for multiplanar myelographic imaging during lumbar decompression.¹⁶

Both ACT and MSCT yielded predominantly positive or very positive results in all of the diagnostic categories. MSCT as the current “gold standard” was significantly better than ACT in all of the diagnostic categories. Only 80% of all of the ACT examinations were rated as sufficient for diagnosis. The shortcomings in myelographic ACT especially concern the delineation of soft tissue structures. Although it is the main purpose of a myelogram to delineate the thecal sac, the spinal

nerve roots, and the adjacent bone, it is the particular interest in myelographic CT to additionally provide information on soft tissue structures like ligaments and intervertebral disks. Here, ACT fails in up to 70% of cases (“perceptibility of intervertebral disks”; Table 1).

Interobserver and intraobserver agreement in the weighted κ statistics were substantially good in all of the categories and for both methods.^{14,17} The testing of the intraobserver agreement does not reveal any hint for a learning curve regarding ACT images, which would be represented by a lower κ value than that of MSCT.

The primary application of ACT is the imaging of high-contrast structures, such as vessels filled with contrast media.¹⁸ In this study we describe a different application by performing an ACT examination after intrathecal administration of contrast media. The 3D information contained in the myelographic ACT datasets can be used for 3D volume-rendered technique (VRT) and 3D maximum intensity projection (MIP) images that compare well with conventional myelography (Fig 1). In addition, using these volume data to plan the myelographic projections could save fluoroscopy time; having performed the rotational acquisition as the very first scan, one can place the C-arm according to the position of the 3D image on the workstation and thereby avoid fluoroscopy. The approximated radiation dosage of 20 mGy per ACT acquisition (manufacturer information) is relatively low compared with an abdominal CT acquisition (40 mGy).¹⁹ Phantom measurements of effective patient dosage in lumbar ACT acquisitions have not been available thus far.

However, the higher spatial resolution of ACT in comparison with MSCT did not translate into a diagnostic advantage in our series (Figs 2 and 3). When conducting the examinations, we were expecting a far better delineation of the bone and of a smaller structure, such as the spinal nerve roots. A reason for the relatively poor rankings of ACT in these categories may be the significant amount of ring artifacts, edge artifacts, and scattered radiation-related image noise, which partially antagonized the high spatial resolution and significantly lowered the signal intensity-to-noise ratio. A possible source of movement artifacts may be the patient’s position during the rotational acquisition; like in conventional myelography, the patients were placed in the prone position. Placement in the supine position, as in postmyelographic CT, could serve as a solution.

The technical conditions in our study differ from the first case report on rotational myelography, where an image intensifier-equipped system was used.⁶ The acquisition protocol that we used is dedicated to achieve a contrast resolution close to conventional CT in combination with high spatial resolution; therefore, the relatively long acquisition time of 20 seconds is necessary. Otherwise we could not expect to discriminate disks and ligaments in a CT-like fashion. Because breath holds for up to 20 seconds are difficult to perform for some patients with lumbago, the duration of the acquisition is a significant drawback, possibly causing substantial movement artifacts. Further technical developments concerning faster digital image acquisition might provide faster protocols in the future.

Our retrospective analysis demonstrates that, in a large amount of patients, the entire diagnostic myelographic examination, including multiplanar cross-sectional imaging,

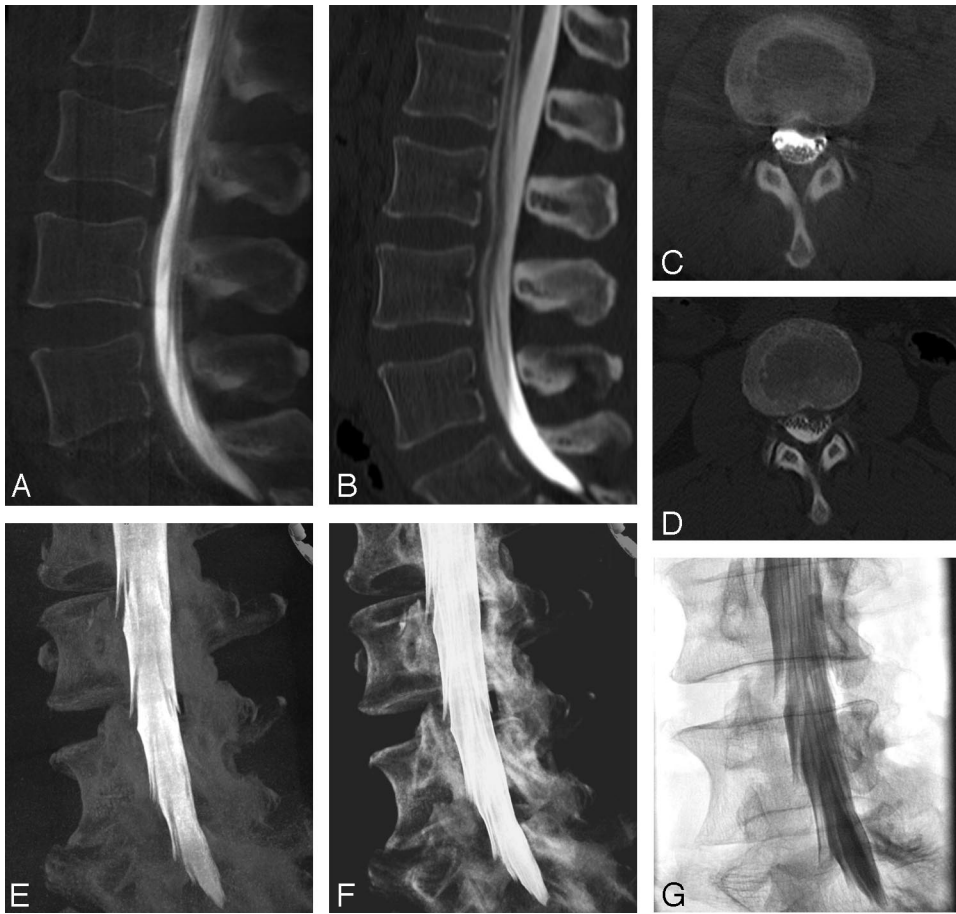


Fig 1. Images from a 58-year-old woman with persistent back pain. The left lateromedial prolapsed intervertebral disk in the segment L2/3 is equally well visible in both ACT (A and C) and MSCT (B and D) images. ACT images in the left posterior oblique position are displayed as 3D-MIP (E) and 3D-VRT (F). G. The myelographic projection was derived by transferring the position of the 3D volume from the workstation to the C-arm. Hence, no additional fluoroscopy was necessary to determine the optimal angles for projection myelographies.

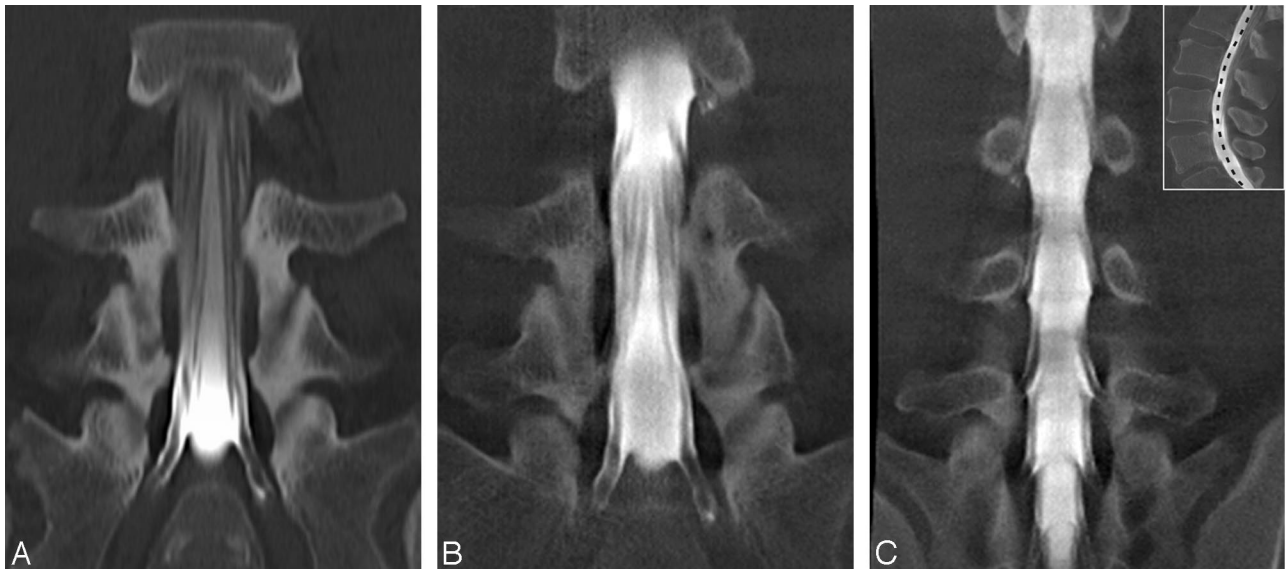


Fig 2. Images from a 62-year-old man with symptoms of spinal claudication. Coronal MPR planes of ACT (A) and MSCT (B) are of equal quality. C. A curved coronal reconstruction of the ACT provides an appropriate depiction of the segmental nerve roots.

could have been performed at the angiographic device. Concerning efficiency, it may be advantageous to perform conventional myelography and cross-sectional imaging at a single imaging system plus all of the postprocessing on 1 workstation. If this was practiced, an additional postmyelographic MSCT scan could always be performed later on, for example, limited to a certain segment of interest or in question, if

the rotational acquisition is not sufficient for diagnosis. An important benefit for the patient would be a substantial amount of time saved and comfort gained by possibly saving the MSCT scan.^{12,20} However, to establish myelographic ACT as a realistic diagnostic alternative to MSCT in diagnostic myelographic imaging, the imaging characteristics of ACT are currently not sufficient.

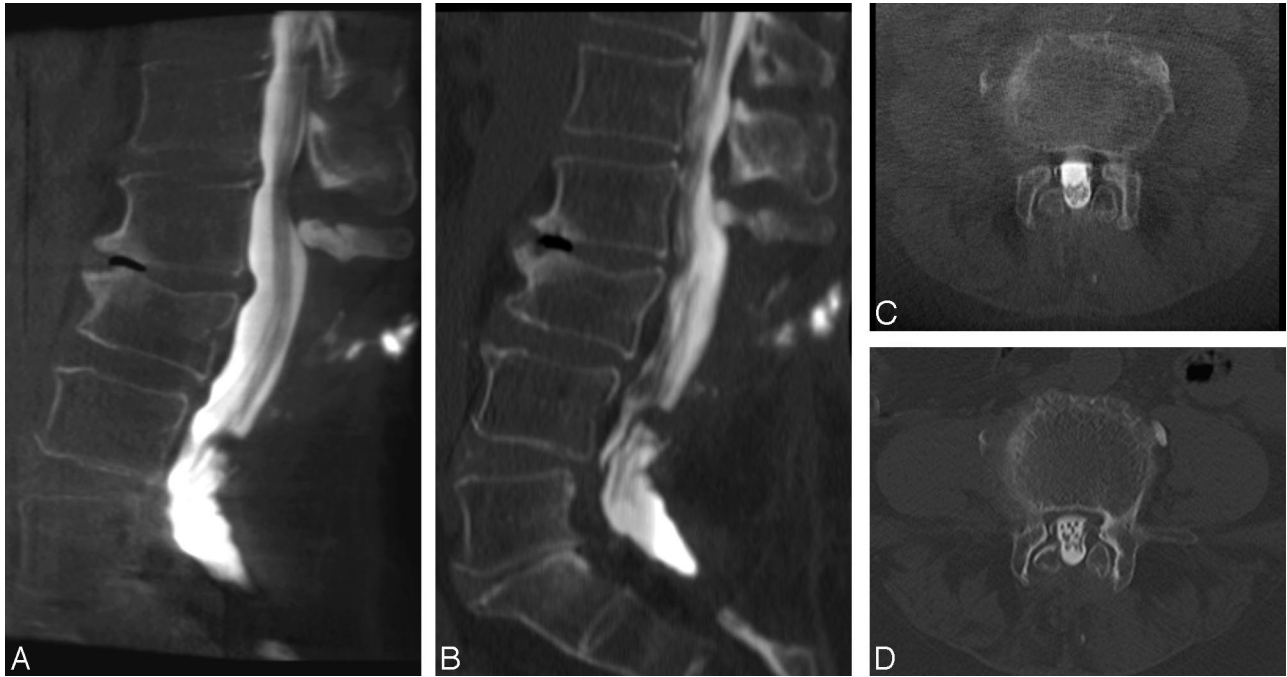


Fig 3. MPR images from a 75-year-old woman with persistent back pain after multisegmental laminectomy. In the sagittal sections (A, ACT; B, MSCT), the relevant degenerative changes can be depicted equally well: ligamentous hyperplasia in the segment L1/2, ventral osteochondrosis in the segment L2/3, and the slight listhesis in the segment L4/5. A, Note the loss of detail and the enhanced image noise in the ACT section at the level from L5 to S2 due to the high attenuation of contrast media in the thecal sac. The transverse sections through the vertebral body of L4 (C, ACT; D, MSCT) show the hypertrophic facet joints and the thecal sac herniating into the laminectomy site. Both techniques show a well-defined L4 nerve root of the right side and an increase of tissue around the L4 nerve root of the contralateral side.

References

- Bartynski WS, Lin L. Lumbar root compression in the lateral recess: MR imaging, conventional myelography, and CT myelography comparison with surgical confirmation. *AJNR Am J Neuroradiol* 2003;24:348–60
- Bischoff RJ, Rodriguez RP, Gupta K, et al. A comparison of computed tomography-myelography, magnetic resonance imaging, and myelography in the diagnosis of herniated nucleus pulposus and spinal stenosis. *J Spinal Disord* 1993;6:289–95
- Saint-Louis LA. Lumbar spinal stenosis assessment with computed tomography, magnetic resonance imaging, and myelography. *Clin Orthop Relat Res* 2001;122–36
- Thornton MJ, Lee MJ, Pender S, et al. Evaluation of the role of magnetic resonance myelography in lumbar spine imaging. *Eur Radiol* 1999;9:924–29
- Tsuchiya K, Katase S, Aoki C, et al. Application of multi-detector row helical scanning to postmyelographic CT. *Eur Radiol* 2003;13:1438–43
- Kufeld M, Claus B, Campi A, et al. Three-dimensional rotational myelography. *AJNR Am J Neuroradiol* 2003;24:1290–93
- Zellerhoff M, Scholz B, Ruehrnschopf EP, et al. Low contrast 3D reconstruction from C-arm data. *Proc SPIE* 2005;5745:646–55
- Benndorf G, Strother CM, Claus B, et al. Angiographic CT in cerebrovascular stenting. *AJNR Am J Neuroradiol* 2005;26:1813–18
- Benndorf G, Claus B, Strother CM, et al. Increased cell opening and prolapse of struts of a Neuroform stent in curved vasculature: value of angiographic computed tomography: technical case report. *Neurosurgery* 2006;58:ONS-E380; discussion ONS-E380
- Heran NS, Song JK, Namba K, et al. The utility of DynaCT in neuroendovascular procedures. *AJNR Am J Neuroradiol* 2006;27:330–32
- Kalender WA. The use of flat-panel detectors for CT imaging [in German]. *Radiologie* 2003;43:379–87
- Loose R, Wucherer M, Brunner T. [Visualization of 3D low contrast objects by CT cone-beam reconstruction of a rotational angiography with a dynamic solid body detector [in German]. *RoFo* 2005;S1:PO 160
- Cohen J. Weighted kappa: nominal scale agreement with provision for scaled disagreement or partial credit. *Psychol Bull* 1968;70:213–20
- Landis JR, Koch GG. The measurement of observer agreement for categorical data. *Biometrics* 1977;33:159–74
- Buhk JH, Elolf E, Knauth M. Angiographic computed tomography is comparable to multislice computed tomography in lumbar myelographic imaging. *J Comput Assist Tomogr* 2006;30:739–41
- Mauer UM, Kunz U. Intraoperative three-dimensional imaging to monitor selective decompression in lumbar spinal stenosis [in German]. *Orthopade* 2006;35:1258–60
- Jakobsson U, Westergren A. Statistical methods for assessing agreement for ordinal data. *Scand J Caring Sci* 2005;19:427–31
- Anxionnat R, Bracard S, Macho J, et al. 3D angiography. Clinical interest. First applications in interventional neuroradiology. *J Neuroradiol* 1998;25:251–62
- Gray JE, Archer BR, Butler PF, et al. Reference values for diagnostic radiology: application and impact. *Radiology* 2005;235:354–58
- Akhtar M, Vakharia KT, Mishell J, et al. Randomized study of the safety and clinical utility of rotational vs. standard coronary angiography using a flat-panel detector. *Catheter Cardiovasc Interv* 2005;66:43–49