

Are your **MRI contrast agents** cost-effective?

Learn more about generic **Gadolinium-Based Contrast Agents**.



**FRESENIUS  
KABI**

caring for life

**AJNR**

**Do Apparent Diffusion Coefficient  
Measurements Predict Outcome in Children  
with Neonatal Hypoxic-Ischemic  
Encephalopathy?**

L. Liauw, G. van Wezel-Meijler, S. Veen, M.A. van Buchem  
and J. van der Grond

This information is current as  
of April 20, 2024.

*AJNR Am J Neuroradiol* published online 8 October 2008  
<http://www.ajnr.org/content/early/2008/10/08/ajnr.A1318.citation>

ORIGINAL  
RESEARCH

L. Liauw  
G. van Wezel-Meijler  
S. Veen  
M.A. van Buchem  
J. van der Grond

# Do Apparent Diffusion Coefficient Measurements Predict Outcome in Children with Neonatal Hypoxic-Ischemic Encephalopathy?

**BACKGROUND AND PURPOSE:** Diffusion-weighted imaging (DWI) permits early detection and quantification of hypoxic-ischemic (HI) brain lesions. Our aim was to assess the predictive value of DWI and apparent diffusion coefficient (ADC) measurements for outcome in children with perinatal asphyxia.

**MATERIALS AND METHODS:** Term neonates underwent MR imaging within 10 days after birth because of asphyxia. MR imaging examinations were retrospectively evaluated for HI brain damage. ADC was measured in 30 standardized brain regions and in visibly abnormal areas on DWI. In survivors, developmental outcome until early school age was graded into the following categories: 1) normal, 2) mildly abnormal, and 3) definitely abnormal. For analysis, category 3 and death (category 4) were labeled "adverse," 1 and 2 were "favorable," and 2–3 and death were "abnormal" outcome. Differences in outcome between infants with and without DWI abnormalities were analyzed by using  $\chi^2$  tests. The nonparametric Mann-Whitney *U* test analyzed whether ADC values in visible DWI abnormalities correlated with age at imaging. Logistic regression analysis tested the predictive value for outcome of the ADC in each standardized brain region. Receiver operating characteristic analysis was used to find optimal ADC cutoff values for each region for the various outcome scores.

**RESULTS:** Twenty-four infants (13 male) were included. Mean age at MR imaging was 4.3 days (range, 1–9 days). Seven infants died. There was no difference in outcome between infants with and without visible DWI abnormalities. Only ADC of the posterior limb of the internal capsule correlated with age. ADC in visibly abnormal DWI regions did not have a predictive value for outcome. Of all measurements performed, only the ADC in the normal-appearing basal ganglia and brain stem correlated significantly with outcome; low ADC values were associated with abnormal/adverse outcome, and higher ADC values, with normal/favorable outcome (basal ganglia:  $P = .03$  for abnormal,  $P = .01$  for adverse outcome; brain stem:  $P = .006$  for abnormal,  $P = .03$  for adverse outcome).

**CONCLUSIONS:** ADC values in normal-appearing basal ganglia and brain stem correlated with outcome, independently of all MR imaging findings including those of DWI. ADC values in visibly abnormal brain tissue on DWI did not show a predictive value for outcome.

Neonatal hypoxic-ischemic (HI) brain injury is one of the most important causes of neurologic disabilities during childhood, accounting for more than half of the cases of cerebral palsy.<sup>1,2</sup> MR imaging is an established tool to detect neonatal brain injury, and it plays an important role in the prediction of neurologic outcome in neonates with HI brain injury.<sup>2–6</sup> MR imaging findings of the brains of neonates with HI encephalopathy (HIE) have been described by many authors.<sup>1,3,4,6,7</sup> Conventional T1- and T2-weighted images are used most often but findings may be normal despite significant brain injury, especially when imaging is performed early, during the first few days after the event.<sup>1,3,6,7</sup>

Diffusion-weighted imaging (DWI) often reveals HI brain injury at an earlier stage than conventional MR imaging<sup>8–11</sup>; in addition, it provides quantitative apparent diffusion coefficient (ADC) values in brain tissue.<sup>12–16</sup> It has been proposed that these quantitative measures may have additional diagnostic value, especially in cases with diffuse lesions that may remain below the threshold of visual detection. Some articles have published normal values for ADC in different regions of

the normal brain in young infants.<sup>12,13,16,17</sup> Others have reported abnormal ADC values in severely abnormal (as shown by MR imaging) white matter and deep gray matter, during the first week after the HI event.<sup>11–13,18–22</sup> However, in none of these studies were ADC values related to longer follow-up.<sup>11–13,18–22</sup> In addition, none of these study outcomes were related to ADC in normal-appearing brain regions. To our knowledge, only 1 relatively small study in 11 neonates described the predictive value of DWI and ADC measurements for outcome at 24 months of age in children born asphyxiated.<sup>23</sup> Predictive values of DWI or ADC were not calculated. In that study, DWI was measured only in the basal ganglia and periventricular white matter. No discrimination between regions with visible DWI abnormalities and normal-appearing regions was made.

In the present study, we investigated the value of DWI for outcome prediction until early school age in neonates with HIE. Our aim was to assess the following: 1) the relation between visible DWI abnormalities and outcome, and 2) the relation to outcome of ADC values in regions with and without visible DWI abnormalities.

## Materials and Methods

### Subjects

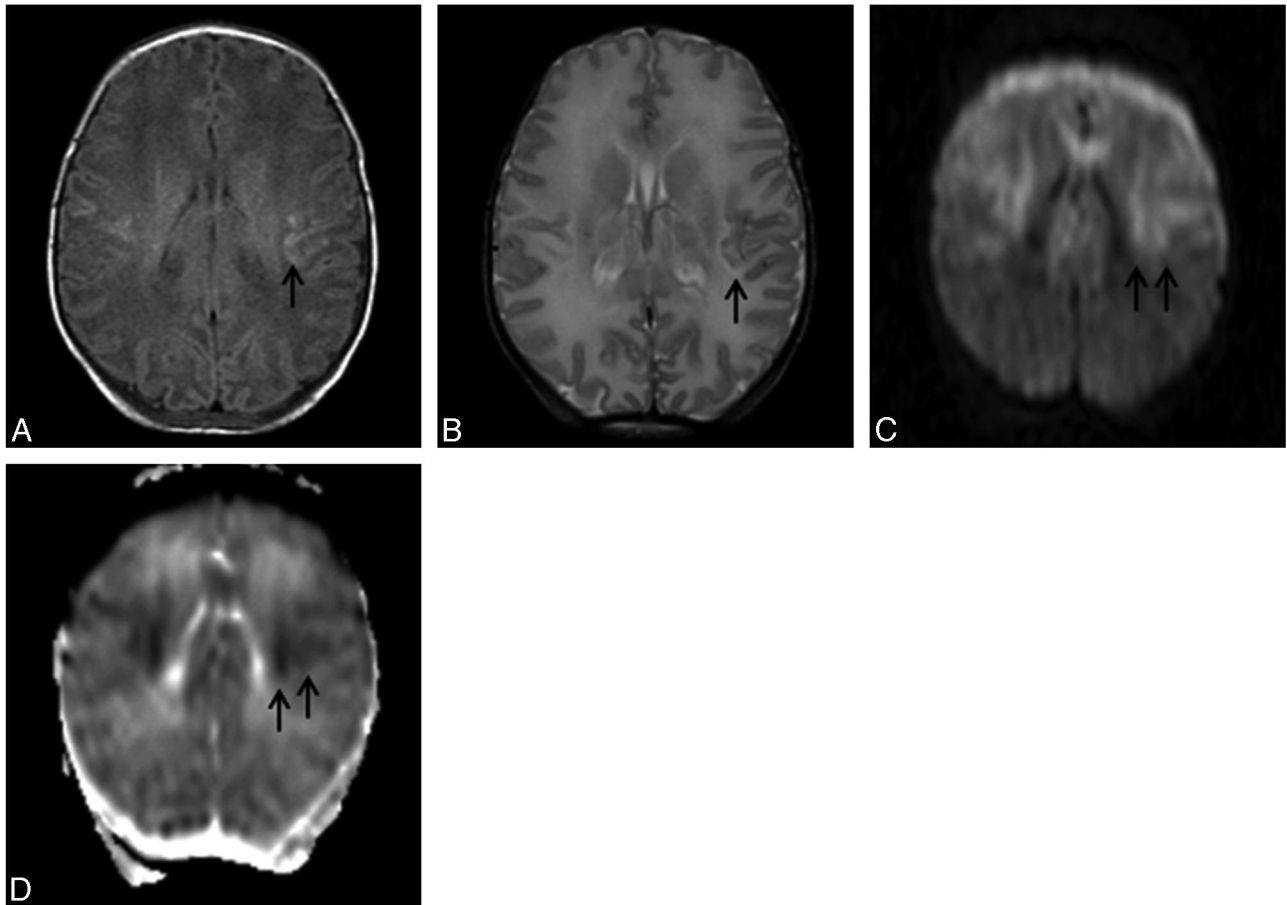
The institutional review board approved this retrospective study and waived informed consent. Brain MR imaging studies performed be-

Received June 15, 2008; accepted after revision August 11.

From the Departments of Radiology (L.L., M.A.v.B., J.v.d.G.) and Neonatology (G.v.W.-M., S.V.), Leiden University Medical Center, Leiden, the Netherlands.

Please address correspondence to L. Liauw, MD, Department of Radiology/667, Radboud University Nijmegen Medical Center, PO Box 9101, 6500 HB Nijmegen, the Netherlands; e-mail: lishya\_liauw@nmi.com.sg

DOI 10.3174/ajnr.A1318



**Fig 1.** A, T1-weighted image: TR/TE, 550/14 ms; signals acquired, 2; matrix, 205/256; section thickness, 5 mm; section gap, 0.5 mm; FOV, 16 cm. B, T2-weighted image: TR/TE, 5405/120 ms; signals acquired, 2; matrix, 205/256; section thickness, 5 mm; section gap, 0.5 mm; FOV, 16 cm. C,  $b=1000$  DWI image: TR/TE, 4299/74 ms; section thickness, 6 mm; b-value of 1000  $s/mm^2$ . D, ADC image. These images are of an infant of outcome group 3 (definitely abnormal outcome at 4 years 9 months of age). The T1-weighted (A) image shows irregular high SI in and around the peri-Rolandic cortex (arrow). The T2-weighted image (B) shows abnormal high SI in the subcortical white matter around the peri-Rolandic area (arrow). The  $b=1000$  DWI (C) shows high SI in the peri-Rolandic area and the central white matter (arrows). The ADC image (D) shows low SI in the peri-Rolandic area and the central white matter (arrows).

tween January 2001 and December 2003 in infants who were born at a gestational age of  $>37$  weeks and who underwent MR imaging to assess brain injury due to perinatal asphyxia were selected as previously described.<sup>24</sup> All MR imaging examinations were performed within 10 days after birth. All 24 infants included in our study were born at or transferred to our institution and were admitted to our tertiary neonatal intensive care unit. They were included if they fulfilled all the following criteria: 1) signs of fetal distress before delivery (abnormal cardiocographic recording such as decreased variability, late deceleration, baseline bradycardia); 2) Apgar score of  $<7$  after 5 minutes; 3) umbilical cord blood pH level of  $<7.2$ ; 4) clinical signs of HIE,<sup>25</sup>; and 5) radiologic evidence of HI brain injury on MR imaging as reported by the attending neuroradiologist.

Evaluation of the clinical history, retrospectively based on data from individual patient documentation, was performed by 1 author (S.V., having 23 years of experience in neonatology and neonatal follow-up). This author was blinded to the results of the brain MR imaging examinations and ADC measurements. Neonatal clinical classification of HIE was retrospectively graded according to Sarnat and Sarnat.<sup>25</sup> HIE stage 1 indicates a mild encephalopathy, lasting  $<24$  hours with normal findings on electroencephalography (EEG). HIE stage 2 indicates a moderate encephalopathy, with the infant being lethargic and hypotonic and having seizures. In HIE stage 3, there is a severe encephalopathy with the infant being comatose and severely

hypotonic with decreased or absent reflex activity and a severely depressed EEG finding.<sup>25</sup>

Surviving infants visited the outpatient clinic of our institution or the referring hospital at regular intervals, at the ages of 3 months, 1 year, 2 years, and 5 years. If necessary as judged by the clinical condition, additional visits were scheduled. All surviving infants underwent developmental and neurologic examinations performed by experienced and specially trained neonatologists, pediatricians, or child neurologists. In surviving children, developmental outcome at clinical follow-up was graded as follows<sup>21</sup>: 1) normal—that is, normal neurologic examination findings, normal cognitive developmental history, and normal Van Wiechen examination findings (a Dutch child health care developmental assessment tool based on the developmental scales of Gesell and adapted by Touwen and Hempel<sup>26,27</sup>); 2) mildly abnormal—that is, mildly abnormal neurologic findings (mild hypertonia, hypotonia, and/or asymmetry) and/or mildly abnormal cognitive developmental history (such as mild speech and language delay, mild behavioral disorders, and/or the need for remedial teaching at school) and/or mildly abnormal Van Wiechen examination findings; and 3) definitely abnormal—that is, children with major neurologic problems, such as cerebral palsy and/or severe cognitive function disorders and/or epilepsy and/or severely abnormal Van Wiechen examination findings. Outcome was classified in category 4 in case of neonatal death. For analysis, outcome categories 1

and 2 were labeled “favorable”; categories 3 and 4, “adverse”; and categories 2–4, “abnormal.” Outcome was retrospectively graded by 1 author (S.V.), again blinded to the MR imaging findings and also to the neonatal clinical classification. Outcome classification was based on a compilation of all available information of all follow-up visits.

### MR Imaging

If necessary, the infants were sedated. In ventilated sedated infants or infants on antiepileptic medication, this sedation was performed by increasing the dosage of the sedative or antiepileptic medication just before the MR imaging procedure. Those who were not on sedatives or antiepileptic medication received chloral hydrate, 50–70 mg/kg, administered orally 30 minutes before imaging. Infants were positioned supine and snugly swaddled in blankets during the imaging procedure. Ear protection was used and consisted of commercially available neonatal ear muffs (MiniMuffs; Natus Medical, San Carlos, Calif) placed over the ears. The infant’s head was immobilized by molded foam put around the head during the imaging procedure. The temperature was maintained and heart rate and oxygen saturation were monitored throughout the procedure. A physician experienced in neonatal resuscitation was always present during imaging and transportation to and from the MR imaging unit.

Images were obtained with superconducting magnets (Gyrosan ACS-NT 15; Philips Medical Systems, Best, the Netherlands) operating at a field strength of 1.5T. T1-weighted spin-echo sequences (TR/TE, 550–560/14–20 ms), T2-weighted spin-echo sequences (TR/TE, 5406–6883/100–120 ms), fluid-attenuated inversion recovery sequences (TR/TE, 6000–8000/110–120 ms; TI, 2000 ms), T1-weighted gadolinium-enhanced spin-echo sequences (TR/TE, 550–560/14–20 ms), and DWI were performed. DWI was performed by using a single-shot spin-echo echo-planar sequence (TR/TE, 5132–4200/74 ms) with a b-value of 1000 s/mm<sup>2</sup>. All sequences were performed in transverse planes. Section thickness was 4–5 mm with an intersection gap of 0.4–0.5 mm. For DWI, section thickness was 6 mm. Because this was a retrospective study, MR spectroscopy was not routinely performed in this patient group.

### MR Imaging Data Collection

All MR images were retrospectively evaluated by 2 authors, a neonatologist and a neuroradiologist, both experienced in neonatal neuroimaging (G.v.W.-M. and L.L.; G.v.W.-M. having 16 and L.L. having 9 years of experience). Both reviewers were blinded to the infants’ identities and thus to the clinical history of the infants. DWI abnormalities were independently assessed on a 5-point scale. The confidence of the investigator for the detection of the abnormality was scored with a diagnostic confidence score, assigned by using a 5-point scale: definitely abnormal, probably abnormal, equivocal, probably normal, or definitely normal. In a consecutive consensus reading, final DWI abnormalities were assessed. In this consensus reading, conventional T1- and T2-weighted images were also assessed, and it was indicated whether brain injury was present and which type of injury pattern was present in each infant. Consensus was reached in all cases.<sup>24</sup>

### ADC Measurements

ADC measurements were independently performed in 30 standardized regions of the brain by 1 author (L.L.), who was blinded to the patient’s identity, by using Philips Medical Systems proprietary software. In addition, ADC measurements were performed in brain regions that appeared visibly abnormal on DWI. All measurements were retrospectively performed on the MR imaging operator console. All MR imaging

examinations were reloaded from the archives. Trace maps were used to calculate ADC values in all regions of interest. Because of image deformation in the DWI acquisition, regions of interest were identified on the original T2-weighted images and visually matched and positioned on the *b*=0 image of the DWI acquisition, which can be considered as fast T2-weighted echo-planar MR imaging. From there, the region of interest was copied onto the corresponding ADC map. Oval regions of interest were used for all regions. Regions of interest were drawn to include as much of the structure as possible. Care was taken to avoid inclusion of CSF in any region of interest. In both hemispheres, regions of interest were drawn in the white matter of the semioval center anteriorly and posteriorly, close to the central sulcus, head of the caudate nucleus, putamen and globus pallidus, posterior limb of the internal capsule (PLIC), frontal and posterior white matter at the level of the basal ganglia, medial and lateral part of the thalamus, middle cerebellar peduncle, temporal and occipital white matter, white matter in the cerebellar hemispheres, and the cerebral peduncles in the brain stem at the level of the red nucleus. Care was taken not to place the region of interest in the dentate nucleus or the cerebellar folia when measuring the cerebellar white matter. The area of each region of interest was 0.3–1 cm<sup>2</sup>, except in the PLIC and central sulcus, where the region-of-interest areas were 0.15–0.2 cm<sup>2</sup>.

### Statistical Analysis

All statistical analyses were performed by 1 author (J.v.d.G.) by using the Statistical Package for the Social Sciences software (SPSS for Windows, Version 14.0.2; SPSS, Chicago, Ill). To study whether outcome (adverse-favorable, abnormal-normal) differed between infants with and without visible DWI abnormalities, we used  $\chi^2$  tests. The non-parametric Mann-Whitney *U* test was used to analyze whether ADC values in visible DWI abnormalities and in normal-appearing brain regions displaying no visible abnormalities on conventional MR imaging, DWI, and ADC images correlated with the postnatal age at imaging. To investigate the predictive value on outcome of ADC values in each brain region, we used logistic regression analysis in which age at imaging was entered as a covariate. Receiver operating characteristic analysis was used to find optimal ADC cutoff values for each region for the various developmental outcome scores. A *P* < .05 was considered statistically significant.

## Results

### Outcome

Twenty-four infants (13 male) were included in this study. Mean age at MR imaging was 4.3 days (range, 1–9 days), mean postconceptional age was 41 weeks (range, 37<sup>+4</sup> – 43<sup>+3</sup> weeks). Of the infants who were included in this study, 10 were sedated; the other 15 infants did not require (additional) medication. MR imaging showed no prevailing HI injury pattern. Table 1 shows outcome in relation to the neonatal clinical classification. Outcome of the surviving infants was scored at the minimum age of 2 years (range, 2.08–5.75 years; mean, 3.75 years; median, 3.46 years; SD, 1.28). In all 7 children (4 males) who died (mean, 8.4 days after birth; median, 7 days; range, 4–13 days), the cause of death was respiratory failure and/or multiorgan failure due to perinatal asphyxia.

### DWI Findings

Despite considerable artifacts in the posterior fossa on DWI images, the cerebellum and brain stem could be assessed well for their signal intensity (SI). In 21 of the 24 neonates, the

**Table 1: Outcome in relation to neonatal clinical classification**

Neonatal classification According to Sarnat and Sarnat <sup>25</sup>	No.	Outcome			
		Normal (n = 6)	Mildly Abnormal (n = 1)	Definitely Abnormal (n = 10)	Died (n = 7)
HIE grade 1	3	2	0	1	0
HIE grade 2	18	4	1	9	4
HIE grade 3	3	0	0	0	3

**Note:**—HIE indicates hypoxic-ischemic encephalopathy.

**Table 2: ADC data of the normal-appearing brain tissue for the favorable and adverse outcome categories\***

	Mean		SD		Range	
	Favorable	Adverse	Favorable	Adverse	Favorable	Adverse
Semioval center anterior	1394.6	1337	62.3	228	1331–1479	979–1644
Semioval center posterior	1295.3	1282.5	41.8	258.8	1219–1346	943–1775
Central sulcus	983.9	977.9	84.6	147	806–1122	724–1248
Basal ganglia	1115.3†	994†	62.5	181.2	1033–1206	718–1388
Caudate head	1160.5	1120.4	77.8	173.9	1017–1298	838–1443
Frontal wm	1561.9	1499.1	158.6	273.8	1311–1768	1057–1942
Posterior wm	1483.1	1550.5	207.4	176.9	1133–1794	1247–1791
Medial thalamus	953.5	996.1	81.9	183.1	826–1103	756–1401
Lateral thalamus	930.6	939.7	83	205.6	810–1033	664–1412
PLIC	965.9	904.7	77.2	176.4	866–1099	626–1160
Brain stem	1075†	952.7†	108.6	137.2	920–1242	724–1182
Cerebellum	1106.6	1217.2	158.9	110.3	820–1384	975–1447
Occipital wm	1475	1332.4	156.4	198.8	1270–1706	984–1628
Temporal wm	1360	1318.6	62.2	144.5	1289–1474	1038–1611
Middle cerebellar peduncle	878.9	878.7	119.9	109.7	727–1115	655–1151

**Note:**—wm indicates white matter; ADC, apparent diffusion coefficient; PLIC, posterior limb of the internal capsule.

\* Data are shown calculated from the ADC value (in  $10^{-6}/\text{mm}^2/\text{s}$ ).

†  $P < .05$  between favorable and adverse outcome.

following 36 abnormalities were seen on DWI (Fig 1): 5 SI changes in the basal ganglia, 1 SI change in the thalamus, and 6 SI changes in the PLIC. Five abnormalities were recognized as arterial infarction; 6, as borderzone infarction; and 3 lesions, as punctate white matter lesions. In 10 infants, the white matter of the cerebral hemispheres had diffusely abnormal SI on DWI.

There was no difference in outcome between infants with and without visible DWI abnormalities. A significant correlation between ADC values in visible DWI abnormalities (in  $10^{-6}/\text{mm}^2/\text{s}$ ) and age at imaging was found only for the PLIC, showing a strong correlation between ADC values and postnatal age at imaging ( $R = 0.823$ ,  $P = .003$ ). ADC values in visibly abnormal regions on DWI did not have any predictive value for outcome (corrected for age at imaging).

### Normal-Appearing Brain Tissue Findings

Normal-appearing brain tissue displayed no visible abnormalities on conventional MR imaging, DWI, and ADC images. In 4 normal-appearing brain regions, ADC was significantly related to age at imaging. Higher ADC values were found with increasing age in the occipital white matter ( $R = 0.622$ ,  $P = .011$ ), temporal white matter ( $R = 0.578$ ,  $P = .024$ ), PLIC ( $R = 0.501$ ,  $P = .025$ ), and medial thalamus ( $R = 0.451$ ,  $P = .027$ ). In none of the other normal-appearing regions was a significant correlation found.

Table 2 shows the ADC values in the normal-appearing regions (on conventional MR imaging and DWI) for neonates of the favorable (groups 1–2) and adverse (group 3, death) outcome groups. In the normal-appearing basal ganglia and brain stem, we found significantly lower ADC values in the

subgroup of neonates with abnormal/adverse outcome than in infants with normal/favorable outcome. The ADC in both regions correlated significantly with outcome (corrected for age at imaging: basal ganglia,  $P = .03$  for abnormal,  $P = .01$  for adverse outcome; and brain stem,  $P = .006$  for abnormal,  $P = .03$  for adverse outcome). For none of the other normal-appearing brain regions were significant correlations found with outcome.

Tables 3–6 show the results of the receiver operating characteristic analyses (sensitivity, specificity, positive- and negative predictive values [PPVs, NPVs], and multiple cutoff values of ADC of the basal ganglia and brain stem) for abnormal (outcome groups, 2–3 and death) and adverse (outcome group 3 and death) outcomes, respectively. For abnormal outcome, the ADC cutoff level of the basal ganglia for a 100% sensitivity (0% specificity) is  $1357 \times 10^{-6}/\text{mm}^2/\text{s}$  and for a 100% specificity (67% sensitivity) is  $1018 \times 10^{-6}/\text{mm}^2/\text{s}$  ( $P = .035$ ). For adverse outcome, the ADC cutoff level for a 100% sensitivity (0% specificity) is  $1357 \times 10^{-6}/\text{mm}^2/\text{s}$  and for a 100% specificity (71% sensitivity) is  $1018 \times 10^{-6}/\text{mm}^2/\text{s}$  ( $P = .014$ ). For abnormal outcome, the ADC cutoff level of the brain stem for a 100% sensitivity (33% specificity) is  $1182 \times 10^{-6}/\text{mm}^2/\text{s}$  and for a 100% specificity (67% sensitivity) is  $988 \times 10^{-6}/\text{mm}^2/\text{s}$  ( $P = .006$ ). For adverse outcome, the ADC cutoff level for a 100% sensitivity (29% specificity) is  $1182 \times 10^{-6}/\text{mm}^2/\text{s}$  and for a 100% specificity (47% sensitivity) is  $897 \times 10^{-6}/\text{mm}^2/\text{s}$  ( $P = .03$ ).

For abnormal outcome, the ADC cutoff level of the basal ganglia for a 100% PPV (55% NPV) is  $1018 \times 10^{-6}/\text{mm}^2/\text{s}$  ( $P = .035$ ). For adverse outcome, the ADC cutoff level for a 100% PPV (64% NPV) is  $1018 \times 10^{-6}/\text{mm}^2/\text{s}$  ( $P = .014$ ). For

**Table 3: ROC analysis showing sensitivity, specificity, PPV, and NPV for abnormal outcome of multiple cutoff levels of ADC (in  $10^{-6}/\text{mm}^2/\text{s}$ ) of the basal ganglia\***

Cutoff Level	Sensitivity	95% CI†	Specificity	95% CI†	PPV	NPV
<574	6.67	1.1–32.0	100.00	54.1–100.0	100.0	30.0
<1018.5	66.67	38.4–88.1	100.00	54.1–100.0	100.0	54.5
<1036.5	66.67	38.4–88.1	83.33	36.1–97.2	90.9	50.0
<1109.5	80.00	51.9–95.4	50.00	12.4–87.6	80.0	50.0
<1174	86.67	59.5–98.0	16.67	2.8–63.9	72.2	33.3
<1239	93.33	68.0–98.9	0.00	0.0–45.9	70.0	0.0

Note:—ROC indicates receiver operating characteristic analysis; CI, confidence interval; PPV, positive predictive value; NPV, negative predictive value.

\* Area under the ROC curve = 0.767. Significance level  $P$  (area = 0.5) = .0347.

† 95% CI = 0.533–0.920.

**Table 4: ROC analysis showing sensitivity, specificity, PPV, and NPV for adverse outcome of multiple cutoff levels of ADC (in  $10^{-6}/\text{mm}^2/\text{s}$ ) of the basal ganglia\***

Cutoff Level	Sensitivity	95% CI†	Specificity	95% CI†	PPV	NPV
<574	7.14	1.2–33.9	100.00	58.9–00.0	100.0	35.0
<1018.5	71.43	41.9–91.4	100.00	58.9–100.0	100.0	63.6
<1061.5	78.57	49.2–95.1	71.43	29.3–95.5	84.6	62.5
<1104.5	78.57	49.2–95.1	57.14	18.8–89.6	78.6	57.1
<1148	85.71	57.2–97.8	28.57	4.5–0.7	70.6	50.0
<1239	92.86	66.1–98.8	0.00	0.0–41.1	65.0	0.0

\* Area under the ROC curve = 0.786. Significance level  $P$  (area = 0.5) = .0135.

† 95% CI = 0.554–0.931.

**Table 5: ROC analysis showing sensitivity, specificity, PPV, and NPV for abnormal outcome of multiple cutoff levels of ADC (in  $10^{-6}/\text{mm}^2/\text{s}$ ) of the brain stem\***

Cutoff Level	Sensitivity	95% CI†	Specificity	95% CI†	PPV	NPV
<736.5	5.56	0.9–7.4	100.00	54.1–100.0	100.0	26.1
<988	66.67	41.0–86.6	100.00	54.1–00.0	100.0	50.0
<995	66.67	41.0–86.6	83.33	36.1–97.2	92.3	45.5
<1093	83.33	58.6–96.2	50.00	12.4–87.6	83.3	50.0
<1151.5	94.44	72.6–99.1	33.33	5.3–77.3	81.0	66.7
<1182	100.00	81.3–100.0	33.33	5.3–77.3	81.8	100.0

\* Area under the ROC curve = 0.815. Significance level  $P$  (area = 0.5) = .0061.

† 95% CI = 0.605–0.941.

**Table 6: ROC analysis showing sensitivity, specificity, PPV, and NPV for adverse outcome of multiple cutoff levels of ADC (in  $10^{-6}/\text{mm}^2/\text{s}$ ) of the brain stem\***

Cutoff Level	Sensitivity	95% CI†	Specificity	95% CI†	PPV	NPV
<736.5	5.88	1.0–28.8	100.00	58.9–100.0	100.0	30.4
<897	47.06	23.0–72.1	100.00	58.9–100.0	100.0	43.7
<942.5	47.06	23.0–72.1	85.71	42.2–97.6	88.9	40.0
<1151.5	94.12	71.2–99.0	28.57	4.5–0.7	76.2	66.7
<1182	100.00	80.3–100.0	28.57	4.5–0.7	77.3	100.0

\* Area under the ROC curve = 0.756. Significance level  $P$  (area = 0.5) = .0305.

† 95% CI = 0.540–0.906.

abnormal outcome, the ADC cutoff level of the brain stem for a 100% PPV (50% NPV) is  $988 \times 10^{-6}/\text{mm}^2/\text{s}$  ( $P = .006$ ). For adverse outcome, the ADC cutoff level for a 100% PPV (44% NPV) is  $897 \times 10^{-6}/\text{mm}^2/\text{s}$  ( $P = .03$ ).

## Discussion

The aim of this study was to investigate the value of DWI and ADC for outcome prediction until early school age in neonates with HIE. Although ADC values in visibly abnormal brain tissue on DWI did not correlate with outcome, ADC of the normal-appearing basal ganglia and brain stem correlated with outcome, independent of all MR imaging findings, including DWI.

Apart from case reports, only a few published studies have so far addressed the predictive value of ADC measurements in

neonates with HI brain damage.<sup>10,12,13,21,23</sup> Wolf et al<sup>12</sup> studied 13 term neonates with suggested HIE within 12 days after birth. Clinical follow-up was short, but not specified. ADC values were measured in predefined brain regions; no distinction was made between regions with visible DWI abnormalities and normal-appearing regions. Wolf et al<sup>12</sup> found decreased ADC values in the PLIC, corona radiata, posterior frontal white matter, and parietal white matter in patients with HIE compared with control subjects, but they did not assess the predictive value of ADC values for outcome.

Rutherford et al<sup>13</sup> studied 63 term neonates who presented with early seizures, of whom 49 with HIE had undergone repetitive MR imaging. Reduced ADC in the centrum semiovale, anterior and posterior white matter at the level of the basal ganglia, central sulcus, lentiform nucleus, medial and lateral

thalamus, PLIC, brain stem, and cerebellum allowed early detection of infarction. However, this study did not investigate the relation between ADC and long-term clinical follow-up. Boichot et al<sup>21</sup> studied the predictive value of conventional MR imaging and DWI for neurologic outcome in 30 term neonates with severe HIE. Imaging was performed in the first 12 days after birth; outcome was evaluated after at least 12 months. A mixed pattern of cortical and basal ganglia SI abnormalities on MR imaging was associated with unfavorable outcome. Significantly reduced ADC values were noted in all measured brain regions, especially the basal ganglia, in the unfavorable outcome group but only if MR imaging was performed during the first 6 days after birth.

To our knowledge, the study by L'Abée et al<sup>23</sup> is the only one relating DWI to longer follow-up until 24 months of age in a group of 11 asphyxiated neonates. ADC values were measured in the basal ganglia and the periventricular white matter of the parieto-occipital region, and neurodevelopment was assessed in survivors at 24 months. Nine of the 11 neonates had a poor outcome. ADC values in the basal ganglia were abnormally low in 5 and in the parietal white matter in 4 of the 7 patients who died. Although low ADC values had predictive value, normal ADC values were also seen in children with poor outcome. In none of these studies was ADC related to follow-up longer than infancy.

The most important result of our study is that ADC values in the basal ganglia and brain stem were predictive of outcome. The ADC values in the normal-appearing brain stem and basal ganglia in infants with perinatal asphyxia correlated with abnormal or adverse outcome, independent of all MR imaging findings including DWI; low ADC values were associated with abnormal/adverse outcome and higher ADC values, with normal/favorable outcome. Normal-appearing brain tissue displayed no visible abnormalities on conventional MR imaging, DWI, and ADC images. Our finding is in accordance with several conventional MR imaging studies showing motor outcome to be related to the severity of basal ganglia and internal capsule involvement in infants with HIE.<sup>4,5,28-30</sup>

Our finding is also in agreement with the results of several other studies on ADC measurements in neonatal HIE. Boichot et al<sup>21</sup> found reduced ADC in the basal ganglia in infants with abnormal outcomes after neonatal HIE. However, they did not discriminate between regions with visible DWI abnormalities and normal-appearing regions. L'Abée et al<sup>23</sup> found abnormally low ADC values in the basal ganglia in 5 of 7 patients who died. Again, no discrimination between regions with visible DWI abnormalities and normal-appearing regions was made. In a group of neonates with HIE, Vermeulen et al<sup>20</sup> showed lower ADC in the brain stem compared with that of controls. They did not relate ADC values to outcome. Our study also seems to be in agreement with Barkovich et al,<sup>31</sup> who showed that on follow-up imaging, abnormalities may be seen in regions of formerly normal-appearing white and gray matter. In other words, brain tissue may be abnormal despite normal appearance on (early) MR imaging. We, therefore, hypothesize that quantitative ADC measurements are more reliable in detecting abnormal brain tissue than visual analysis of conventional and DWI images.

In our clinical setting, the other important finding was that ADC values in visibly abnormal regions on DWI did not have any significant predictive value for outcome (corrected for age at imaging). There are 2 probable explanations for this remarkable finding. First, we studied a group of infants with HIE having various HI brain lesions. Possibly, if we had selected a large group of infants with a specific type of brain injury, we would have found a predictive value of ADC for outcome in abnormal-appearing regions as did Hunt et al.<sup>19</sup> They showed that high ADC values in the PLIC were associated with survival in term infants with HIE. The lowest ADC values in the PLIC were found in survivors with severe disability and in survivors with global brain injury. Second, we imaged infants between 1 and 10 days after birth. Although 13 of 24 infants underwent imaging between 1 and 4 days after birth and only 2 infants were older than 7 but younger than 10 days, timing of imaging was still variable. It is well known that ADC values vary with time after HI as a result of the ongoing pathologic processes and that areas of abnormal diffusivity may "pseudonormalize" within the first 2 weeks of life.<sup>31</sup>

We found a strong association only between the ADC value of the PLIC, either visibly abnormal or normal, and postnatal age at imaging. Other authors have reported abnormal ADC values in injured brain tissue during the first week after the HI event; ADC values later became higher before returning to normal values.<sup>11-13,18-22</sup> Our finding may be explained by the fact that our group was relatively small and heterogeneous. It is possible that if a larger number of infants had been studied, we would have found associations between ADC values and postnatal age at imaging in more structures.

As mentioned previously, an imperfection of our study may be the timing of the MR imaging examinations, taking place up to 10 days after birth, whereas on DWI, SI abnormalities gradually diminish and are most obvious between 1 and 4 days after the incident.<sup>11,13,32</sup> Although postnatal age at imaging was used as a covariate in our analyses, it would have been more appropriate to consider time since the inciting event. However, in most cases of perinatal asphyxia, the exact time of the inciting event is difficult to determine.<sup>1</sup> Another limitation is that we did not perform follow-up imaging in the first 2 weeks after birth; normal ADC values do not exclude the presence of abnormal tissue in neonates with HI brain damage.<sup>13,31</sup> Finally, because of the heterogeneity of the group we studied, showing various injury patterns, the number of infants with specific injury patterns was limited. This may have influenced our results, showing no predictive value of ADC in brain tissue appearing abnormal on DWI.

## Conclusions

We conclude that in neonates with HIE, low ADC values of the normal-appearing basal ganglia and brain stem correlate with abnormal or adverse outcome, independently of all imaging findings. In this group of neonates with heterogeneous injury patterns, ADC values in visibly abnormal brain tissue on DWI did not have predictive value for outcome.

## Acknowledgments

We thank S. Servaas for his help with data collection.

## References

1. Cowan F, Rutherford M, Groenendaal F, et al. **Origin and timing of brain lesions in term infants with neonatal encephalopathy.** *Lancet* 2003;361:736–42
2. Cowan F. **Outcome after intrapartum asphyxia in term infants.** *Semin Neonatol* 2000;5:127–40
3. Rutherford MA. **The asphyxiated term infant.** In: Rutherford MA, ed. *MRI of the Neonatal Brain*. London: WB Saunders; 2002:99–128
4. Rutherford MA, Pennock JM, Counsell SJ, et al. **Abnormal magnetic resonance signal in the internal capsule predicts poor neurodevelopmental outcome in infants with hypoxic-ischemic encephalopathy.** *Pediatrics* 1998;102:323–28
5. Cowan FM, de Vries LS. **The internal capsule in neonatal imaging.** *Semin Fetal Neonatal Med* 2005;10:461–74
6. Barkovich AJ. **Brain and spine injuries in infancy and childhood.** In: Barkovich AJ, ed. *Pediatric Neuroimaging*. Philadelphia: Lippincott Williams & Wilkins; 2005:190–290
7. Rutherford M, Pennock J, Schwieso J, et al. **Hypoxic-ischaemic encephalopathy: early and late magnetic resonance imaging findings in relation to outcome.** *Arch Dis Child Fetal Neonatal Ed* 1996;75:F145–51
8. Cowan FM, Pennock JM, Hanrahan JD, et al. **Early detection of cerebral infarction and hypoxic ischemic encephalopathy in neonates using diffusion-weighted magnetic resonance imaging.** *Neuropediatrics* 1994;25:172–75
9. Inder T, Huppi PS, Zientara GP, et al. **Early detection of periventricular leukomalacia by diffusion-weighted magnetic resonance imaging techniques.** *J Pediatr* 1999;134:631–34
10. Liu AY, Zimmerman RA, Haselgrove JC, et al. **Diffusion-weighted imaging in the evaluation of watershed hypoxic-ischemic brain injury in pediatric patients.** *Neuroradiology* 2001;43:918–26
11. Forbes KP, Pipe JG, Bird R. **Neonatal hypoxic-ischemic encephalopathy: detection with diffusion-weighted MR imaging.** *AJNR Am J Neuroradiol* 2000;21:1490–96
12. Wolf RL, Zimmerman RA, Clancy R, et al. **Quantitative apparent diffusion coefficient measurements in term neonates for early detection of hypoxic-ischemic brain injury: initial experience.** *Radiology* 2001;218:825–33
13. Rutherford M, Counsell S, Allsop J, et al. **Diffusion-weighted magnetic resonance imaging in term perinatal brain injury: a comparison with site of lesion and time from birth.** *Pediatrics* 2004;114:1004–14
14. Neil JJ, Shiran SI, McKinstry RC, et al. **Normal brain in human newborns: apparent diffusion coefficient and diffusion anisotropy measured by using diffusion tensor MR imaging.** *Radiology* 1998;209:57–66
15. Lovblad KO, Schneider J, Ruoss K, et al. **Isotropic apparent diffusion coefficient mapping of postnatal cerebral development.** *Neuroradiology* 2003;45:400–03
16. Tanner SF, Ramenghi LA, Ridgway JP, et al. **Quantitative comparison of intra-brain diffusion in adults and preterm and term neonates and infants.** *AJR Am J Roentgenol* 2000;174:1643–49
17. Toft PB, Leth H, Peitersen B, et al. **The apparent diffusion coefficient of water in gray and white matter of the infant brain.** *J Comput Assist Tomogr* 1996;20:1006–11
18. Barkovich AJ, Westmark KD, Bedi HS, et al. **Proton spectroscopy and diffusion imaging on the first day of life after perinatal asphyxia: preliminary report.** *AJNR Am J Neuroradiol* 2001;22:1786–94
19. Hunt RW, Neil JJ, Coleman LT, et al. **Apparent diffusion coefficient in the posterior limb of the internal capsule predicts outcome after perinatal asphyxia.** *Pediatrics* 2004;114:999–1003
20. Vermeulen RJ, Fetter WP, Hendriks L, et al. **Diffusion-weighted MRI in severe neonatal hypoxic ischaemia: the white cerebrum.** *Neuropediatrics* 2003;34:72–76
21. Boichot C, Walker PM, Durand C, et al. **Term neonate prognoses after perinatal asphyxia: contributions of MR imaging, MR spectroscopy, relaxation times, and apparent diffusion coefficients.** *Radiology* 2006;239:839–48
22. Zarifi MK, Astrakas LG, Poussaint TY, et al. **Prediction of adverse outcome with cerebral lactate level and apparent diffusion coefficient in infants with perinatal asphyxia.** *Radiology* 2002;225:859–70
23. L'Abée C, de Vries LS, van der Grond J, et al. **Early diffusion-weighted MRI and 1H-magnetic resonance spectroscopy in asphyxiated full-term neonates.** *Biol Neonate* 2005;88:306–12
24. Liauw L, van der Grond J, van den Berg-Huysmans AA, et al. **Hypoxic-ischemic encephalopathy: diagnostic value of conventional MR imaging pulse sequences in term-born neonates.** *Radiology* 2008;247:204–12
25. Sarnat HB, Sarnat MS. **Neonatal encephalopathy following fetal distress: a clinical and electroencephalographic study.** *Arch Neurol* 1976;33:696–705
26. Gesell A, Amatruda CS. **Developmental diagnosis: normal and abnormal child development.** In: Knobloch HPBH, ed. *Developmental Diagnosis; the Evaluation and Management of Normal and Abnormal Neuropsychologic Development in Infancy and Early Childhood*. 3rd ed. New York: Harper and Row; 1974
27. Brouwers-de Jong EA, Burgmeijer RJF, Laurent de Angulo MS. **Ontwikkelingsonderzoek op het consultatiebureau. Handboek bij het vernieuwde Van Wiechenonderzoek.** [in Dutch] Assen, the Netherlands: Van Gorcum; 1996;1–343
28. Krageloh-Mann I, Helber A, Mader I, et al. **Bilateral lesions of thalamus and basal ganglia: origin and outcome.** *Dev Med Child Neurol* 2002;44:477–84
29. Mercuri E, Barnett AL. **Neonatal brain MRI and motor outcome at school age in children with neonatal encephalopathy: a review of personal experience.** *Neural Plast* 2003;10:51–57
30. Rutherford M, Srinivasan L, Dyet L, et al. **Magnetic resonance imaging in perinatal brain injury: clinical presentation, lesions and outcome.** *Pediatr Radiol* 2006;36:582–92
31. Barkovich AJ, Miller SP, Bartha A, et al. **MR imaging, MR spectroscopy, and diffusion tensor imaging of sequential studies in neonates with encephalopathy.** *AJNR Am J Neuroradiol* 2006;27:533–47
32. Mader I, Schoning M, Klose U, et al. **Neonatal cerebral infarction diagnosed by diffusion-weighted MRI: pseudonormalization occurs early.** *Stroke* 2002;33:1142–45