

Are your **MRI contrast agents** cost-effective?

Learn more about generic **Gadolinium-Based Contrast Agents**.



**FRESENIUS  
KABI**

caring for life

**AJNR**

## **Long-Term Outcome after Coil Embolization of Cavernous Sinus Arteriovenous Fistulas**

A. Bink, K. Goller, M. Lichtenberg, T. Neumann-Haefelin, S. Dützmann, F. Zanella, J. Berkefeld and R. du Mesnil de Rochemont

This information is current as of April 19, 2024.

*AJNR Am J Neuroradiol* published online 18 March 2010  
<http://www.ajnr.org/content/early/2010/03/18/ajnr.A2040.citation>

ORIGINAL  
RESEARCH

A. Bink  
K. Goller  
M. Luchtenberg  
T. Neumann-Haefelin  
S. Dützmann  
F. Zanella  
J. Berkefeld  
R. du Mesnil de  
Rochemont



## Long-Term Outcome after Coil Embolization of Cavernous Sinus Arteriovenous Fistulas

**BACKGROUND AND PURPOSE:** Cranial nerve palsies are regularly observed in patients with arteriovenous fistulas of the cavernous sinus. The purpose of our study was to determine the long-term clinical outcome—with a special focus on extra-ocular muscular dysfunctions—in patients who had undergone endovascular treatment of a cavernous sinus fistula with detachable coils.

**MATERIALS AND METHODS:** Sixteen patients were recalled for an ophthalmoneurologic control examination (mean interval of 4.4 years). The mRS and the EQ-5D questionnaire were used for the description of general outcome. Age, duration of symptoms, character of the fistula (direct, dural), and coil volume were tested to assess their relevance for persistent symptoms.

**RESULTS:** All patients displayed complete regression of chemosis, exophthalmus, and pulsating tinnitus with no evidence of recurrences. Oculomotor disturbances persisted in 9 of 13 patients and caused permanent diplopia in 7 patients. In 15 patients a mRS score of 1 or 2 was achieved; however, 7 patients reported some limitations in life quality (EQ-5D). A significant correlation was found between coil volume and persistent diplopia ( $P = .032$ ) and persistent cranial nerve VI paresis ( $P = .037$ ).

**CONCLUSIONS:** Coil embolization of the cavernous sinus led to durable closure of AVF and reliable regression of acute symptoms. However, long-term follow-up showed a 44% rate of persistent cranial nerve deficits with disturbances of oculomotor and visual functions. This may be explained by the underlying fistula size itself and/or the space-occupying effect of the coils. As neuro-ophthalmologic outcome is crucial for control of therapeutic success, patients should be routinely examined by ophthalmologists.

**ABBREVIATIONS:** AVF = arteriovenous fistula; CNP = cranial nerve palsies; CS = cavernous sinus; ICA = internal carotid artery; LR = likelihood ratio; mRS = modified Rankin Scale; na = not available; SOV = superior ophthalmic vein

In a recent retrospective study we analyzed the technical success and acute complication rates in patients with direct or dural AVF after endovascular coil packing of the cavernous sinus.<sup>1</sup> Although the initial results showed a rapid regression of acute symptoms such as chemosis, exophthalmus, and progressive visual loss, cranial nerve deficits persisted in the early postinterventional phase. CNP may occur due to the fistula or as a complication of endovascular treatment.<sup>1-10</sup> Periprocedural aggravation or new CNP as well as preinterventional neuro-ophthalmic problems are reported to have a good prognosis.<sup>2</sup> Most previous studies gave an overall rating of the clinical outcome in patients following endovascular treatment of the AVF of the cavernous sinus without reporting the detailed neuro-ophthalmologic findings. In the early follow-up of patients with cavernous sinus AVF, we had the impression that incomplete regression of CNP is more common than has been reported in the literature. The use of coils as embolization material harbors the theoretic disadvantage that coil packing may cause a permanent space-occupying effect on cranial nerves running through the cavernous sinus.

The aim of this study was to evaluate the long-term out-

come in patients embolized with coils to obtain more detailed information about the general and neuro-ophthalmologic outcome in patients with cavernous sinus AVF and to compare this with the published data.

### Materials and Methods

Between 2001 and 2007 a total of 19 consecutive patients with direct ( $n = 13$ ) or dural ( $n = 6$ ) AVF with involvement of the cavernous sinus received endovascular treatment with transarterial or transvenous coil packing. In cases with direct AVF, a primary transarterial approach was used, and in dural AVF, a transvenous route through the inferior petrosal sinus was used.<sup>1</sup> If transarterial embolization failed to reach the target or remained incomplete, a transvenous approach through the inferior petrosal sinus or, in 1 case, a retrograde approach via the facial and ophthalmic veins was used.<sup>1</sup> Once the cavernous sinus was reached, the aim of the procedure was to catheterize and embolize the compartments with outflow to dangerous venous connections to the ophthalmic or cortical veins.<sup>1</sup> In most cases the fistulas needed additional dense coil packing of large parts of the cavernous sinus from the anterior to the posterior part to close it. More detailed technical information concerning the endovascular procedures has been provided previously.<sup>1</sup>

Before intervention, fistulas were classified on the basis of their arterial supply and venous drainage patterns.<sup>1</sup> The compartments of the cavernous sinus affected by the fistula as well as the compartments with dense coil packing were determined in relationship to cranial nerve compartmental anatomy according to the scheme of Nishino et al.<sup>2</sup> These evaluations were performed retrospectively, via consensus, by 2 experienced neuroradiologists blinded to the clinical symptoms.

We reviewed the records of these patients and obtained informed

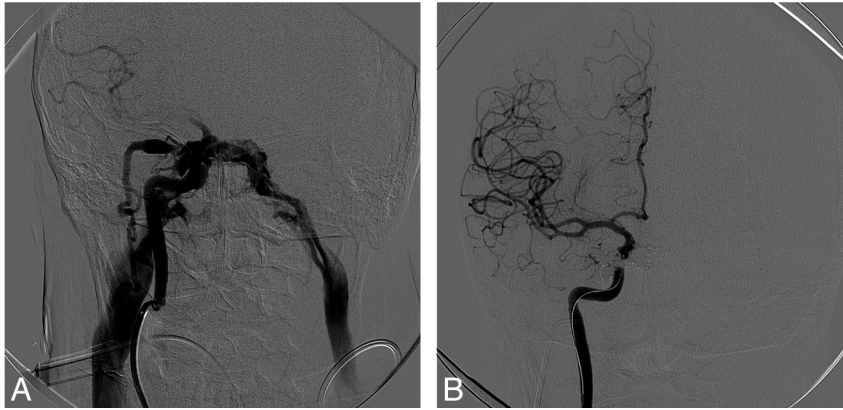
Received October 12, 2009; accepted after revision December 28.

From the Department of Neuroradiology (A.B., K.G., F.Z., J.B., R.M.R.), Department of Ophthalmology (M.L.), Department of Neurology (T.N.-H.), and Department of Neurosurgery (S.D.), Goethe-University, Frankfurt/Main, Germany.

Please address correspondence to Andrea Bink, MD, Department of Neuroradiology, Goethe-University, Schleusenweg 2-16, Haus 95, D-60528 Frankfurt am Main, Germany; e-mail: andrea.bink@kqu.de

Indicates article with supplemental on-line tables.

DOI 10.3174/ajnr.A2040



**Fig 1.** A, Digital subtraction angiography of the right ICA showing a direct cavernous sinus fistula with bilateral outflow into the inferior petrosal sinus and the right ophthalmic vein. B, Final digital subtraction angiography of the right ICA after transarterial and transvenous coil embolization with complete occlusion of the AVF.

consent for extended neuro-ophthalmologic examination at the next scheduled routine follow-up. The examination consisted of a neuro-ophthalmologic examination performed by ophthalmologists including the following parameters: cranial nerve functions, visual deficits, intraocular pressure, exophthalmus, ptosis, chemosis, pain, and pulsating tinnitus. Trochlear nerve function was not assessed in patients with oculomotor deficits because it is difficult to evaluate trochlear dysfunction when other cranial nerve palsies are present.<sup>2</sup> The clinical outcome for each parameter was stratified into cured (when the symptom no longer existed), improved (when the intensity had decreased), unchanged, or worsened (when symptoms had worsened or new symptoms had developed).<sup>11</sup>

The patients were queried about headache, vertigo, pulsatile and nonpulsatile tinnitus, and gait disturbance. If headache was reported patients filled in the Headache Impact Test (HIT-6) questionnaire.<sup>12</sup>

The patients were rated on the mRS<sup>13</sup> and asked to assess their health state by answering the EQ-5D<sup>14</sup>; they were also asked to indicate their mental status on a numeric analog scale ranging from 0 (worst possible condition) to 10 (best possible condition). Additionally, patients were asked to compare their current health state with the state before the onset of symptoms and the state immediately before the intervention. Because it is difficult for patients to differentiate exactly between fistula-related symptoms and symptoms of other origin, especially in the long term, they were asked about their general health state.

Additional information about the patients' preinterventional and postinterventional health state was provided by the ophthalmologic data base of each patient during the hospital stay and, when existent, by external charts.

For each patient the cumulative coil volume was calculated. For this purpose, the volumes of each coil as given by the manufacturers were added.

### Statistical Analysis

Age, duration of symptoms, character of the fistula (dural/direct), and coil volume were tested as independent variables for their relevance for persistence of symptoms and neurologic deficits (CNP of III, V, and VI, diplopia, ptosis, visual loss, headache, disturbance of pupillary function, anisocoria). A logistic regression model with backward elimination was used.<sup>15</sup>

The Kruskal-Wallis test was used to test whether the cumulative coil volume had an impact on the quality of CNP (unchanged, improved, resolved) at the time of follow-up.<sup>16</sup>

Whether the access had an effect on the number of symptoms at follow-up was determined with the Kruskal-Wallis test.

Statistical significance was defined as a *P* value of  $<.05$ .

### Results

Sixteen (1 man and 15 women; mean age, 66 years; range, 28–88 years) out of 19 patients who fulfilled the inclusion criteria consented to participate in the follow-up study. Three patients were not available for follow-up: 2 had moved without leaving an address, and 1 patient had died of an unknown cause.

#### Acute Treatment of the Fistula

The mean interval between the onset of clinical symptoms and treatment of the fistula was 42 days (median, 25 days; range, 3–131 days). A total of 11 patients had a direct fistula, and 5 had a dural fistula. Of the 11 patients with a direct fistula, 3 patients had a trauma and 4 patients a ruptured aneurysm. In 4 patients no definite etiology was found. All patients showed a venous drainage into the superior orbital vein; 7 had additional cortical venous drainage.

A total of 14 patients (including 1 patient with bilateral fistulas) were treated in 1 session, 2 sessions were needed in 1 patient, and 3 sessions were needed in another patient. Access to the cavernous sinus was singly transvenous in 9 patients; 5 patients had a transarterial access, and 2 patients had a mixed access. In our patients no correlation was found between access and outcome ( $P = .684$ ).

The mean number of coils used was 24 (median, 18; range, 3–47), and the mean total coil volume was 196.4 mm<sup>3</sup> (median, 143 mm<sup>3</sup>; range, 70–577 mm<sup>3</sup>).

With the exception of a subtotally occluded AVF with a minor residual shunt, coil packing of the cavernous sinus was technically successful and led to complete closure of the fistulas. An example of a total occlusion of trauma-induced direct cavernous sinus fistula is given in Fig 1. In 13 of 16 cases, analysis of the compartments involved in the fistula could predict clinical cranial nerve deficits either exactly ( $n = 7$ ) or partly ( $n = 6$ ). There was only partial congruence between those compartments and compartments with dense coil packing. Details of compartmental analysis in relationship to CNP in the acute phase and during follow-up are given in On-line Table 1.

### **Follow-up: Ocular Symptoms and Neurologic Deficits**

The mean interval between treatment and the follow-up examination was 4.4 years (median, 2.1 years; range, 10–92 months).

The early peri-interventional course has been described in detail elsewhere.<sup>1</sup> On-line Table 2 illustrates the course of the ocular symptoms and neurologic deficits over the long term.

Detailed examination revealed that ptosis existed in 8 patients and had regressed completely in 3 patients. In 1 patient ptosis was profound; in the other 4 it was subtle. Ptosis was only present in patients who also had oculomotor deficits. Ptosis was not described in the early postoperative phase reports taken as the source for a previous study.<sup>1</sup> The same is true for the subtle disturbances of oculomotor function found in 4 patients that were not documented during the preinterventional or early postinterventional period. In our recent retrospective evaluation, we were able to include data from our ophthalmologic university patient data base, which led to the higher amount of deficiencies.

No patient worsened or developed new symptoms suspicious for a recurrent fistula. None of the patients had an occlusion of the ICA, and in the follow-up examination no patient presented with symptoms of cerebral infarction. The amount of fistula-related symptoms decreased between the peri-interventional phase and follow-up (no symptoms [follow-up versus peri-interventional]: 3 versus 0 patients; up to 3 symptoms: 12 versus 7 patients; up to 5 symptoms: 1 versus 9 patients). Four patients with direct fistulas had persistent deficits of oculomotor function without major improvement of double vision or ptosis at follow-up. There was no clear-cut correlation between pretherapeutic and posttherapeutic compartment anatomy and the outcome regarding cranial nerve deficits (On-line Table 1).

On-line Table 3 gives an overview of visual acuity, vertigo, nonpulsating tinnitus, gait disturbance, and headache for each patient.

In the follow-up examination, 1 patient had persistence of the initial visual loss because of venous stasis retinopathy (On-line Tables 2 and 3). One patient's initial acute visual deficits (On-line Table 3, no. 14) showed improvement (On-line Table 2). Other patients' visual deficits were unrelated to the fistula (On-line Table 3).

In 3 patients with vertigo an orthostatic origin was underlying. One patient reported with vertigo since the traumatic fistula.

A total of 9 patients reported nonpulsating tinnitus, while 8 described a nonpermanent noise in the ear. One patient with occlusion of bilateral fistulas reported a permanent noise in both ears 1 year after the endovascular procedure. Repeat-angiography revealed total occlusion of both fistulas and no new fistula. Two patients had gait disturbances due to ocular symptoms. In 1 patient diplopia and in the other patient visual field deficits in connection with feet problems developing after the trauma-induced fistula were responsible for the gait disturbances.

Headache was present in 6 of 16 patients. In the HIT-6 questionnaire, scores from 40 to 63 points were reached (patient 1, 49; patient 3, 55; patient 5, 41; patient 8, 54; patient 14, 63; patient 16, 40). In 2 patients headache had no or minimal influence on everyday life, and in 3 patients headaches had

little influence on everyday life. One patient's score revealed that headache had a strong impact on her life. This headache was reported after a trauma-induced fistula. The patient had a V1 lesion and the headache was interpreted to be neuropathic. Intraocular pressure was normal in all patients (mean value right eye, 15.6 mm Hg; mean value left eye, 15.4 mm Hg).

### **General Outcome and Quality of Life**

An mRS score of 1 ("no significant disability") was attained by 75%, a score 2 ("slight disability") by 19%, and a score of 3 ("moderate disability") was attained by 6% of patients. No patient had an mRS score of 0 or 4–6.

Analysis of the scores on the EQ-5D numeric analog scale (worst indicated by 0, best state indicated by 100) revealed a mean score of 76 based on the patients' self-assessments of their general state of health. The results of the other EQ-5D dimensions are summarized in On-line Table 4.

In the self-assessment of mental state, the mean overall value was 7.25 (worst indicated by 0, best possible condition indicated by 10). In total, 75% of the patients rated their health state as better or similar in comparison to the time before the onset of symptoms. Three patients reported a similar general health state in comparison with the time before the intervention and with the time before the onset of symptoms. Four patients rated their health as worse than before the onset of symptoms: 2 patients said they were not as resilient as before, and 1 patient reported shoulder pain. One woman claimed a worse health state in comparison with the time before the onset of symptoms and the time just before the intervention. She had a polytrauma caused by a car crash and a traumatic AVF. She suffered from strong headache (HIT-6 score of 63 points), permanent back pain, knee and feet pain, inner restlessness, and not being as resilient as before.

### **Statistical Analysis**

The cumulative volume of the detached coils ranged from 70 to 577 mm<sup>3</sup>. In patients with unchanged cranial nerve VI paresis (group 1), mean coil volume was 324 mm<sup>3</sup>; in patients with improved cranial nerve VI paresis (group 2), it was 243 mm<sup>3</sup>. In patients with cured cranial nerve VI paresis (group 3), the mean coil volume was 116 mm<sup>3</sup>. The Kruskal-Wallis test did not show significant differences in cumulative coil volume between the 3 groups ( $P = .063$ ).

Individual tests performed with the logistic regression model (age, duration of symptoms, character of the fistula, and total coil volume) showed a significant correlation for coil volume versus persistent diplopia ( $P = .032$ ) and coil volume versus persistent cranial nerve VI paresis ( $P = .037$ ).

The overall LR test of the complete logistic regression model (dependent variable: diplopia at follow-up; tested variables: age, duration of symptoms, character of the fistula, coil volume) was  $P = .003$  (Nagelkerke  $R^2 = 0.84^{15}$ ).

The overall LR test of the complete logistic regression model with cranial nerve VI paresis as a dependent variable was  $P = .021$  ( $R^2 = 0.69$ ).

In the individual tests none of the tested independent variables had a significant  $P$  value concerning persistence of cranial nerve III paresis. In the complete model the overall LR test was significant with  $P = .032$  ( $R^2 = 0.68$ ). No new aspects were

revealed by the backward elimination of the logistic regression, and no other significant results were found.

## Discussion

According to the results of this follow-up study, coil embolization has proved to be a stable and durable treatment for closure of AVF of the cavernous sinus. After a mean follow-up interval of 53 months, no patient had worsened symptoms or symptoms suspicious for recurrent AVF such as pulsating tinnitus, chemosis, or exophthalmus. However, cranial nerve deficits and consecutive ophthalmologic symptoms regressed only partly in most cases, and residuals of these deficits were frequently found, causing permanent morbidity and some limitation of quality of life. Despite their symptoms, most patients were in a good general condition as shown by the results of mRS, numeric analog scale, structured interview, and EQ-5D.

The course of patients with AVF of the cavernous sinus has been the subject of many studies. Complete regression or improvement of symptoms due to spontaneous thrombosis is reported in 25%–90% of cases.<sup>17–20</sup> Whereas these reports include all types of cavernous sinus fistula, a previous study on patients with Barrow type B fistulas and without embolization found clinical cure in 69.6% of patients and improvement in 13% of patients.<sup>21</sup>

For many years balloon embolization was the criterion standard for the treatment of direct AVF of the cavernous sinus. Permanent CNP were reported early on as a complication in 16%–63% of patients with initial CNP after the use of balloon embolization to treat cavernous sinus fistulas.<sup>22–24</sup> The reported percentages of permanent CNP after coil embolization are comparable to treatment with balloons. However, the comparability of the studies is limited by the different outcome definitions and the described details of ocular symptoms. Some studies mention only the existence of ocular symptoms, while others provide a detailed analysis of the cranial nerves involved. The number of patients included differs with a wide range, and only about every second paper mentions CNP in the follow-up. Therefore, in this series outcome was not measured as a summarized overall category. Because AVF of the cavernous sinus presents mostly with orbital and neuro-ophthalmic symptoms,<sup>11</sup> emphasis was placed on a detailed ophthalmologic and cranial nerve report. Concerning coil embolization a wide range (ie, 3%–50%) of permanent CNP was found in studies with patient populations of between 4 and 31.<sup>7,25,26</sup> The follow-up examinations performed in 69 patients after coil embolization of dural cavernous sinus fistulas revealed 5.5% residual symptoms, which were mostly CNP.<sup>27</sup> Our detailed results are less optimistic concerning regression of CNP, reporting about 9 of 16 patients with permanent CNP, including 5 with improved CNP. However, the overall results after coil embolization are promising; this result has been documented (On-line Table 2).

Analysis with the logistic regression model revealed the independent variable coil volume as significant for persistent cranial nerve VI paresis and diplopia. Together, the tested independent variables seem to have an impact on persistent cranial nerve III paresis. Neither duration of symptoms, dural or direct origin of the fistula, or age proved to be relevant concerning residual symptoms or neurologic deficits.

One possible explanation for this finding is a permanent pressure of the coils on the neural structures running through the cavernous sinus. Furthermore, although no statistical significance was found, the hypothesis of a space-occupying effect appears to be supported by the observation that mean cumulative coil volume increased from patients with cured cranial nerve VI paresis (116 mm<sup>3</sup>) to patients with improved cranial nerve VI paresis (243 mm<sup>3</sup>) and individuals with unchanged cranial nerve VI paresis (324 mm<sup>3</sup>). Although our hypothesis seems to be confirmed by these results, note that the reported rate of persistent CNP after balloon occlusion of cavernous sinus AVF may also be very high; however, it is well-known that all balloons deflate with time so that mechanical compression is resolvable. Therefore, another possible theory for the correlation between volume of coils and the persistence of CNP should be considered: the fact that a more substantial vessel wall injury supposes a higher risk of cranial nerve injury through mechanical and ischemic cranial nerve damage, and, consequently, a larger coil volume is needed for closure of a larger fistula.

Analysis of compartmental anatomy of the cavernous sinus proved some correspondence between radiologically expected, clinically present CNP and densely packed compartments. However, only 2 of 4 patients with unchanged CNP had dense coil packing of critical compartments. The lack of new or progressive CNP after coiling favors the hypothesis that the initial damage of the fistula is more important than secondary treatment effects.

Analysis of compartmental anatomy for the purpose of targeted coiling of the fistula is of limited value in most patients for several reasons: the complexity of the cavernous sinus and the high opaqueness due to contrast material seen in high-flow fistulas sometimes makes exact localization of the fistulous point and estimation of the size of the arteriovenous connection extremely difficult. Limitation of coiling to the compartment of the fistula harbors the risk of incomplete closure and shifting of venous drainage into cortical or ocular veins if microcatheter access to compartments with dangerous venous drainage is blocked.

Thus, the chosen strategy of coiling compartments with orbital or cortical venous drainage first before final occlusion of the fistula seems to be safer for most patients until more efficient embolization techniques for local closure of the fistulous site are developed. To close a fistula completely with the use of the currently available detachable coils demands dense coil packing of large parts of the cavernous sinus in most cases.

A final comparison of our results with other long-term follow-up studies is not possible due to a lack of data on coil volumes. In a recent study on CNP as a peri-interventional complication occurring in 39.4% of patients either as aggravation or new CNP, a coil volume >200 mm<sup>3</sup> was reported to be critical.<sup>2</sup> Alternative to dense packing of the whole sinus, some authors have described targeted embolization, especially in dural AVF of the cavernous sinus aimed at the involved compartment after careful delineation of the precise fistulous point.<sup>28–30</sup> This could be an alternative with a lower chance of persistent CNP. As an alternative treatment option for direct cavernous fistulas without a space-occupying effect, covered stents should be considered; however, the available stents are inflexible and have not been approved for this indication.<sup>31</sup>

Detailed neuro-ophthalmologic examination revealed slight ptosis and subtle disturbances of oculomotor functions that had not been detected in the normal clinical neurologic work-up described in a previous study.<sup>1</sup> Therefore, preinterventional, peri-interventional, and long-term follow-up assessment of these patients should include examinations by ophthalmologists.

In 3 patients cranial nerve V sensory deficits were found, which are reported rarely in patients with AVF of the cavernous sinus. In 1 patient a dysesthesia in V1 and V2 was seen preinterventionally<sup>7</sup>; in 1 patient it was observed as a postinterventional complication.<sup>8</sup>

Théaudin et al found more asymptomatic patients after transvenous embolization with coils than after transarterial embolization with particles.<sup>11</sup> Taking into account that our group consisted only of patients after coil embolization, we found no influence of access, an observation that is highly congruent with the fact that all patients underwent complete occlusion from the anterior to posterior parts of the cavernous sinus.

The long-term outcome was also measured by the patients' assessment of their health state and by the questionnaires HIT-6 and EQ-5D. To our knowledge this was done for the first time in these patients. The mean score for mental state on the numeric analog scale documented good health (mean value 7.25 of maximum 10). This was confirmed by the results of the EQ-5D questionnaire (On-line Table 3). The numeric analog scale of the EQ-5D revealed a good general health state (mean value 76 of maximum 100). Most patients reported no problems. Moderate problems were documented in 41% of the patients. These data generated by the patients' ratings are therefore consistent with the good results of the mRS and additionally with the previously reported mRS results in patients with dural carotid cavernous fistulas.<sup>32</sup>

One limitation of our study is the small number of patients, which does not allow a definite statistical statement. To prove the theory of a space-occupying effect of the coils as a cause of the persistent CNP, we would need a control group. Nevertheless, we can conclude that, of all the tested variables, the volume of coils correlated with permanent cranial nerve VI paresis and diplopia either due to the underlying size of fistula itself or due to the long-term space-occupying effect or both.

The current data show that, in contrast to the more optimistic results of some previous reports, preinterventional cranial nerve palsies are permanent in most patients in our series, though improved in part. Although cranial nerve palsies were present, most patients rated their quality of life as good.

## Conclusions

Long-term follow-up examinations showed that preinterventional cranial nerve palsies with disturbances of oculomotor and visual functions were permanent in 44% of patients. This may be explained by the underlying fistula size itself and/or the space-occupying effect of the coils and therefore the permanent pressure on the cranial nerves running through or in the wall of the cavernous sinus. All symptoms related to reversed flow in the ophthalmic vein remained cured after successful treatment. Patients rated their quality of life as good, which was underlined by the mRS score.

In summary, coil embolization of AVFs of the cavernous sinus is a therapy with a satisfactory long-term outcome. Patients with cavernous sinus fistulas should be routinely examined by an ophthalmologist: meticulous and thorough follow-up of ocular symptoms is crucial for the control of the therapeutic success in these patients.

## Acknowledgments

The authors thank Hanns Ackermann, PhD, for assistance with statistical analyses.

## References

1. Bink A, Berkefeld J, Lüchtenberg M, et al. **Coil embolization of cavernous sinus in patients with direct and dural arteriovenous fistula.** *Eur Radiol* 2009; 19:1443–49
2. Nishino K, Ito Y, Hasegawa H, et al. **Cranial nerve palsy following transvenous embolization for a cavernous sinus dural arteriovenous fistula: association with the volume and location of detachable coils.** *J Neurosurg* 2008;109:208–14
3. Aihara N, Mase M, Yamada K, et al. **Deterioration of ocular motor dysfunction after transvenous embolization of dural arteriovenous fistula involving the cavernous sinus.** *Acta Neurochir* 1999;141:707–09
4. Benndorf G, Bender A, Lehmann R, et al. **Transvenous occlusion of dural cavernous sinus fistulas through the thrombosed inferior petrosal sinus: report of four cases and review of the literature.** *Surg Neurol* 2000;54:42–54
5. Cheng KM, Chan CM, Cheung YL. **Transvenous embolisation of dural carotid-cavernous fistulas by multiple venous routes: a series of 27 cases.** *Acta Neurochir* 2003;145:17–29
6. Kim DJ, Kim DI, Suh SH, et al. **Results of transvenous embolization of cavernous dural arteriovenous fistula: a single-center experience with emphasis on complications and management.** *AJNR Am J Neuroradiol* 2006;27:2078–82
7. Klich J, Huppertz HJ, Spetzger U, et al. **Transvenous treatment of carotid cavernous and dural arteriovenous fistulae: results for 31 patients and review of the literature.** *Neurosurgery* 2003;53:836–56
8. Oishi H, Arai H, Sato K, et al. **Complications associated with transvenous embolisation of cavernous dural arteriovenous fistula.** *Acta Neurochir* 1999; 141:1265–71
9. Yamashita K, Taki W, Nishi S, et al. **Transvenous embolization of dural carotid-cavernous fistulae: technical considerations.** *Neuroradiology* 1993;35: 475–79
10. Roy D, Raymond J. **The role of transvenous embolization in the treatment of intracranial dural arteriovenous fistulas.** *Neurosurgery* 1997;40:1133–41
11. Théaudin M, Saint-Maurice JP, Chapot R, et al. **Diagnosis and treatment of dural carotid-cavernous fistulas: a consecutive series of 27 patients.** *J Neurol Neurosurg Psychiatry* 2007;78:174–79
12. Kosinski M, Bayliss MS, Bjorner JB, et al. **A six-item short-form survey for measuring headache impact: the HIT-6.** *Qual Life Res* 2003;12:963–74
13. van Swieten JC, Koudstaal PJ, Visser MC, et al. **Interobserver agreement for the assessment of handicap in stroke patients.** *Stroke* 1988;19:604–07
14. The Euroqol Group. **Euroqol: a new facility for the measurement of health-related quality-of-life.** *Health Policy* 1990;16:199–208
15. Hosmer DW, Lemeshow S. *Applied Logistic Regression.* New York: Wiley; 2000
16. Kruskal WH, Wallis WA. **Use of ranks in one-criterion variance analysis.** *J Am Stat Assoc* 1952;47:583–621 and 1953;48:907–11
17. Phelps CD, Thompson HS, Ossoinig KC. **The diagnosis and prognosis of atypical carotid-cavernous fistula (red-eyed shunt syndrome).** *Am J Ophthalmol* 1982;93:423–36
18. Viñuela F, Fox AJ, Debrun GM, et al. **Spontaneous carotid-cavernous fistulas: clinical, radiological, and therapeutic considerations: experience with 20 cases.** *J Neurosurg* 1984;60:976–84
19. Nukui H, Shibasaki T, Kaneko M, et al. **Long-term observations in cases with spontaneous carotid-cavernous fistulas.** *Surg Neurol* 1984;21:543–52
20. Halbach VV, Higashida RT, Hieshima GB, et al. **Dural fistulas involving the cavernous sinus: results of treatment in 30 patients.** *Radiology* 1987;163: 437–42
21. Liu HM, Wang YH, Chen YF, et al. **Long-term clinical outcome of spontaneous carotid cavernous sinus fistulae supplied by dural branches of the internal carotid artery.** *Neuroradiology* 2001;43:1007–14
22. Tsai FY, Hieshima GB, Mehringer CM, et al. **Delayed effects in the treatment of carotid-cavernous fistulas.** *AJNR Am J Neuroradiol* 1983;4:357–61
23. Berthelsen B, Svendsen P. **Treatment of direct carotid-cavernous fistulas with detachable balloons.** *Acta Radiol* 1987;28:683–91
24. Brosnahan D, McFadzean RM, Teasdale E. **Neuro-ophthalmic features of carotid cavernous fistulas and their treatment by endoarterial balloon embolisation.** *J Neurol Neurosurg Psychiatry* 1992;55:553–56
25. Bavinszki G, Killer M, Gruber A, et al. **Treatment of post-traumatic carotico-**

- cavernous fistulae using electrolytically detachable coils: technical aspects and preliminary experience. *Neuroradiology* 1997;39:81–85
26. Liang CC, Michon JJ, Cheng KM, et al. **Ophthalmologic outcome of transvenous embolization of spontaneous carotid-cavernous fistulas: a preliminary report.** *Int Ophthalmol* 1999;23:43–47
27. Kirsch M, Henkes H, Liebig T, et al. **Endovascular management of dural carotid-cavernous sinus fistulas in 141 patients.** *Neuroradiology* 2006;48:486–90
28. Y. Usami S, Abe T, Hata Y. **Classification of the venous route of carotid cavernous fistula.** *Interventional Neuroradiol* 1997;3(suppl 2):93–96
29. Nakamura M, Tamaki N, Kawaguchi T, et al. **Selective transvenous embolization of dural carotid-cavernous sinus fistulas with preservation of sylvian venous outflow: report of three cases.** *J Neurosurg* 1998;89:825–29
30. Agid R, Willinsky RA, Haw C, et al. **Targeted compartmental embolization of cavernous sinus dural arteriovenous fistulae using transfemoral medial and lateral facial vein approaches.** *Neuroradiology* 2004;46:156–60
31. Wang C, Xie X, You C, et al. **Placement of covered stents for the treatment of direct carotid cavernous fistulas.** *AJNR Am J Neuroradiol* 2009;30:1342–46
32. Meyers PM, Halbach VV, Dowd CF, et al. **Dural carotid cavernous fistula: definitive endovascular management and long-term follow-up.** *Am J Ophthalmol* 2002;134:85–92