

Are your **MRI contrast agents** cost-effective?

Learn more about generic **Gadolinium-Based Contrast Agents**.



**FRESENIUS
KABI**

caring for life

AJNR

**Immunoglobulin G4—Related Sclerosing
Disease Mimicking Invasive Tumor in the
Nasal Cavity and Paranasal Sinuses**

T. Sasaki, K. Takahashi, M. Mineta, T. Fujita and T.
Aburano

This information is current as
of April 20, 2024.

AJNR Am J Neuroradiol published online 5 May 2011
<http://www.ajnr.org/content/early/2011/05/05/ajnr.A2495>

Immunoglobulin G4–Related Sclerosing Disease Mimicking Invasive Tumor in the Nasal Cavity and Paranasal Sinuses

CASE REPORT

T. Sasaki
K. Takahashi
M. Mineta
T. Fujita
T. Aburano

SUMMARY: IgG4RSD affecting the nasal cavity and paranasal sinuses is extremely rare. A 71-year-old man presented with an invasive mass in the nasal cavity and paranasal sinuses that was confirmed by immunostaining to be IgG4RSD. The occurrence of this disease in the nasal cavity and paranasal sinuses can resemble a malignant tumor on diagnostic imaging.

ABBREVIATIONS: IgG4 = immunoglobulin G4; IgG4RSD = immunoglobulin G4–related sclerosing disease

IgG4RSD involves multiple organs, particularly exocrine organs such as the salivary glands, pancreas, and biliary tracts.¹ When it affects the head and neck, it commonly involves the salivary, lachrymal, and pituitary glands. There is insufficient radiologic data for IgG4RSD affecting the nasal cavity and paranasal sinuses.^{1–3} We present a case of IgG4RSD mimicking an invasive malignant tumor in the nasal cavity and maxillary sinuses on both sides.

Case Report

A 71-year-old man who had a brain contusion 25 years earlier complained of nasal occlusion and swelling of the right cheek. The patient had no further relevant medical history. A right maxillary tumor was suspected. His serum immunoglobulin level, including IgG4, was slightly elevated (114 mg/dL; normal range, 4.8–105 mg/dL; 7% of total serum immunoglobulin). The results of other biochemical tests were normal. MR imaging showed a mass in the nasal cavity and both maxillary sinuses, invading the right cheek subcutaneously along the right plexus dentalis superior, the left pterygopalatine fossa, and the left sphenoidal bone marrow (Fig 1). No osseous destruction was apparent. Masses of intermediate intensity and slight hyperintensity were observed on T1- and T2-weighted images, respectively (Fig 1A, -B), and an area of high T1-weighted signal intensity within the right maxillary sinus suggested hemorrhage (Fig 1A). Fat-suppressed T1-weighted imaging of the masses revealed homogeneous gadolinium contrast enhancement (Fig 1C).

We suspected malignant lymphoma, melanoma, or other malignant tumor with perineural and bone marrow invasion and biopsied the nasal mucosa. Hematoxylin-eosin staining revealed lymphoid follicles with a germinal center among proliferative fibrosis, with lymphocyte and plasma cells without atypia (Fig 2A). Immunostaining revealed plasma cells expressing IgG4 (Fig 2B, -C). Other organ systems showed no abnormalities. Oral prednisolone therapy for 18 months (tapered to 10 mg/day from an initial dose of 40 mg/day) reduced the tumor volume to approximately one-third, and the tumor remained stable with time.

Received September 14, 2010; accepted November 26.

From the Department of Radiology (T.S., K.T., T.A.), Asahikawa Medical University, Hokkaido, Japan; and Departments of Radiology (M.M.) and Otorhinolaryngology (T.F.), Asahikawa Red Cross Hospital, Hokkaido, Japan.

Please address correspondence to Tomoaki Sasaki, MD, Department of Radiology, Asahikawa Medical University, 2-1-1 Midorigaoka-higashi, Asahikawa, Hokkaido 078-8510, Japan; e-mail: tomoaki3est@gmail.com

DOI 10.3174/ajnr.A2495

Discussion

IgG4RSD affecting the nasal cavity and paranasal sinuses with perineural and bone marrow invasion strongly resembled a malignant tumor. The differential diagnoses included lymphoma, adenoid cystic carcinoma, squamous cell carcinoma, olfactory neuroblastoma, malignant melanoma, or other malignant tumor.⁴ Olfactory neuroblastoma, adenoid cystic carcinoma, and squamous cell carcinoma were atypical with regard to location and expansile formation.⁴ Malignant melanoma occasionally appears as a high-intensity mass on T1-weighted images but might appear more exophytic and inhomogeneous when larger in mass.^{5,6} Diagnostic imaging did not rule out the possibility of nonspecific malignant lymphoma.^{7–9}

In the head and neck region, IgG4RSD commonly manifests as chronic sclerosing sialadenitis, chronic sclerosing dacryoadenitis, and lymphoplasmacytic hypophysitis.^{1,10,11} IgG4RSD is considered to result from an imbalance in the regulatory immune reaction,¹² but the mechanisms are still unclear. IgG4RSD develops predominantly in males¹³ and involves ≥ 2 sites in most patients, though some patients may have disease involving only 1 organ.¹⁴ IgG4RSD is diagnosed on the basis of clinical and histopathologic evidence such as the presence of lymphoplasmacytic infiltrates, especially elevated IgG4-positive plasma cells and fibrotic sclerosing tissue.¹ IgG4RSD has been shown to respond favorably to steroid therapy.¹³ Azathioprine or rituximab is useful in cases of relapse or failure to wean off steroids.^{15,16}

IgG4RSD affecting the nasal cavity and paranasal sinuses is extremely rare. Ishida et al¹ reported 1 such case of an invasive mass with similar diagnostic characteristics. However, prominent perineural and bone marrow invasion associated with IgG4RSD at this site has not been previously reported. Socolovsky et al¹⁷ reported a case of reactive lymphoid follicular hyperplasia, which was not IgG4RSD, involving a peripheral nerve. Lymphoproliferative diseases, despite being benign, could resemble perineural invasion on diagnostic imaging, though the mechanism thereof is unclear.

In conclusion, IgG4RSD may involve the nasal cavity and paranasal sinuses with perineural and bone marrow invasion, mimicking malignant lymphoma.

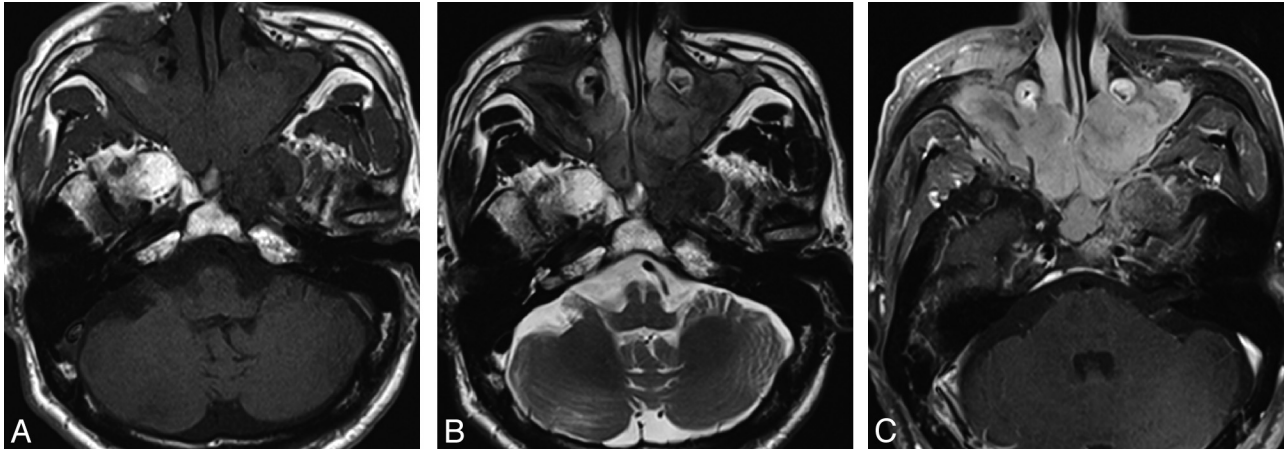

Fig 1. MR imaging of a mass in the nasal cavity and both maxillary sinuses. *A*, T1-weighted image shows a mass of intermediate intensity compared with muscle and high-intensity areas in the right maxillary sinus. *B*, Slight hyperintensity is seen on the T2-weighted image. *C*, Fat-suppressed T1-weighted image has homogeneous gadolinium contrast enhancement.

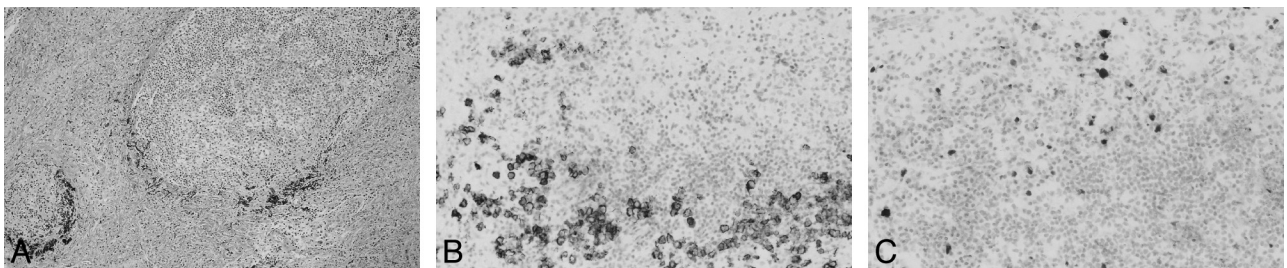


Fig 2. Histopathologic evaluation of the biopsy. *A*, Hematoxylin-eosin stain reveals lymphoid follicles with a germinal center, among proliferative fibrosis with lymphocyte and plasma cells lacking atypia (original magnification $\times 25$). *B*, Immunohistopathologic staining for CD138 demonstrates plasma cell infiltration (original magnification $\times 50$). *C*, Immunostaining demonstrates plasma cell IgG4 expression (original magnification $\times 50$).

References

- Ishida M, Hotta M, Kushima R, et al. Multiple IgG4-related sclerosing lesions in the maxillary sinus, parotid gland and nasal septum. *Pathol Int* 2009;59:670–75
- Ikeda R, Awataguchi T, Shoji F, et al. A case of paranasal sinus lesions in IgG4-related sclerosing disease. *Otolaryngol Head Neck Surg* 2010;142:458–59
- Isaka Y, Yoshioka K, Nishio M, et al. A case of IgG4-related multifocal fibrosclerosis complicated by central diabetes insipidus. *Endocr J* 2008;55:723–28
- Boo H, Hogg JP. Nasal cavity neoplasms: a pictorial review. *Curr Probl Diagn Radiol* 2010;39:54–61
- Yousem DM, Li C, Montone KT, et al. Primary malignant melanoma of the sinonasal cavity: MR imaging evaluation. *Radiographics* 1996;16:1101–10
- Kim SS, Han MH, Kim JE, et al. Malignant melanoma of the sinonasal cavity: explanation of magnetic resonance signal intensities with histopathologic characteristics. *Am J Otolaryngol* 2000;21:366–78
- Ou CH, Chen CC, Ling JC, et al. Nasal NK/T-cell lymphoma: computed tomography and magnetic resonance imaging findings. *J Chin Med Assoc* 2007;70:207–12
- Nguyen DD, Loo BW Jr, Tillman G, et al. Plasmablastic lymphoma presenting in a human immunodeficiency virus-negative patient: a case report. *Ann Hematol* 2003;82:521–25
- King AD, Lei KI, Richards PS, et al. Non-Hodgkin's lymphoma of the nasopharynx: CT and MR imaging. *Clin Radiol* 2003;58:621–25
- Masaki Y, Dong L, Kurose N, et al. Proposal for a new clinical entity, IgG4-positive multiorgan lymphoproliferative syndrome: analysis of 64 cases of IgG4-related disorders. *Ann Rheum Dis* 2009;68:1310–15
- Shimatsu A, Oki Y, Fujisawa I, et al. Pituitary and stalk lesions (infundibulohypophysitis) associated with immunoglobulin G4-related systemic disease: an emerging clinical entity. *Endocr J* 2009;56:1033–41. Epub 2009 Nov 19
- Zen Y, Fujii T, Harada K, et al. Th2 and regulatory immune reactions are increased in immunoglobulin G4-related sclerosing pancreatitis and cholangitis. *Hepatology* 2007;45:1538–46
- Nishino T, Toki F, Oyama H, et al. Long-term outcome of autoimmune pancreatitis after oral prednisolone therapy. *Intern Med* 2006;45:497–501
- Cheuk W, Lee KC, Chong LY, et al. IgG4-related sclerosing disease: a potential new etiology of cutaneous pseudolymphoma. *Am J Surg Pathol* 2009;33:1713–19
- Sandanayake NS, Church NI, Chapman MH, et al. Presentation and management of post-treatment relapse in autoimmune pancreatitis/immunoglobulin G4-associated cholangitis. *Clin Gastroenterol Hepatol* 2009;7:1089–96
- Khosroshahi A, Bloch DB, Deshpande V, et al. Rituximab therapy leads to rapid decline of serum IgG4 levels and prompt clinical improvement in IgG4-related systemic disease. *Arthritis Rheum* 2010;62:1755–62
- Socolovsky M, Spaho N, Cueto DG, et al. Reactive lymphoid follicular hyperplasia mimicking a peripheral nerve tumor. *Surg Neurol* 2008;70:514–17