

Are your **MRI contrast agents** cost-effective?

Learn more about generic **Gadolinium-Based Contrast Agents**.



**FRESENIUS  
KABI**

caring for life

**AJNR**

**Anatomic Location and Somatotopic  
Arrangement of the Corticospinal Tract at  
the Cerebral Peduncle in the Human Brain**

H.G. Kwon, J.H. Hong and S.H. Jang

*AJNR Am J Neuroradiol* published online 8 September 2011  
<http://www.ajnr.org/content/early/2011/09/08/ajnr.A2660>

This information is current as  
of April 17, 2024.

ORIGINAL  
RESEARCHH.G. Kwon  
J.H. Hong  
S.H. Jang

# Anatomic Location and Somatotopic Arrangement of the Corticospinal Tract at the Cerebral Peduncle in the Human Brain

**BACKGROUND AND PURPOSE:** Little is known about the detailed anatomic location and somatotopic arrangement at the CP. Using DTT with FSL tools, we conducted an investigation of the anatomic location and somatotopic arrangement of the CST at the CP in the human brain.

**MATERIALS AND METHODS:** We recruited 43 healthy volunteers for this study. DTI was obtained by using 1.5T, and CSTs for the hand and leg were obtained by using the FSL tool. The somatotopic location of the CST was evaluated as the highest probabilistic location at the upper and lower midbrain. The posterior boundary was determined as the line between the interpeduncular fossa and the lateral sulcus; we then drew a rectangle on the basis of the boundary of the CP.

**RESULTS:** In the mediolateral direction, the highest probabilistic locations for the hand and leg were an average of 60.46% and 69.98% from the medial boundary at the upper midbrain level and 53.44% and 62.76% at the lower midbrain level, respectively. As for the anteroposterior direction, the highest probabilistic locations for the hand and leg were an average of 28.26% and 32.03% from the anterior boundary at the upper midbrain level and 30.19% and 33.59% at the lower midbrain level, respectively.

**CONCLUSIONS:** We found that the hand somatotopy for the CST is located at the middle portion of the CP and the leg somatotopy is located lateral to the hand somatotopy.

**ABBREVIATIONS:** CP = cerebral peduncle; CST = corticospinal tract; DTI = diffusion tensor imaging; DTT = diffusion tensor tractography; FA = fractional anisotropy; FSL = Functional MR Imaging of the Brain Software Library; MD = mean diffusivity

The CP is a compact area into which many descending corticofugal tracts converge and pass through.<sup>1-4</sup> Due to its anatomic characteristics, occurrence of a brain injury at the CP could result in severe neurologic deficits.<sup>5,6</sup> Therefore, detailed clarification of the anatomy of the CP would be important for clinical neuroscience. The CST is the most important motor pathway in the human brain. Detailed knowledge of the somatotopy of the CST would be helpful in the establishment of scientific rehabilitative strategies, estimation of the rehabilitative period, establishment of guidelines for invasive procedures, and prediction of final outcome for patients with brain injury. Many previous studies have reported that the CST was located in the middle portion of the CP.<sup>2,3,7-12</sup> However, some studies have provided slightly different data, suggesting that the CST was located in the mid-to-lateral portion of the CP.<sup>1,13,14</sup> As for the somatotopic arrangement of the CST at the CP, many neuroanatomy textbooks have shown mediolateral arrangement of somatotopies for the arm and leg.<sup>2,3</sup> How-

ever, studies elucidating detailed somatotopic anatomy have been limited and somewhat controversial.<sup>14,15</sup> Therefore, the exact anatomic location and somatotopic arrangement of the CST at the CP have not been clearly elucidated for easy application in the clinical field.

DTT, which is derived from DTI, provides the advantage of visualization and localization of the CST at the subcortical level in 3D.<sup>16</sup> Therefore, several DTT studies of the somatotopic anatomy of the CST in the human brain have been reported for the corona radiata, internal capsule, pons, and medulla.<sup>17-24</sup> However, little is known about the detailed anatomic location and somatotopic arrangement of the CP.<sup>14</sup>

In the current study, by using DTT, we attempted to investigate the detailed anatomic location and somatotopic arrangement of the CST at the CP in the healthy human brain.

## Materials and Methods

### Subjects

We recruited 43 right-handed healthy subjects (men, 21; women, 22; mean age, 31.02 years; range, 20–50 years) with no previous history of neurologic, physical, or psychiatric illness. Handedness was evaluated by using the Edinburgh Handedness Inventory.<sup>25</sup> All subjects understood the purpose of the study and provided written informed consent before participation. The study protocol was approved by our local institutional research board.

### Data Acquisition

DTI data were acquired by using a 6-channel head coil on a 1.5T Gyroscan Intera scanner (Philips Healthcare, Best, the Netherlands) with single-shot echo-planar imaging. For each of the 32 noncollinear diffusion-sensitizing gradients, we acquired 67 contiguous sections

Received February 13, 2011; accepted March 21.

From the Department of Physical Therapy (H.G.K.), Graduate School of Rehabilitation Science, Daegu University, Daegu, Republic of Korea; and Department of Physical Medicine and Rehabilitation (J.H.H., S.H.J.), College of Medicine, Yeungnam University, Taegu, Republic of Korea.

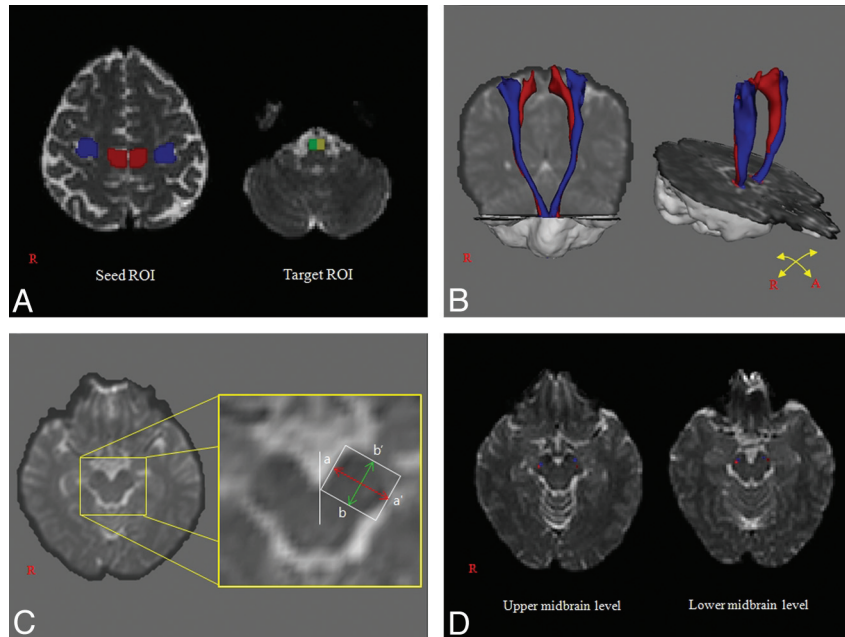
This work was supported by National Research Foundation of Korea Grant funded by the Korean Government (KRF-2008-314-E00173).

Please address correspondence to Sung Ho Jang, MD, Department of Physical Medicine and Rehabilitation, College of Medicine, Yeungnam University 317-1, Daemyungdong, Namku, Taegu, 705-717, Republic of Korea; e-mail: strokerehab@hanmail.net or belado@med.yu.ac.kr



Indicates open access to non-subscribers at [www.ajnr.org](http://www.ajnr.org)

<http://dx.doi.org/10.3174/ajnr.A2660>



**Fig 1.** A, Seed regions of interest were placed on the precentral knob (blue) for the hand and on the mediodorsal part (leg somatotopy) of the primary motor cortex for the leg (red). The target region of interest was placed on the known CST area of the pontomedullary junction. B, CSTs were constructed in both hemispheres (blue, hand; red, leg). The probability threshold is the point at which the corticopontocerebellar fiber disappears. C, Landmarks for measurement of the location of the CST (white line, midline of the interpeduncular fossa; white-lined rectangle, the boundary of the cerebral peduncle of the midbrain; a-a' double-headed arrow [red], mediolateral direction; b-b' double-headed arrow [green], anteroposterior direction). D, The location of the CST is shown at the upper and lower midbrain.

parallel to the anterior/posterior commissure line. Imaging parameters were as follows: acquisition matrix =  $96 \times 96$ ; reconstructed to matrix =  $128 \times 128$ ; FOV =  $221 \times 221 \text{ mm}^2$ ; TR = 10,726 ms; TE = 76 ms; parallel imaging reduction factor (sensitivity encoding factor) = 2; echo-planar imaging factor = 49;  $b = 1000 \text{ s/mm}^2$ ; NEX = 1; and section thickness = 2.3 mm (acquired isotropic voxel size =  $2.3 \times 2.3 \times 2.3 \text{ mm}^3$ ).

### Fiber Tracking

The FSL ([www.fmrib.ox.ac.uk/fsl](http://www.fmrib.ox.ac.uk/fsl)) was used for analysis of diffusion-weighted imaging data. Head-motion effect and image distortion due to eddy currents were corrected by affine multiscale 2D registration. Fiber tracking was performed by using a probabilistic tractography method, based on a multifiber model and applied in the present study using tractography routines implemented in Functional Magnetic Resonance Imaging of the Brain Diffusion (5000 streamline samples, 0.5-mm step lengths, curvature thresholds = 0.2).<sup>26-28</sup> CSTs for both the upper and lower extremities were determined by selection of fibers passing through both seed and target regions of interest. Seed regions of interest for the hand and leg were located in accordance with known anatomy (region of interest for the hand, the precentral knob; region of interest for the leg, the dorsomedial part [leg somatotopy] of the primary motor cortex).<sup>22</sup> The target region of interest was located at the pontomedullary junction of the CST (blue portion of the anterior pontomedullary junction on the BO map).<sup>22</sup> Additionally, we measured the dimensions of seed and target regions of interest.

### Measurement of CST location

For each subject, the somatotopic location of the CST at the midbrain was evaluated as the highest probabilistic location in the 2 sections (in the upper midbrain, the superior colliculus can be seen in the axial image; and in the lower midbrain, the inferior colliculus can be seen in

the axial image) (Fig 1). The posterior boundary was determined by drawing a line from the interpeduncular fossa to the lateral sulcus; we then drew a rectangle on the basis of the boundary of the CP. As shown Fig 1, the double-headed arrow, a-a', was defined as the mediolateral direction of the upper and lower midbrain, and the double-headed arrow, b-b', as the anteroposterior direction.

### Statistical Analysis

An independent *t* test by using the highest probabilistic location was performed for determination of variances between CSTs associated with the hand and leg at the upper and lower midbrain. Values of FA, MD, and tract volume were used in the performance of an independent *t* test for determination of variances between the right and left hemispheres. The dimensions of seed and target regions of interest were tested for normality. The significance level of the *P* value was set at .05.

### Results

The Table shows the DTI parameters for the CST and locations of the CST at the CP. In the mediolateral direction, the highest probabilistic locations for the hand and leg were an average of 60.46% and 69.98% from the medial boundary at the upper midbrain level and 53.44% and 62.76% at the lower midbrain level, respectively. As for the anteroposterior direction, the highest probabilistic locations for the hand and leg were an average of 28.26% and 32.03% from the anterior boundary at the upper midbrain level and 30.19% and 33.59% at the lower midbrain level, respectively. The dimensions of seed and target regions of interest met the normality between subjects. In the seed regions of interest for the hand, the dimensions for the right and left were an average of 52.62 and 53.34, respectively, and 51.47 and 50.82 for the leg, respectively. As for the target regions of interest, the dimensions for

**Results of DTI parameters for the CST and average locations of the highest probability point of the CST at the CP of the midbrain<sup>a</sup>**

	Right		Left		Total	
	Hand	Leg	Hand	Leg	Hand	Leg
FA	0.52 (±0.03)	0.53 (±0.12)	0.53 (±0.05)	0.52 (±0.1)	0.53 (±0.04)	0.53 (±0.11)
MD	0.91 (±0.14)	0.89 (±0.18)	0.87 (±0.13)	0.88 (±0.12)	0.89 (±0.14)	0.89 (±0.15)
Tract volume	693.56 (±419.98)	494.86 (±298.43)	618.3 (±372.14)	567.7 (±284.4)	655.93 (±396.25)	531.28 (±292.09)
Upper midbrain level						
Mediolateral	59.41 (±9.6)	70.77 (±7.84)	61.39 (±9.8)	69.20 (±7.78)	60.46 (±9.69)	69.98 (±7.8)
Anteroposterior	27.94 (±10.57)	32.19 (±13.34)	28.59 (±9.72)	31.86 (±9.53)	28.26 (±10.1)	32.03 (±11.52)
Lower midbrain level						
Mediolateral	53.45 (±9.38)	62.51 (±14.84)	53.42 (±10.61)	63 (±10.32)	53.44 (±9.96)	62.76 (±12.73)
Anteroposterior	28.23 (±8.37)	31.51 (±10.28)	32.15 (±11)	35.68 (±10.85)	30.19 (±9.91)	33.59 (±10.72)

<sup>a</sup> Values represent mean (±SD), MD × 10<sup>-3</sup>(mm<sup>2</sup>/s), and location (%).

the right and left were an average of 14.49 and 14.37, respectively. In terms of FA, MD, and tract volume, no significant differences were observed between hemispheres ( $P < .05$ ). No significant differences were observed in the location of the anteroposterior direction between the hand and leg somatotopies ( $P < 0.05$ ). In contrast, in terms of the location for the mediolateral direction, significant differences were observed between hand and leg somatotopies ( $P < .05$ ).

## Discussion

In the current study, we found that the hand somatotopy for the CST descended through the middle portion of the CP and that the leg somatotopy was located lateral to the hand somatotopy. In addition, we found that the somatotopies for the hand and leg were arranged horizontal to the line of the anterior boundary of the CP; however, the leg somatotopy was located slightly posterior to the hand somatotopy with the standard of the anterior boundary of the CP. We attempted to obtain useful data that could be easily applied in the clinical field. However, defining the anatomic boundary was difficult due to the anatomic variation of the CP, particularly the round anterior boundary of the CP. Therefore, we were obliged to adopt the line between the interpeduncular fossa and the lateral sulcus as the posterior boundary for a rectangle of the CP.

Before development of DTI, a number of studies attempted to elucidate the location and somatotopic arrangement of the CST at the CP of the human brain by using the wallerian degeneration phenomenon on brain CT or MR imaging following brain injury,<sup>7-12,29,30</sup> direct brain stimulation study during surgery,<sup>15,31</sup> or pedunculotomy for control of involuntary movements.<sup>5,6</sup> Although there seems to be a general consensus that the CST occupies the middle portion of the CP and that the somatotopies for the arm and leg are arranged mediolaterally, some controversies still exist. Moreover, studies elucidating detailed anatomic information have been limited.<sup>14,15</sup> Studies reporting that the CST was located in the middle portion of the CP have been a general trend<sup>7-10,12</sup>; however, some textbooks or studies have suggested more specific data: the middle three-fifths,<sup>3</sup> middle half,<sup>11</sup> or middle two-thirds.<sup>2</sup> As for the somatotopic arrangement of the CST, by direct brain stimulation study during stereotactic surgery in more than 700 cases, Martinez et al (1967)<sup>15</sup> found unique data demonstrating an anteroposterior somatotopic arrangement from the face to the upper to the lower limbs rather than a mediolateral arrangement at the upper CP. We think that our results generally coincide with those of previous studies; however, our

study revealed unique results showing that the hand and leg somatotopy for the CST was located in the mid-to-lateral portion of the CP and that the leg somatotopy was located slightly posterior to the hand somatotopy with the standard of the anterior boundary of the CP.<sup>2,3,7-12,15</sup>

A few DTT studies have reported the location of CST in the CP.<sup>1,13,14</sup> In 2002, Mori and van Zijl<sup>13</sup> provided data suggesting that the CST was located in the mid-to-lateral portion of the CP. Subsequently, by using functional MR imaging and DTI, Newton et al (2006)<sup>1</sup> demonstrated the pathway of corticofugal fibers from multiple cortical motor areas to the CP. They found that the neural tracts from the primary motor cortex to the CP are located laterally at the CP. Recently, Park et al (2008)<sup>14</sup> also demonstrated that the CSTs were located in the mid-to-lateral portion of the CP and that the somatotopic arrangement for the hand and leg showed mediolateral orientation at the CP. Our results are also compatible with those of previous DTT studies; however, because these previous studies did not include detailed numeric data for anatomic location, as in our study, direct comparison is impossible. To the best of our knowledge, this is the first DTI study containing detailed numeric data that can be easily applied in the clinical field.

## Conclusions

We found that the hand somatotopy for the CST was located at the middle portion of the CP and that the leg somatotopy was located lateral to the hand somatotopy. This result should be helpful to clinicians in the neuroscience field. However, it has a limitation in that we studied only hand and leg somatotopy, excluding evaluation of the CST for somatotopy of the face or trunk. Further studies to address this limitation are warranted. We believe that clinical correlation studies by using DTT will be necessary in the near future.

## References

- Newton JM, Ward NS, Parker GJ, et al. **Non-invasive mapping of corticofugal fibres from multiple motor areas: relevance to stroke recovery.** *Brain* 2006;129:1844-58
- Carpenter MB. *Core Text of Neuroanatomy.* Baltimore: Williams & Wilkins; 1985
- Affii AK, Bergman RA. *Functional Neuroanatomy: Text and Atlas.* New York: Lange Medical Books/McGraw-Hill; 2005
- Duus P. *Topical Diagnosis in Neurology: Anatomy, Physiology, Signs, Symptoms.* Stuttgart, Germany: Thieme Medical Publishers; 1989
- Bucy PC, Keplinger JE, Siqueira EB. **Destruction of the "pyramidal tract" in man.** *J Neurosurg* 1964;21:285-98
- Jane JA, Yashon D, Becker DP, et al. **The effect of destruction of the corticospinal tract.** *J Neurosurg* 1964;21:285-98

- nal tract in the human cerebral peduncle upon motor function and involuntary movements: report of 11 cases. *J Neurosurg* 1968;29:581–85
7. Bouchareb M, Moulin T, Cattin F, et al. Wallerian degeneration of the descending tracts: CT and MRI features of the brain stem. *J Neuroradiol* 1988;15:238–52
  8. Kobayashi S, Hasegawa S, Maki T, et al. Retrograde degeneration of the corticospinal tract associated with pontine infarction. *J Neurol Sci* 2005;236:91–93
  9. Uchino A, Imada H, Ohno M. MR imaging of wallerian degeneration in the human brain stem after ictus. *Neuroradiology* 1990;32:191–95
  10. Uchino A, Onomura K, Ohno M. Wallerian degeneration of the corticospinal tract in the brain stem: MR imaging. *Radiat Med* 1989;7:74–78
  11. Warabi T, Miyasaka K, Inoue K, et al. Computed tomographic studies of the basis pedunculi in chronic hemiplegic patients: topographic correlation between cerebral lesion and midbrain shrinkage. *Neuroradiology* 1987;29:409–15
  12. Waragai M, Watanabe H, Iwabuchi S. The somatotopic localisation of the descending cortical tract in the cerebral peduncle: a study using MRI of changes following wallerian degeneration in the cerebral peduncle after a supratentorial vascular lesion. *Neuroradiology* 1994;36:402–04
  13. Mori S, van Zijl PC. Fiber tracking: principles and strategies: a technical review. *NMR Biomed* 2002;15:468–80
  14. Park JK, Kim BS, Choi G, et al. Evaluation of the somatotopic organization of corticospinal tracts in the internal capsule and cerebral peduncle: results of diffusion-tensor MR tractography. *Korean J Radiol* 2008;9:191–95
  15. Martinez SN, Bertrand C, Botana-Lopez C. Motor fiber distribution within the cerebral peduncle: results of unipolar stimulation. *Confin Neurol* 1967;29:117–22
  16. Mori S, Crain BJ, Chacko VP, et al. Three-dimensional tracking of axonal projections in the brain by magnetic resonance imaging. *Ann Neurol* 1999;45:265–69
  17. Kim YH, Kim DS, Hong JH, et al. Corticospinal tract location in internal capsule of human brain: diffusion tensor tractography and functional MRI study. *Neuroreport* 2008;19:817–20
  18. Holodny AI, Gor DM, Watts R, et al. Diffusion-tensor MR tractography of somatotopic organization of corticospinal tracts in the internal capsule: initial anatomic results in contradistinction to prior reports. *Radiology* 2005;234:649–53
  19. Ino T, Nakai R, Azuma T, et al. Somatotopy of corticospinal tract in the internal capsule shown by functional MRI and diffusion tensor images. *Neuroreport* 2007;18:665–68
  20. Westerhausen R, Huster RJ, Kreuder F, et al. Corticospinal tract asymmetries at the level of the internal capsule: is there an association with handedness? *Neuroimage* 2007;37:379–86
  21. Yamada K, Kizu O, Kubota T, et al. The pyramidal tract has a predictable course through the centrum semiovale: a diffusion-tensor based tractography study. *J Magn Reson Imaging* 2007;26:519–24
  22. Hong JH, Son SM, Jang SH. Somatotopic location of corticospinal tract at pons in human brain: a diffusion tensor tractography study. *Neuroimage* 2010;51:952–55
  23. Han BS, Hong JH, Hong C, et al. Location of the corticospinal tract at the corona radiata in human brain. *Brain Res* 2010;1326:75–80
  24. Kwon HG, Hong JH, Lee MY, et al. Somatotopic arrangement of the corticospinal tract at the medullary pyramid in the human brain. *Eur Neurol* 2011;65:46–49
  25. Oldfield RC. The assessment and analysis of handedness: the Edinburgh inventory. *Neuropsychologia* 1971;9:97–113
  26. Behrens TE, Johansen-Berg H, Woolrich MW, et al. Non-invasive mapping of connections between human thalamus and cortex using diffusion imaging. *Nat Neurosci* 2003;6:750–57
  27. Behrens TE, Berg HJ, Jbabdi S, et al. Probabilistic diffusion tractography with multiple fibre orientations: what can we gain? *Neuroimage* 2007;34:144–55
  28. Smith SM, Jenkinson M, Woolrich MW, et al. Advances in functional and structural MR image analysis and implementation as FSL. *Neuroimage* 2004;23(suppl 1):S208–19
  29. Mark VW, Taub E, Perkins C, et al. Poststroke cerebral peduncular atrophy correlates with a measure of corticospinal tract injury in the cerebral hemisphere. *AJNR Am J Neuroradiol* 2008;29:354–58
  30. Stovring J, Fernando LT. Wallerian degeneration of the corticospinal tract region of the brain stem: demonstration by computed tomography. *Radiology* 1983;149:717–20
  31. Quinones-Hinojosa A, Lyon R, Du R, et al. Intraoperative motor mapping of the cerebral peduncle during resection of a midbrain cavernous malformation: technical case report. *Neurosurgery* 2005;56:E439, discussion E439