ON-LINE APPENDIX

Methods 1: Evaluation of the Conventional MR Imaging Features of WNT-Subgroup Medulloblastoma

T1, T2, FLAIR, DWI, and ADC signal properties of the tumor were described as being hypo-, iso-, or hyperintense compared with those of the cerebellar cortex. For ADC hypointense signal, an additional, subjective grading system was used that included categories of hypointense, hypointense +, and hypointense ++. On postcontrast T1-weighted images, signal enhancement, when present, was evaluated by using 3 criteria: "extent" (ie, whether the entire tumor or only portions were enhanced), "homogeneity" (ie, homogeneous versus inhomogeneous), and "magnitude" (ie, faint, moderate, or avid). When a tumor was not entirely enhancing and/or enhancement was inhomogeneous, the magnitude of enhancement was scored on the basis of the most pronounced enhancement within the tumor. Similarly, the diffusion-weighted and ADC signal properties of the tumors were recorded on the basis of the highest and lowest signal observed within the tumor field, respectively. Only solid tumor areas were evaluated when describing the overall signal properties of the tumors (ie, cystic, necrotic, and hemorrhagic tumor areas were not considered). For additional explanation, see On-line Figs 1 and 2).

Additional tumor features, including cysts, necrosis, and intratumoral hemorrhage, were also assessed. Cysts were defined as well- and smoothly marginated fluid-filled spaces within the tumors or along their periphery. The latter was differentiated from sequestrated CSF spaces (eg, remnants of the fourth ventricle) on the basis of their FLAIR signal properties: Cysts typically exhibited higher signal than did normal CSF. Necrosis was considered present when the margins of the intratumoral fluid-filled spaces were less defined and irregular. These criteria worked well in most cases, but on rare occasions, distinguishing the 2 was challenging. Depending on equipment availability, the presence of intratumoral hemorrhage was evaluated on T2-weighted fast spin-echo or T2-weighted gradient-echo images. If both image types were available, then the T2-weighted gradient-echo image analysis took precedence. No distinction was made between hemorrhage and possible calcifications; all markedly T2-hypointense lesion components on these images were assumed to represent hemorrhages, though some of those may have corresponded to dystrophic calcifications. In the patient who had only a preoperative CT study, the images were evaluated for cysts, necrosis, and hemorrhage, but not for signal properties.

Methods 2: Preoperative Evaluation of Anatomic Tumor Features

The evaluation began with a standardized description of the primary location and CSF space involvement (ie, preoperative primary anatomic features) of the tumor. Categories of posterior fossa CSF-space involvement included the fourth ventricle, the foramen of Magendie, the cisterna magna, the foramen magnum, the foramina of Luschka, and the CP angle cisterns. The first tumor laterality score (ie, LS-1) was assigned on the basis of the pattern of involvement of the "lateralized" CSF spaces (ie, the foramina of Luschka and the CP angle cisterns: L1 for left-sided; R1 for right-sided; and L1, R1 for bilateral involvement). The LS-1 scores of each tumor were then consolidated into net scores (LS-1c) for each patient; thus, the tumor with only bilateral foramen of Luschka involvement was assigned an LS of zero, indicating that no unequivocal imaging sign of laterality was found.

The following examples explain the calculation of laterality scores LS-1 and LS-1c (based on preoperative primary anatomic features):

- A tumor with bilateral foramen of Luschka involvement received an LS-1 of L1, R1; hence, LS-1c was zero, whereas a tumor with involvement of the right foramen of Luschka and right CP angle cistern received an LS-1 of R2; consequently, LS-1c was R2, too.
- A tumor involving the left foramen of Luschka, the foramen of Magendie, the cisterna magna, and the foramen magnum received an LS-1c of L1.
- A tumor involving only the fourth ventricle received LS-1c of zero.

Next, we assessed secondary parenchymal structure invasion (preoperative secondary anatomic features). The anatomic structures evaluated included the bilateral superior cerebellar peduncles, middle cerebellar peduncles, inferior cerebellar peduncles, dentate nuclei, the floor of the fourth ventricle (ie, the tegmentum of the pons), the posterolateral sectors of the brain stem, and the cerebellar hemispheres. In each category, lesion involvement was scored as being left-sided, right-sided, or bilateral. When lesion involvement was thought to be bilateral and one side appeared to be more involved than the other, then the dominant side received a score of 2 and the subdominant side, a score of 1. Accordingly, a second LS was then recorded for each tumor (LS-2), and a consolidated version of this score was later recorded (LS-2c) by following the described method for deriving LS-1c.

The following example explains the calculation of laterality scores LS-2 and LS-2c (based on preoperative secondary anatomic features):

- A tumor involving the left superior and middle cerebellar peduncles and both dentate nuclei received an initial LS of L3, R1, which was subsequently consolidated to an LS-2c of L2.
- A tumor involving both the superior cerebellar peduncle (right more than left) and the right dentate nucleus received an initial LS of R3, L1, which was subsequently consolidated to an LS-2c of R2.

After this, an aggregate LS (LS-3) was calculated and then consolidated (LS-3c) for all tumors on the basis of all preoperative imaging data (ie, primary and secondary anatomic features) arising from steps 1 and 2.

The following example explains the calculation of laterality scores LS-3 and LS-3c (based on preoperative primary and secondary anatomic features):

- A tumor that was determined to involve the right foramen of Luschka (R1) on the basis of preoperative primary anatomic features and then determined to involve the bilateral dentate nucleus and right posterolateral brain stem (R2, L1) on the basis of preoperative secondary anatomic features received an aggregate LS of R3, L1, which was then consolidated to an LS-3c of R2.

On the basis of the LS-3 and the pattern of CSF-space involvement (ie, fourth ventricle versus cisterna magna, cerebellopontine angle cistern, and so forth), each tumor received a group assignment describing its location in more specific terms, such as apparent midline (LS-3 = 2 or less), off-midline (LS-3 = 3 or higher), apparent intraventricular (ie, fourth ventricle involved with or without involvement of other posterior fossa CSF spaces), or extraventricular (ie, no involvement of the fourth ventricle). Possible subtypes based on all preoperative imaging data were as follows: 1) midline-intraventricular; 2) midline-extraventricular (ie, tumor in infravermian location with dominant involvement of the cisterna magna); 3) off-midline–intraventricular (ie, tumor in an intraventricular but eccentric location centered on the foramen of Luschka and lateral recess of the fourth ventricle on 1 side); and 4) off-midline–extraventricular (ie, dominant involvement of the CP angle cistern on 1 side).

Methods 3: Postoperative Imaging Evaluation of Anatomic Tumor Features

Laterality scores were generated to describe the postoperative cerebellar and brain stem lesions (LS-4), which were subsequently consolidated (LS-4c) by using the same evaluation and scoring concept described for the preoperative studies above.

Methods 4: Combined Pre- and Postoperative Evaluation of Location Features

Conflicts between preoperative and postoperative findings of involvement of specific anatomic structures or areas of the cerebellum and brain stem were resolved on the basis of the assumption that postoperative lesions more accurately indicate invasion by the original tumor.

The following example explains the calculation of laterality scores LS-5 and LS-5c (based on the preoperative primary and secondary anatomic features and the postoperative damage pattern):

- If involvement of the left dentate nucleus was suggested on the preoperative study but the area was totally intact on the postoperative examination, then the initial LS value for that anatomic structure was disregarded in determining the LS-5. However, if the involvement of a specific anatomic structure was suggested on the preoperative study and was subsequently confirmed on the postoperative imaging, then a double LS value (eg, R2) was assigned to that structure. When only the postoperative imaging study revealed a lesion, then only a simple LS value (eg, R1) was assigned, with the intent being to compensate for the possibility that inadvertent surgical damage may have occurred.

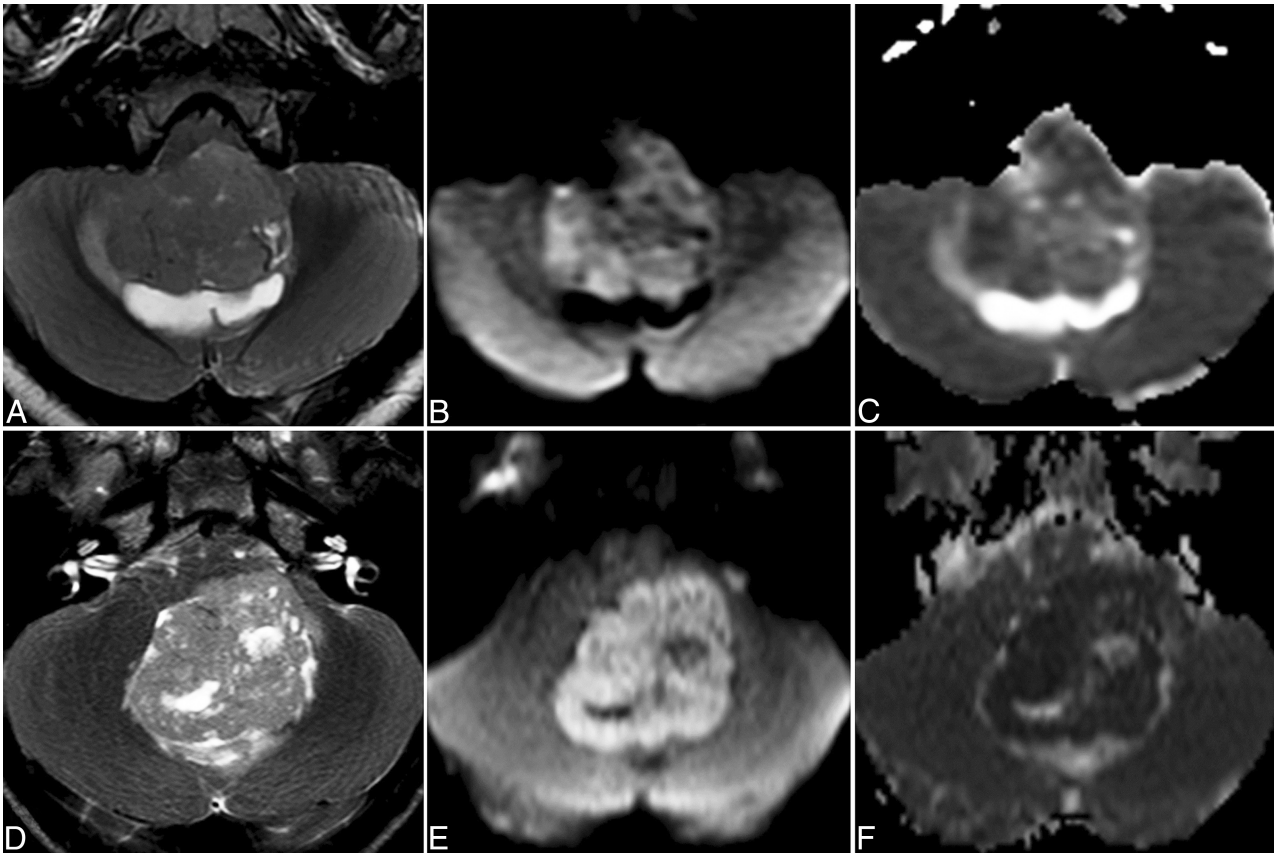

ON-LINE FIG 1. Grading of ADC signal variations in WNT-subgroup medulloblastomas. Subtype B (midline, extraventricular) medulloblastoma exhibits isointense signal in T2WI (*A*), hyperintense signal in DWI (*B*), and inhomogeneous signal, including moderate hypointense signal in the ADC map image (*C*). Subtype C (off-midline, intraventricular) medulloblastoma shows relative hyperintense signal in T2WI (*D*) and DWI (*E*) and markedly low signal (hypointense signal+) in the ADC map image (*F*).

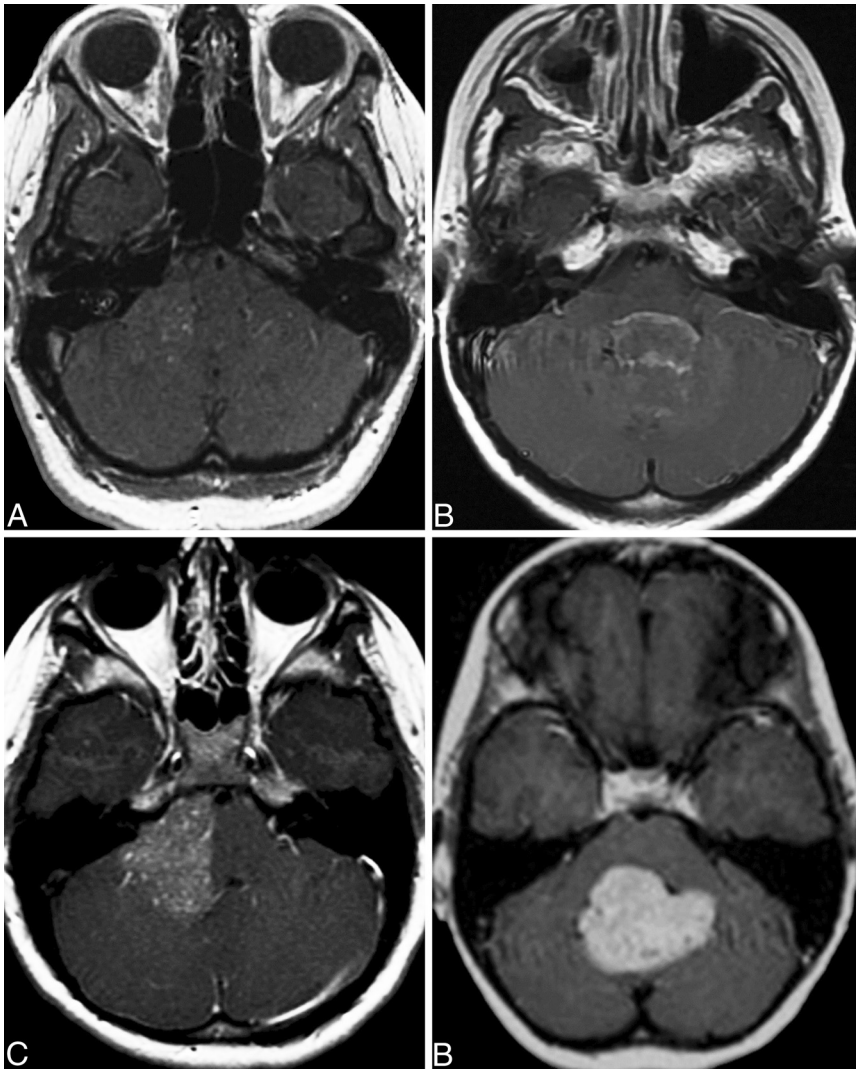

ON-LINE FIG 2. Various enhancement patterns after IV injection of gadolinium-based contrast medium in WNT-subgroup medulloblastomas. Subtype D tumor in the right cerebellopontine angle shows a few punctate-enhancing foci, while most of the tumor does not show perceptible enhancement (*A*). Subtype A tumor is associated with overall inhomogeneous, moderate enhancement, though large portions of the tumor do not show enhancement (*B*). Another subtype D tumor exhibits somewhat inhomogeneous, moderate enhancement, but the entire tumor enhances (*C*). Another subtype A tumor in which the entire lesion shows homogeneous and avid enhancement (*D*).

On-line Table 1: Patterns of posterior fossa CSF-space involvement in WNT-subgroup medulloblastoma

Fourth Ventricle		Foramen of Luschka		Cerebellopontine Angle Cistern[a]		Cisterna Magna		Foramen of Magendie	
Involved?	No. (%)	Involved?	No. (%)	Involved?	No. (%)	Involved?	No. (%)	Involved?	No. (%)
No	5 (31.25)	No	4 (25)	No	12 (75)	No	11 (68.75)	No	8 (50)
Yes	11 (68.75)	Left	5 (31.25)	Left	2 (12.5)	Yes	5 (31.25)[b]	Yes	8 (50)
		Right	6 (37.5)	Right	2 (12.5)				
		Bilateral	1 (6.25)	Bilateral	0				

[a] The tumor was centered on the cerebellopontine angle cistern (with involvement of the foramen of Luschka but without intraventricular extension) in 3 cases: 2 on the right side, and 1 on the left side. The left cerebellopontine angle cistern was involved in another case, but that tumor also had a dominant intraventricular component.

[b] In all 5 cases, the lesion extended cranially into the foramen of Magendie; in 3 cases, it also extended caudally to the foramen magnum. In 2 of the 5 cases, the tumor did not extend into the fourth ventricle; the remaining 3 partially involved the lower part of the fourth ventricle. Associated foramen of Luschka involvement was seen unilaterally in 3 cases and bilaterally in 1 case.

On-line Table 2: Laterality scores at different stages of the lesion-involvement evaluation process

LS	No.	Mean	SD	Range		*P* Value
				Minimum	Maximum	
LS-1c	16	0.94	0.77	0.00	2.00	
LS-2c	16	2.00	1.15	1.00	5.00	.0039[a]
LS-3c	16	2.94	1.53	1.00	6.00	.0010[b]
LS-4c	16	3.06	1.48	1.00	6.00	.6797[c]
LS-5c	16	4.69	2.09	1.00	8.00	.0002[d]

[a] LS-2c vs LS-1c.
[b] LS-3c vs LS-2c.
[c] LS-4c vs LS-3c.
[d] LS-5c vs LS-4c.

On-line Table 3: Agreement among reviewers about the patterns of posterior fossa CSF-space involvement based on preoperative imaging data in WNT-subgroup medulloblastoma: 4th ventricle

Fourth Ventricle Involved?				
	Reviewer 1			
Reviewer 2	No	Yes	Total	Cohen κ Coefficient[a]
No	5	0	5	1.00
Yes	0	11	11	Perfect agreement
Total	5	11	16	

[a] Cohen κ coefficients are presented as an assessment of the interobserver agreement of posterior fossa CSF-space involvement.

On-line Table 4: Agreement among reviewers about the patterns of posterior fossa CSF-space involvement based on preoperative imaging data in WNT-subgroup medulloblastoma: foramen of Luschka

Foramen of Luschka Involved?						
	Reviewer 1					Cohen κ
Reviewer 2	No	Left	Right	Bilateral	Total	Coefficient[a]
No	4	0	0	0	4	1.00
Left	0	5	0	0	5	Perfect
Right	0	0	6	0	6	agreement
Bilateral	0	0	0	1	1	
Total	4	5	6	1	16	

[a] Cohen κ coefficients are presented as an assessment of the interobserver agreement of posterior fossa CSF-space involvement.

On-line Table 5: Agreement among reviewers about the patterns of posterior fossa CSF-space involvement based on preoperative imaging data in WNT-subgroup medulloblastoma: Cerebellopontine angle cistern

Cerebellopontine Angle Cistern Involved?						
	Reviewer 1					Cohen κ
Reviewer 2	No	Left	Right	Yes	Total	Coefficient[a]
No	12	0	0	0	12	0.85
Left	0	1	0	0	1	Almost perfect
Right	0	0	2	0	2	agreement
Yes	0	1	0	0	1	
Total	12	2	2	0	16	

[a] Cohen κ coefficients are presented as an assessment of the interobserver agreement of posterior fossa CSF-space involvement.

On-line Table 6: Agreement among reviewers about the patterns of posterior fossa CSF-space involvement based on preoperative imaging data in WNT-subgroup medulloblastoma: cisterna magna

Cisterna Magna Involved?				
	Reviewer 1			
Reviewer 2	No	Yes	Total	Cohen κ Coefficient[a]
No	11	0	11	1.00
Yes	0	5	5	Perfect agreement
Total	11	5	16	

[a] Cohen κ coefficients are presented as an assessment of the interobserver agreement of posterior fossa CSF-space involvement.

On-line Table 7: Agreement among reviewers about the patterns of posterior fossa CSF-space involvement based on preoperative imaging data in WNT-subgroup medulloblastoma: foramen of Magendie

Foramen of Magendie Involved?				
	Reviewer 1			
Reviewer 2	No	Yes	Total	Cohen κ Coefficient[a]
No	5	0	5	0.63
Yes	3	8	11	Substantial agreement
Total	8	8	16	Perfect agreement

[a] Cohen κ coefficients are presented as an assessment of the interobserver agreement of posterior fossa CSF-space involvement.

On-line Table 8: Agreement among reviewers in determining location-based group assignment based only on preoperative imaging data of each tumor[a]

Reviewer 2	Reviewer 1				Total
	Midline-Intraventricular (Subtype A)	Midline-Extraventricular (Subtype B)	Off-Midline–Intraventricular (Subtype C)	Off-Midline–Extraventricular (Subtype D)	
Midline-intraventricular (subtype A)	3	0	1	0	4
Midline-extraventricular (subtype B)	0	2	0	0	2
Off-midline–intraventricular (subtype C)	3	0	4	0	7
Off-midline–extraventricular (subtype D)	0	0	0	3	3
Total	6	2	5	3	16

[a] Cohen κ coefficient = 0.65 (substantial agreement). Cohen κ coefficient is presented as an assessment of the interobserver agreement for determining group assignment of each tumor.

On-line Table 9: Interobserver variability of laterality scores at different stages of the imaging evaluation process

LS	No.	Reviewer 1				Reviewer 2				ICC[a]	
		Mean	SD	Minimum	Maximum	Mean	SD	Minimum	Maximum		
LS-1c	16	0.94	0.77	0.00	2.00	0.88	0.72	0.00	2.00	0.94	Excellent
LS-2c	16	2.00	1.15	1.00	5.00	2.44	1.50	0.00	5.00	0.71	Good
LS-3c	16	2.94	1.53	1.00	6.00	3.31	2.02	0.00	6.00	0.85	Excellent
LS-4c	16	3.06	1.48	0.00	6.00	3.31	1.66	0.00	7.00	0.85	Excellent
LS-5c	16	4.69	2.09	1.00	8.00	5.50	2.78	1.00	11.00	0.73	Good

Note:—ICC indicates intraclass correlation coefficient.

[a] Intraclass correlation coefficients are presented as an assessment of the interobserver variability of laterality scores.