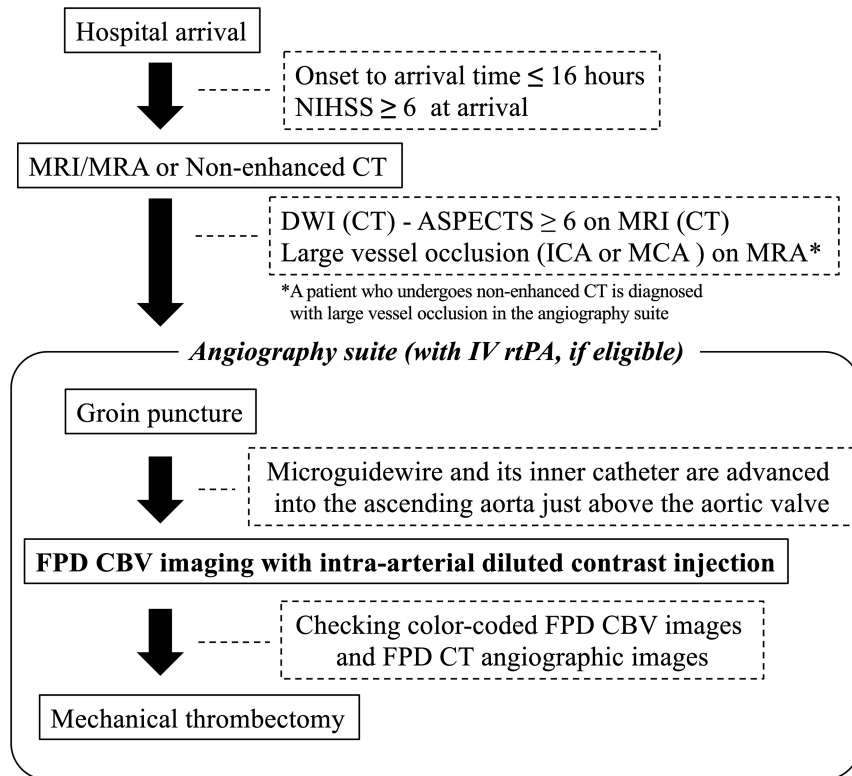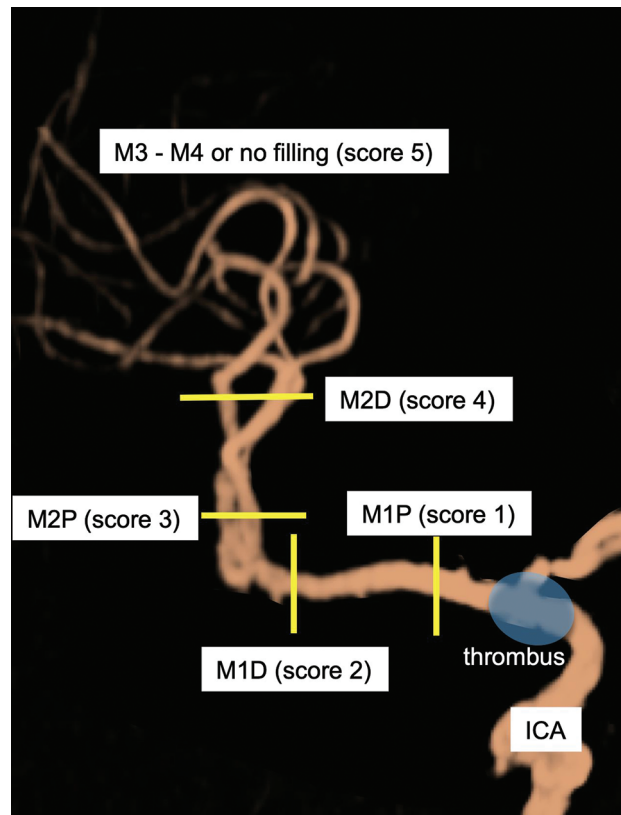


ONLINE FIG 1. MR imaging–based protocol for mechanical thrombectomy.



ONLINE FIG 2. Diagrammatic representation of assignment of the visualization score in the right ICA-T occlusion case. In ICA-T occlusion, if the M1 proximal segment is visualized, a score of 1 is assigned. Similarly, if the M1 distal, M2 proximal, or M2 distal segment is visualized, a score of 2, 3, or 4 is assigned, respectively. If MCA M3 and M4 segments are visualized or no significant visualization is found, a score of 5 is assigned.