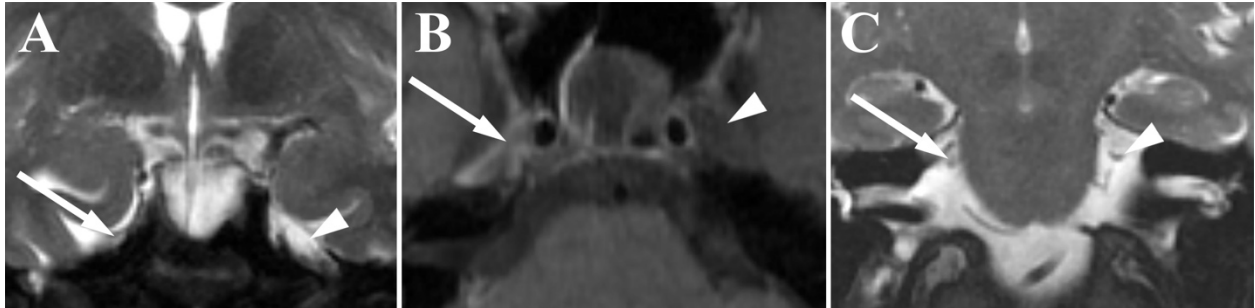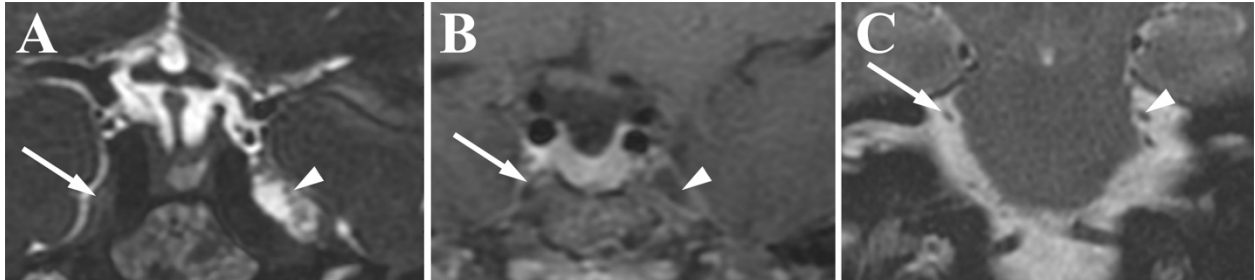
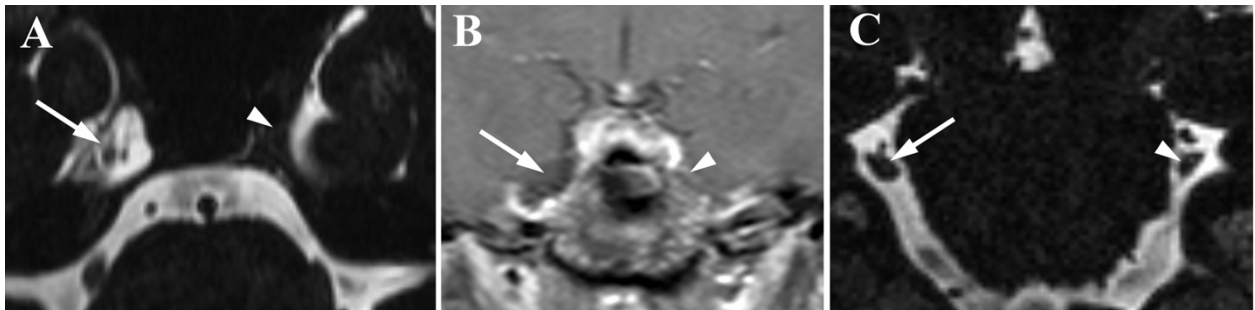


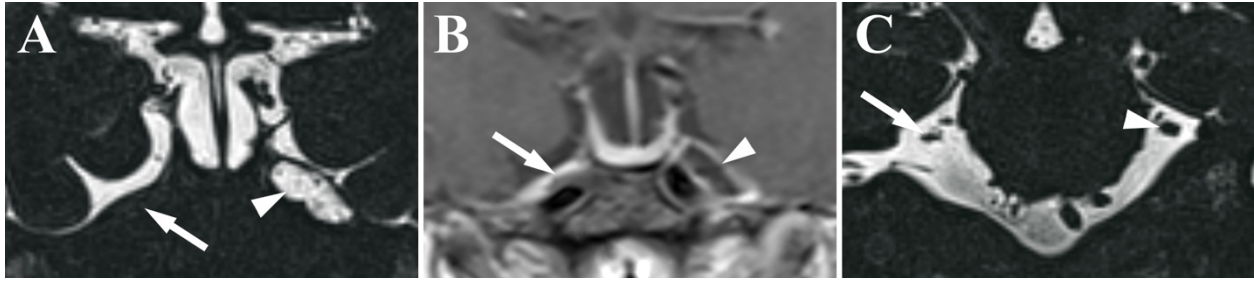
Supplemental Figure 1. (A) Coronal T2- and (B) postcontrast axial T1-weighted images in Patient 1 showing absence of Meckel's cave (arrow) compared to the normal side (arrowhead). (C) Coronal T2-weighted image shows atrophy of the trigeminal nerve ipsilateral to the side of collapse (arrow) compared to the normal contralateral nerve (arrowhead).



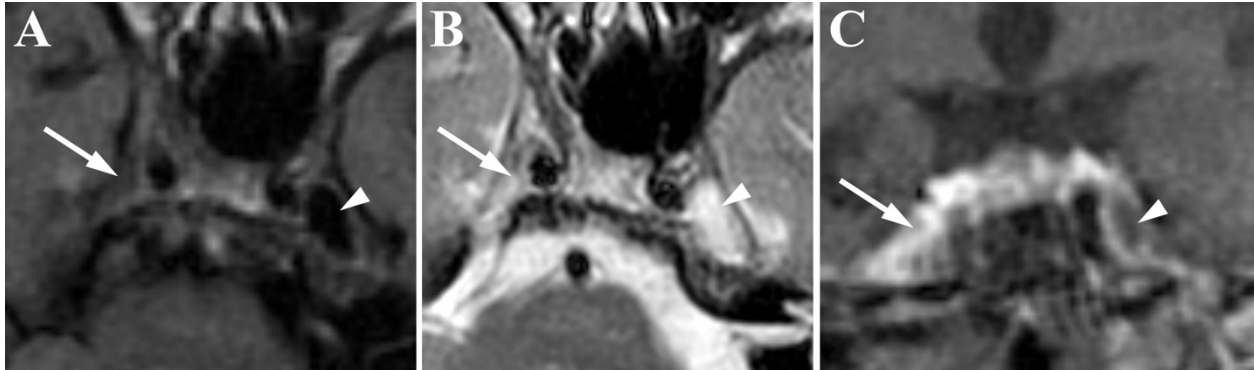
Supplemental Figure 3. (A) Coronal CISS and (B) postcontrast coronal T1-weighted images in Patient 2 showing absence of Meckel's cave (arrow) compared to the normal side (arrowhead). (C) Coronal CISS image shows atrophy of the trigeminal nerve ipsilateral to the side of collapse (arrow) compared to the normal contralateral nerve (arrowhead).



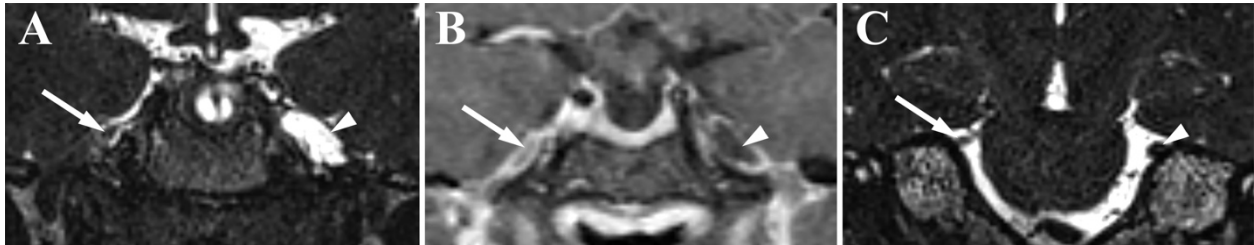Supplemental Figure 3. (A) Axial T2-SPACE and (B) postcontrast coronal T1-weighted images in Patient 3 showing absence of Meckel's cave (arrow) compared to the normal side (arrowhead). (C) Coronal T2-SPACE image shows atrophy of the trigeminal nerve ipsilateral to the side of collapse (arrow) compared to the normal contralateral nerve (arrowhead).



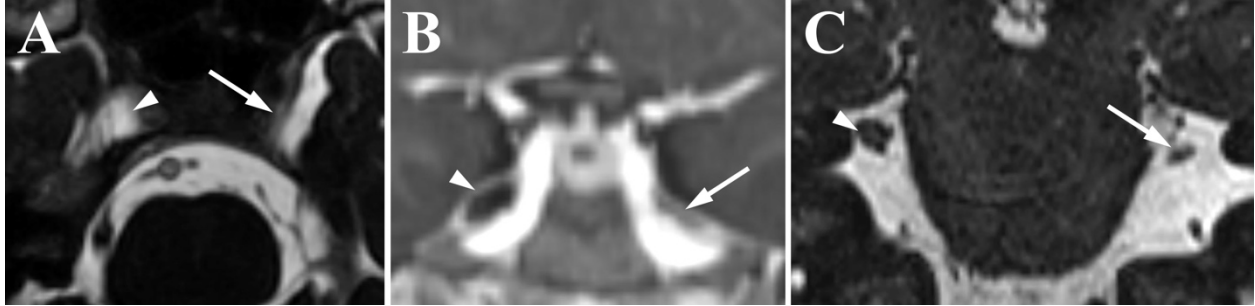Supplemental Figure 4. (A) Coronal T2-SPACE and (B) postcontrast coronal T1-weighted images in Patient 4 showing absence of Meckel's cave (arrow) compared to the normal side (arrowhead). (C) Coronal T2-SPACE image shows atrophy of the trigeminal nerve ipsilateral to the side of collapse (arrow) compared to the normal contralateral nerve (arrowhead).



Supplemental Figure 5. (A) Noncontrast Axial T1-, (B) axial T2-, and (C) postcontrast coronal T1-weighted images in Patient 5 showing absence of Meckel's cave (arrow) compared to the normal side (arrowhead).



Supplemental Figure 6. (A) Coronal T2-SPACE and (B) postcontrast coronal T1-weighted images in Patient 6 showing absence of Meckel's cave (arrow) compared to the normal side (arrowhead). (C) Coronal T2-SPACE image shows atrophy of the trigeminal nerve ipsilateral to the side of collapse (arrow) compared to the normal contralateral nerve (arrowhead).



Supplemental Figure 7. (A) Axial CISS and (B) postcontrast coronal T1-weighted images in Patient 7 showing absence of Meckel's cave (arrow) compared to the normal side (arrowhead). (C) Coronal CISS image shows atrophy of the trigeminal nerve ipsilateral to the side of collapse (arrow) compared to the normal contralateral nerve (arrowhead).

**Supplemental Table 1.** Summary of patient information.

Patient	Age	TN	Age at TN Diagnosis	Side of TN	Additional Relevant Conditions	Side of Absent Meckel's	Atrophy of CN V (Side)	Medical Treatment	Response to Medical Treatment	Intervention 1	Response to Intervention 1	Intervention 2	Response to Intervention 2
1	79	Yes	49	Right	Abnormal elevation of CRP and ESR	Right	Yes (Right)	Carbamazepine, gabapentin	Initial improvement with recurrence	MVD	Initial mild improvement with recurrence	Balloon Compression	Adequate response to treatment
2	61	Yes	36	Right		Right	Yes (Right)	Carbamazepine	Initial improvement with recurrence	MVD	Initial improvement with recurrence	GK	No post-procedure follow up
3	41	Yes	39	Left		Left	Yes (Left)	Carbamazepine, gabapentin	Improved				
4	42	Yes	42	Right	Intracranial Hypertension	Right	Yes (Right)	Carbamazepine	Initial improvement with recurrence	Stereotactic Radiosurgery	Adequate response to treatment		
5	94	Yes	80	Right		Right	Yes (Right)	Carbamazepine, gabapentin, Carbamol, Trileptal,	No response	Rhizotomy	Initial improvement with symptom recurrence		
6	42	Yes	40	Right	Intracranial Hypertension	Right	Yes (Right)	Carbamazepine, gabapentin, tramadol, topiramate, lycrica	No response				
7	43	Yes	40	Left		Left	Yes (Left)	Carbamazepine, oxcarbazepine, phentermine, diazepam, hydrochlorothiazide	No follow up				

**Supplemental Table 2.** Individual scan data and CN V measurements.

Patient	Sequence	Side of Absent Meckel's Cave	Ipsilateral CN V Cross Section (mm)	Contralateral CN V Cross Section (mm)	Ipsilateral CN V Area (mm <sup>2</sup> )	Contralateral CN V Area (mm <sup>2</sup> )	Scanner
1	Cor T2	R	2.1 x 1.5	3.0 x 2.1	3.8	6.4	GE Signa 1.5T
2	CISS	R	1.5 x 2.1	3.4 x 2.6	2.6	4.9	GE Signa 1.5T
3	T2 SPACE	L	2.3 x 1.9	2.9 x 2.4	4.9	7.3	Siemens Skyra 3T
4	T2 SPACE	R	2.7 x 1.3	2.6 x 2.3	3.1	4.8	Siemens Vida 3T
5	No Coronal	R	--	--	--	--	GE Signa 1.5T
6	T2 SPACE	R	2.2 x 2.0	2.4 x 3.1	4.7	6.5	Siemens Skyra 3T
7	CISS	L	2.1 x 2.1	3.3 x 2.7	4.5	8.7	Siemens Skyra 3T
<b>Mean and SD cross-sectional area of the cisternal segment of trigeminal nerve near in mm<sup>2</sup></b>					<b>3.9 ± 0.9</b>	<b>6.4 ± 1.5</b>	<b>P value &lt;0.001*</b>

\* P value was calculated using paired t-test