

Are your MRI contrast agents cost-effective?
Learn more about generic Gadolinium-Based Contrast Agents.



AJNR

Jugular Bulb Diverticula in Medial Petrous Bone

Jerry Stern and Marvin Goldenberg

AJNR Am J Neuroradiol 1980, 1 (2) 153-155
<http://www.ajnr.org/content/1/2/153>

This information is current as
of May 2, 2024.

Jugular Bulb Diverticula in Medial Petrous Bone

Jerry Stern¹
Marvin Goldenberg¹

Upward extension or diverticulum of the jugular bulb is rare. Most often, it protrudes into the middle ear. Three patients are reported in whom direct superior extension from the medial portion of the jugular bulb resulted in a defect in the medial part of the petrous bone. In this position, a jugular bulb diverticulum relates directly to the posterior wall of the internal auditory canal. The distinctive radiographic characteristics of this entity obviate unnecessary investigation and surgery. Encroachment on the internal auditory canal may possibly contribute to neurosensory hearing deficit.

Most often, diverticula of the jugular bulb involve the middle ear, although two reports describe jugular bulb diverticula relating to the internal auditory canal [1, 2]. Dilenge [1] reported two patients with a jugular "notch" encroaching on the posterior structures of the inner ear. Noyek et al. [2] described another patient in whom they believed a high jugular bulb involved the internal auditory canal. We describe three additional cases of a jugular bulb diverticulum protruding into the medial part of the petrous bone. Corroborative documentation by lateral tomography and jugular venography demonstrates the diverticulum immediately posterior to the internal auditory canal. In one patient the defect resulted in a break in the posterior wall of the internal auditory canal.

Case Reports

Case 1

A 74-year-old woman had increasing tinnitus in the left ear for 2 years and bilateral hearing impairment. Rinne test was positive bilaterally and Weber's test was nonlocalizing. Audiometry confirmed a bilateral neurosensory hearing deficit. Tympanometry and electro-nystagmography were normal.

Anteroposterior and lateral hypocycloidal tomography (figs. 1A and 1B) revealed a 15 × 10 × 10 mm defect with smooth, corticated margins in the posteromedial part of the left petrous bone. The posterior wall of the internal auditory canal had been thinned and in one area completely eroded. The defect appeared to be in continuity with the jugular bulb. Jugular venography confirmed that the bony defect was due to a diverticulumlike upward extension of the jugular bulb (figs. 1C and 1D).

Case 2

A 48-year-old woman sought medical attention because of progressive pain in the left ear for 6 months. She had had chronic headaches for over 15 years and tinnitus in the left ear for 4 years.

Received July 30, 1979; accepted after revision September 29, 1979.

¹ Department of Diagnostic Radiology, McGill University, and Jewish General Hospital, 3755 Cote St. Catherine Rd., Montreal, Quebec H3T 1E2. Address reprint requests to J. Stern.

This article appears in March/April 1980 *AJNR* and June 1980 *AJR*.

AJNR 1:153-155, March/April 1980
0195-6108/80/0102-0153 \$00.00
© American Roentgen Ray Society

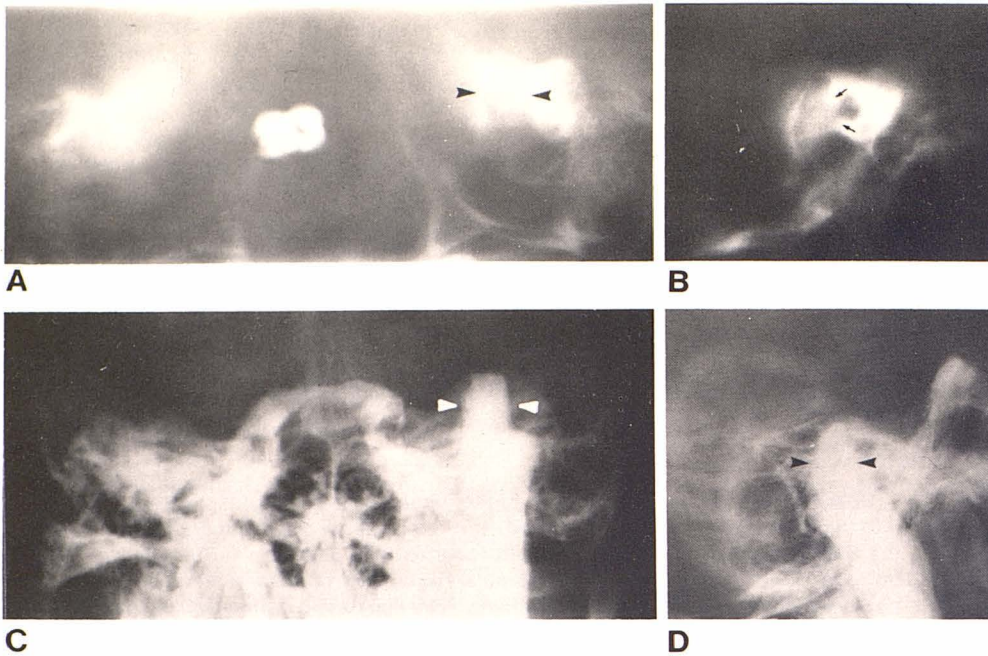


Fig. 1.—Case 1. Anteroposterior (A) and lateral (B) tomograms. Smooth diverticulumlike defect in left petrous bone (arrowheads). Anterior border of defect encroaches on internal auditory canal with discontinuity of cortex of posterior wall (arrows). Anteroposterior (C) and lateral (D) jugular venograms. Defect (arrowheads) is upward extension of jugular bulb in petrous bone.

Inspection revealed no external abnormality. The Rinne test was positive on the left and Weber's test was midline. Tympanometry and audiometry were normal; however the short increment sensitivity index suggested a retrocochlear abnormality on the left.

Hypocycloidal tomography and subsequent jugular venography (fig. 2) demonstrated an extension of the left jugular bulb upward into the petrous bone with marked thinning of the posterior wall of the internal auditory canal.

Case 3

A 66-year-old woman had a painful right ear with blood-tinged discharge. She also complained of poor hearing in both ears.

Examination revealed a perforation of the right tympanic membrane with associated otitis media. Audiometry documented a moderate to severe neurosensory hearing deficit in the right ear and a moderate mixed loss in the left ear.

Tomography (fig. 3) showed a large right jugular bulb associated with a well circumscribed defect involving the internal auditory canal. There was no further radiographic investigation.

Discussion

Normally, the apex of the jugular foramen lies below the inferior rim of the hypotympanum from which it is separated by a bony plate of varying thickness [1, 3-6]. Superolateral extension of the jugular bulb will occur in the middle ear. Should the medial aspect of the jugular bulb protrude directly upward, the medial part of the petrous bone will erode, with encroachment on the posterior wall of the internal auditory canal.

Lateral Diverticulum in Tympanic Cavity

The incidence of a jugular bulb diverticulum protruding into the middle ear cavity is 6% [6]. This condition was first

described by Page in 1914 (discussed by Overton and Ritter [6] and Robin [7]). The myringotomy performed on his patient resulted in severe hemorrhage with eventual fatal sinus thrombosis. Gullane et al. [5] also reported three cases with superolateral displacement of the jugular bulb. In one instance the bulb had extended laterally on a stalk and was seen as a mass in the external auditory canal.

The origin of an extension of the jugular bulb into the middle ear is obscure. It is possibly related to asymmetric flow in the sinusojugular system. This could be due to hypoplasia [8] or acquired thrombosis [9] of the contralateral drainage pathways. Infection [7] or abnormal membranous bone formation related to chondrodystrophy [10] have also been postulated as possible causes.

The extension of the superolateral part of the jugular bulb into the middle ear is variable. As pointed out by Lloyd et al. [11], it can be suspected if there is dehiscence of the floor of the hypotympanum without irregular erosive changes in the middle ear. Confirmation may be achieved by jugular venography.

Medial Diverticulum in Medial Petrous Bone

Direct upward extension of the jugular bulb into the medial part of the petrous bone is a distinct entity that is even more unusual than jugular bulb diverticulum in the middle ear. By encroaching on the internal auditory canal, the defect may contribute to neurosensory hearing deficit. Our cases 1 and 2 complained of tinnitus, and all three patients had neurosensory hearing loss, although with case 1 the impairment was bilateral. Similarly, the patient described by Noyek et al. [2] and one of the two patients of Dilenge [1] had neurosensory hearing impairment.

The plain film and tomographic findings of a medial diverticulum are usually diagnostic. If required, confirmation can

Fig. 2.—Case 2. Anteroposterior (A) and lateral (B) tomograms. Characteristic defect (arrowheads) has smooth cortical margins in left petrous bone. Posterior wall of internal auditory canal intact but markedly thinned (arrows). C and D, Jugular venograms. Lesion in continuity with left jugular vein represents diverticulum of roof of jugular bulb (arrowheads).

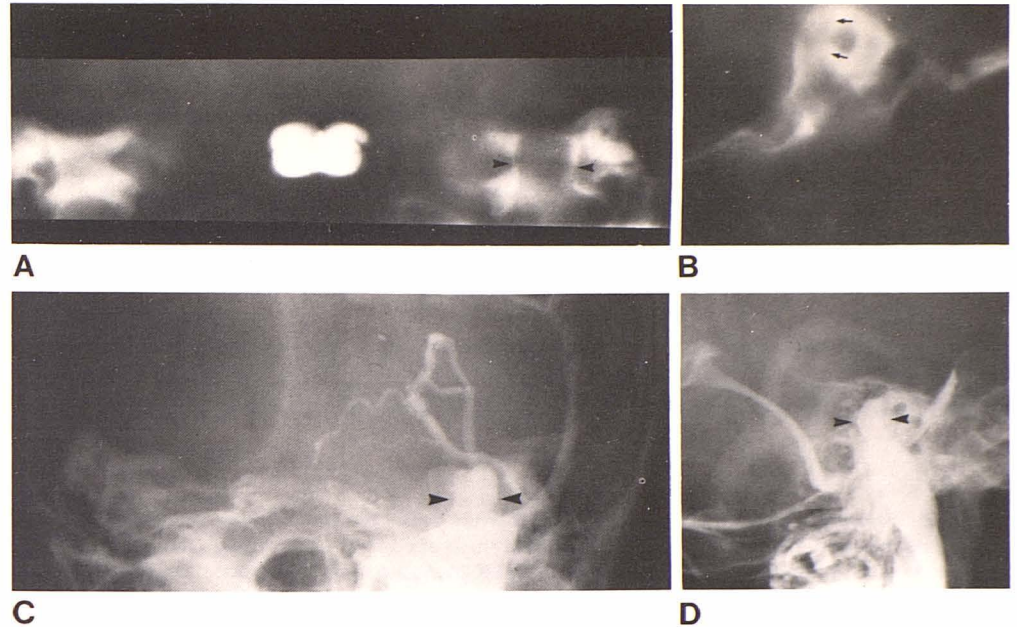


Fig. 3.—Case 3. Anteroposterior tomogram through posterior part of petrous bones. Small defect extends above floor of right internal auditory canal. Margins of defect are again regular and sclerotic.

be obtained by jugular venography. In all of our patients there was a lucent, diverticulumlike defect in the postero-medial part of the petrous bone. The base of the defect was in direct contact with the superior border of the jugular foramen without an intervening bony plate.

Lateral tomography demonstrates the nearness of the defect to the internal auditory canal. In cases 1 and 2, there was marked thinning of the posterior wall of the internal auditory canal, and in case 1 (fig. 1) there was also a localized complete erosion of this area. On both anteroposterior and lateral tomography the lucent defect in the petrous bone is characteristically sharply circumscribed, with sclerotic margins.

Recognition of these features should be sufficient to rule out neoplastic conditions involving the internal auditory canal or petrous bone. Thus, invasive investigations and biopsy with its attendant risks can be avoided.

ACKNOWLEDGMENTS

We thank Edie Gerber for typing the manuscript, David Saxe and Russell Proulx for photographic reproductions, and B. Zavalkoff for technical assistance.

REFERENCES

1. Dilenge D. The jugular notch. *J Can Assoc Radiol* 1977;28:274-277
2. Noyek AM, Holgate RC, Wortzman G, et al. Sophisticated radiology in otolaryngology. *J Otolaryngol* 1977;6:73-94
3. Cornell SH. Jugular venography. *AJR* 1969;106:303-307
4. Farrell FW, Hantz O. Protruding jugular bulb presenting as a middle ear mass: case report and brief review. *AJR* 1977;128:685-687
5. Gullane PJ, Ruby RRF, Rounthwaite FJ, Babb JW, Wong GL. The high jugular bulb. *J Otolaryngol* 1976;5:437-441
6. Overton SB, Ritter FN. A high placed jugular bulb in the middle ear: a clinical and temporal bone study. *Laryngoscope* 1973;83:1986-1991
7. Robin PE. A case of upwardly situated jugular bulb in the left middle ear. *J Laryngol Otol* 1972;86:1241-1246
8. Moretti JA. Highly placed jugular bulb and conductive deafness secondary to sinusojugular hypoplasia. *Arch Otolaryngol* 1976;102:430-431
9. Gejrot T. Retrograde jugulography in the diagnosis of abnormality of the superior bulb of the internal jugular vein. *Acta Otolaryngol (Stockh)* 1964;57:177-180
10. West JM, Bandy BC, Jatek BW. Aberrant jugular bulb in the middle ear cavity. *Arch Otolaryngol* 1974;100:370-372
11. Lloyd TV, Aman MV, Johnson JC. Aberrant jugular bulb presenting as a middle ear mass. *Radiology* 1979;131:139-141