

Are your MRI contrast agents cost-effective?
Learn more about generic Gadolinium-Based Contrast Agents.



AJNR

Cysticercotic cyst of the septum pellucidum.

A B Dublin and B N French

AJNR Am J Neuroradiol 1980, 1 (2) 205-206
<http://www.ajnr.org/content/1/2/205.citation>

This information is current as
of May 2, 2024.

Cysticercotic Cyst of the Septum Pellucidum

ARTHUR B. DUBLIN¹ and BARRY N. FRENCH²

Cysts of the septum pellucidum, especially those producing symptomatic hydrocephalus, are rare. To our knowledge, this is the first report of a cysticercotic cyst of the septum pellucidum. The computed tomographic (CT) and other related radiologic findings of this entity are discussed.

Case Report

A 26-year-old Mexican-American woman was admitted for evaluation of occipital and frontal throbbing headaches. Her symptoms had increased in severity for 5 months and were exacerbated by bending over, and improved by assuming a supine position. CT scanning demonstrated a nonenhancing, rounded, homogeneous mass of cerebral spinal fluid density in the region of the septum pellucidum and anterior third ventricle (fig. 1A). Cerebral arteriography confirmed a lesion in the septum pellucidum.

Because of her deteriorating neurologic status, a decompressive drain was placed in the right lateral ventricle. Conray ventriculography with and without CT, was performed (fig. 1B). A mass, not communicating with the lateral ventricles, was demonstrated in front of the foramina of Monro in the region of the septum pellucidum.

A transcallosal frontal approach into the anterior horn of the left lateral ventricle revealed a bulging septum pellucidum which produced posterior displacement and compression of the interventricular foramina. Fine needle aspiration of the septum produced clear fluid without evidence of abnormal cells or organisms. A thin cystic cavity within the leaves of the septum pellucidum was partly removed and demonstrated several cysticercotic parasites. Marsupialization of the septum and remaining parts of the cyst into both anterior lateral ventricles resulted in clinical improvement.

Discussion

Clefts may occur within the septum pellucidum, commonly resulting in a normal cavum. This cavum usually appears radiographically as a small noncommunicating slit, and is an incidental and asymptomatic finding [1]. Occasionally, the slit may normally be prominent as demonstrated by CT. The main differential point between normal cavi and true cysts is obstructive hydrocephalus in the latter [2, 3].

Cysts producing symptoms due to increased pressure within the cavum itself are rare [2, 3]. Although Gubbay et al. [4] described symptoms due to dilatation of the cavum septi pellucidi, many authors including Shaw and Alvord [1]

suggest that normal cavi do not produce symptomatic obstruction. Headache, as demonstrated in our case, is the predominant clinical feature of cysts. Seizures and symptoms of increased intracranial pressure also occur frequently. Less common are gait disturbances, mental deterioration, and unilateral motor or sensory deficits [2].

The first two cases of pathologic cysts were reported by Dandy [5] in 1931. Since then, other cystic lesions have been described and have been well summarized [2, 3, 6-8]. To our knowledge, this case is the first report of a cysticercotic cyst of the septum pellucidum.

Oncospheres released from the eggs of the pork tapeworm *Taenia solium* may penetrate the gastric mucosa of man to disseminate to various tissues with a predilection for muscle, subcutaneous tissues, brain, and spinal cord. The clinical, pathologic, and CT findings of disseminated cerebral cysticercosis have been well described [9-15]. CT may show small areas of decreased attenuation that often enhance in the acute stage of parenchymal cysticercosis. Cerebral infarction, secondary to vascular occlusions produced by arachnoiditis and vasculitis, has been demonstrated [14]. The chronic stage of cysticercosis demonstrates multiple areas of nonenhancing calcification, some measuring 1-5 mm [16]. Homogeneous or ringlike contrast enhancement may be identified [14].

The differential diagnosis of a cyst of the septum pellucidum includes: ependymal and arachnoid cysts [3], subependymal astrocytomas [17, 18], other cystic gliomas [19], massive pituitary adenomas [20], cystic craniopharyngiomas [21], epidermoid and dermoid tumors [22], lipomas associated with agenesis of the corpus callosum [23], and rarely neuroepithelial (colloid or parafyseal) cysts [6].

The lack of material of fat density on CT tends to exclude lipomas and dermoids [22, 23]. A cystic glioma may show a CT pattern of enhancement identical to cysticercosis. This consists of a ring of enhancement with or without peripherally enhancing nodules [14, 19]. Ependymal and arachnoid cysts, unless complicated by infection, usually do not show enhancement. The lack of enhancement in our case and its location suggested exclusion of craniopharyngioma, epidermoid, and colloid cyst [21, 22, 24], but did not imply parasitic inactivity, especially because calcification was not

Received June 1, 1979; accepted after revision October 10, 1979.

¹ Department of Diagnostic Radiology, Section of Neuroradiology, University of California Davis Medical Center, 4301 X St., Room 214, Sacramento, CA 95817. Address reprint requests to A. B. Dublin.

² Department of Neurosurgery, University of California Davis Medical Center, Sacramento, CA 95817.

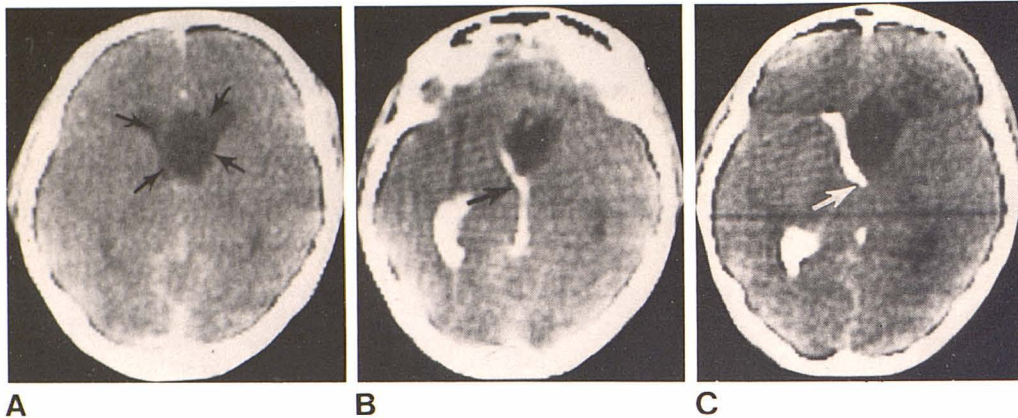


Fig. 1.—A, Contrast-enhanced CT scan. Oval cerebral spinal fluid density lesion (arrows) in region of septum pellucidum. Dilated anterior horns of lateral ventricles. B and C, Post-Contrast ventriculogram CT scans. Filling of right lateral ventricle and third ventricle. Nonfilling left lateral ventricle is identified. Cyst of septum pellucidum anterior to right foramen of Monro (arrows).

observed. Pituitary adenomas usually show some evidence of sella turcica enlargement and more homogeneous enhancement than extraaxial cysticercotic cysts [14, 20]. Hydatid disease, not reported in this region, produces either a single, low density, intraaxial structure much larger than a cysticercotic cyst or small, clustered grapelike lesions (P. E. S. Palmer, personal communication) [25, 26]. However, the diagnosis of parasitic disease should be considered in an individual from an area in which cysticercosis is endemic whenever a homogeneous low density lesion is detected, particularly in or about ventricular or cisternal structures.

REFERENCES

- Shaw MC, Alvord Jr EC. Cava septi pellucidi et vergae: their normal and pathological states. *Brain* 1969;92:213-223
- Wilson CB, Howieson J. Cysts of the septum pellucidum. *Neurochirurgia* 1970;13:93-99
- Deck MD. The lateral ventricles. In: Newton TH, Potts DG, eds. *Radiology of the skull and brain: ventricles and cisterns*, vol 4. St. Louis: Mosby, 1978:3533-3535
- Gubbay SS, Vaughan R, Lekias JS. Intermittent hydrocephalus due to cysts of the septum pellucidum: a study of three cases. *Proc Aust Assoc Neurol* 1977;14:93-99
- Dandy WE. Congenital cerebral cysts of the cavum septi pellucidi (fifth ventricle) diagnosis and treatment. *Arch Neurol Psychiatr* 1931;25:44-66
- Ciric I, Zivin I. Neuroepithelial (colloid) cysts of the septum pellucidum. *J Neurosurg* 1975;43:69-73
- Van Wagenen WP, Aird RV. Dilatations of the cavity of the septum pellucidum and cavum vergae: report of cases. *Am J Cancer* 1934;20:539-557
- Schunk H. Congenital dilatations of the septum pellucidum. *Radiology* 1963;81:610-618
- Obrador S. Clinical aspects of cerebral cysticercosis. *Arch Neurol Psychiatr* 1948;59:457-468
- Stepien L, Chorobski J. Cysticercosis cerebri and its operative treatment. *Arch Neurol Psychiatr* 1949;61:499-527
- Dixon HBF, Lipscomb M. Cysticercosis: an analysis and follow-up of 450 cases. *Privy Council Medical Research Council Special Report Series*, no. 299. London: 1961:1-58
- Schultz TS, Ascherl GF Jr. Cerebral cysticercosis: occurrence in the immigrant population. *Neurosurgery* 1978;3:164-169
- Dublin WB. *Fundamentals of neuropathology*, 2d ed. Springfield, Ill.: Thomas, 1967:140-141
- Carbajal JR, Palacios E, Azar-Kia B, Churchill R. Radiology of cysticercosis of the central nervous system including computed tomography. *Radiology* 1977;125:127-131
- Bentson JR, Wilson GH, Helmer E, Winter J. Computed tomography in intracranial cysticercosis. *J Comput Assist Tomogr* 1977;1:464-471
- Newton TH, Norman D, Alvord EC, Shaw C. The CT scan in infectious disease of the CNS. In: Norman D, Korbkin M, Newton TH, eds. *Computed tomography*. Berkeley: University of California, 1977:323-324
- Scheithaer BW. Symptomatic subependymoma. *J Neurosurg* 1978;49:689-696
- Clark RM, Adams JC. Subependymal astrocytoma of the septum pellucidum: case report and brief review. *J SC Med Assoc* 1978;74:265-267
- Steinhoff H, Lanksch W, Kazner E, et al. Computed tomography in the diagnosis and differential diagnosis of glioblastomas. *Neuroradiology* 1977;14:193-200
- Citrin CM, Davis DO. Computerized tomography in the evaluation of pituitary adenomas. *Invest Radiol* 1977;12:27-35
- Fitz CR, Wortzman G, Harwood-Nash DC, Holgate RC, Barry JF, Boldt DW. Computed tomography in craniopharyngiomas. *Radiology* 1978;127:687-691
- Fawcett RA, Isherwood I. Radiodiagnosis of intracranial pearly tumors with particular reference to the value of computer tomography. *Neuroradiology* 1976;11:235-242
- Byrd SE, Harwood-Nash DC, Fitz CR. Absence of the corpus callosum: computed tomographic evaluation in infants and children. *J Can Assoc Radiol* 1978;29:108-112
- Guner M, Shaw MDM, Turner JW, Steven JL. Computed tomography in the diagnosis of colloid cyst. *Surg Neurol* 1978;6:345-348
- Abbassioun K, Rahmat H, Ameli N, Tafazoli M. Computerized tomography in hydatid cyst of the brain. *J Neurosurg* 1978;49:408-411
- Özgen T, Erbenli A, Bertan V, Sağlam S, Gürcay Ö, Pirnar T. The use of computerized tomography in the diagnosis of cerebral hydatid cysts. *J Neurosurg* 1979;50:339-342