AJNR

MR and CT of Masses of the Anterosuperior Third Ventricle

Gerard A. Waggenspack and Faustino C. Guinto, Jr.

AJNR Am J Neuroradiol 1989, 10 (1) 105-110
http://www.ajnr.org/content/10/1/105

This information is current as of October 11, 2024.

MR and CT of Masses of the Anterosuperior Third Ventricle

Gerard A. Waggenspack[1]
Faustino C. Guinto, Jr.

Six patients with masses of the anterosuperior portion of the third ventricle were imaged with MR and CT. Four patients had proved colloid cysts, one patient had a proved astrocytoma, and one patient had a presumed colloid cyst.

Multiplanar MR imaging provided accurate localization of the anterosuperior third-ventricle mass in all cases. The MR intensity characteristics of the colloid cysts varied and the astrocytoma could not be differentiated from the colloid cysts on MR. The astrocytoma contained a calcification that was clearly demonstrated on CT but was difficult to appreciate on MR. Neither MR nor CT was useful in predicting success of stereotactic aspiration of the colloid cysts in this small series, but the presence of thin, low-viscosity cyst contents could be suggested by both examinations.

Colloid cysts, meningiomas, choroid plexus papillomas, hamartomas, gliomas, vascular lesions, and granulomatous lesions are among the masses that may arise in the anterosuperior third ventricle (ASTV). A patient becomes symptomatic when the mass obstructs the flow of CSF at the foramina of Monro. Symptoms include headaches, vomiting, and mental and visual disturbances. Rarely, acute neurologic deterioration or sudden death may occur [1–3].

CT has proved useful for the diagnosis of masses of the ASTV [4–11]. More recently, MR imaging has added a new dimension to the characterization of masses of the ASTV [12–14]. A retrospective study was done to address two questions: (1) Can MR distinguish colloid cysts from other masses of the ASTV? (2) Can the MR appearance of a mass of the ASTV be used to predict whether or not stereotactic aspiration will be successful?

Materials and Methods

Six patients, three men and three women, ages 28 to 59, with a mass of the ASTV were examined with both MR and CT between April 1985 and November 1987. MR and CT studies were performed before any operative procedure except in one patient in whom MR was obtained after placement of an emergency ventriculoperitoneal shunt.

In three patients, CT-guided stereotactic aspiration of a mass of the ASTV yielded fluid consistent with a diagnosis of colloid cyst. Fragments of cyst wall were recovered in one of these three patients. In two patients, the mass was surgically resected and proved to be a colloid cyst in one case and an astrocytoma in the other. Tissue was not available in the sixth patient, but, on the basis of the CT appearance, it was presumed to be a colloid cyst.

MR was performed with a 0.6-T Technicare system in five patients and with a 1.5-T GE Signa system in one patient. With the 0.6-T system, spin-echo images, 500/32/4 (TR/TE/excitations) and 2000/60, 120/2, were acquired in each case. Section thickness was 8 mm, with a 256 × 128 acquisition matrix, and a 25.6-cm field of view. With the 1.5-T system, spin-echo images, 600/20/2 and 2000/20, 70/2, were acquired. Section thickness was 5 mm, with a 256 × 128 acquisition matrix, and a 24-cm field of view. Hereafter, images with TR = 500 or 600 will be referred to as short TR, images with TR = 2000 and TE = 20 as spin-density, and images with TR = 2000 and TE = 60,70, or 120 as long TR/long TE. Each patient was imaged in the axial and the coronal and/or sagittal planes.

This article appears in the January/February 1989 issue of *AJNR* and the March 1989 issue of *AJR*.

Received February 17, 1988; accepted after revision May 25, 1988.

[1] Both authors: Department of Radiology, Division of Neuroradiology, University of Texas Medical Branch, Galveston, TX 77550-G09. Address reprint requests to G. A. Waggenspack.

***AJNR* 10:105–110, January/February 1989**
0195–6108/89/1001–0105
© American Society of Neuroradiology

CT examinations were performed on a GE 8800 scanner. Studies were obtained both without and with IV iodinated contrast (56 g I) in five cases and only without contrast in one case.

Case Reports

Case 1

A 59-year-old comatose woman had a noncontrast CT scan that showed a poorly defined hypodense mass in the ASTV and hydrocephalus of the lateral ventricles. The mass did not enhance after administration of IV contrast material. The patient underwent emergency ventriculoperitoneal shunting. A repeat noncontrast CT scan showed a well defined hypodense mass in the ASTV (Fig. 1A). MR showed a homogeneous mass that was lower in intensity than gray matter on short TR, isointense with gray matter on spin-density, and hyperintense on long TR/long TE (Figs. 1B–1D). CT-guided stereotactic aspiration of the mass yielded thin fluid that contained amorphous debris and inflammatory cells, consistent with a diagnosis of colloid cyst. Epithelial cells were not recovered. On CT the mass measured 1.7 cm in diameter prior to aspiration and 0.8 cm in diameter after aspiration.

Case 2

A 28-year-old man with constant headaches of varying severity and blurred vision had a physical examination that revealed bilateral papilledema. MR showed a mass with intensity similar to white matter on short TR (Fig. 2A). On long TR/long TE, the mass had a hyperintense periphery with a markedly hypointense internal focus (Figs. 2B and 2C). A noncontrast CT scan showed a homogeneous hyperdense mass in the ASTV (Fig. 2D). CT-guided stereotactic aspiration yielded gelatinous material consistent with a diagnosis of colloid cyst. No epithelium was identified. The cyst measured 1.4 cm in diameter prior to aspiration and could not be identified on CT images after aspiration.

Case 3

A 43-year-old woman presented with a 2-month history of intermittent headaches and memory loss. She also reported two syncopal episodes, one 3 weeks prior to admission and one 1 day before admission. Blurred optic disks were seen on funduscopic examination. A noncontrast CT scan showed hydrocephalus and a slightly hyperdense mass in the ASTV (Fig. 3A). The mass enhanced 10 H after administration of IV contrast material. MR showed a homoge-

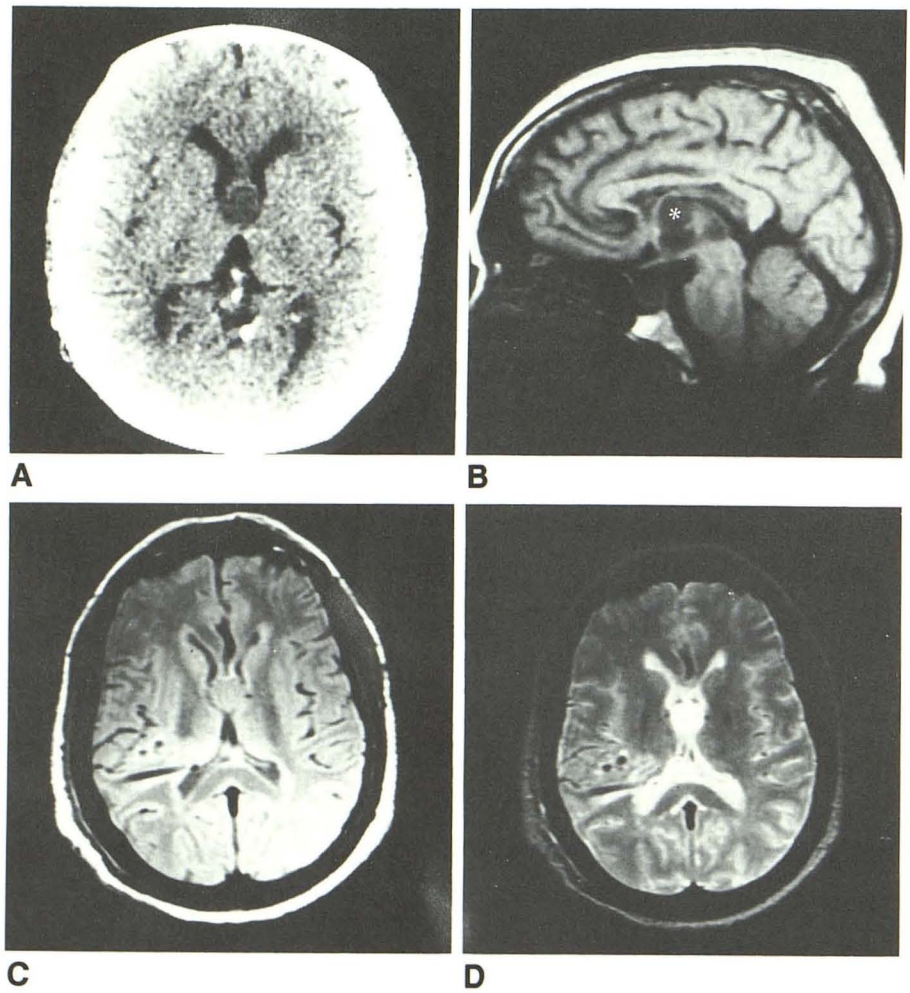

Fig. 1.—Case 1: Colloid cyst.

***A*, Noncontrast CT scan shows hypodense mass in anterosuperior third ventricle.**

***B*, Midline sagittal spin-echo MR image (600/20). Homogeneous mass, lower in intensity than gray matter, is seen in anterosuperior third ventricle (*asterisk*). Fornix is bowed anteriorly and superiorly.**

***C*, Axial spin-echo MR image (2000/20). Mass is higher in intensity than in *B*, but easily separable from lower-intensity CSF in lateral ventricles.**

***D*, Axial spin-echo MR image (2000/70). Mass shows very high signal intensity but is more difficult to distinguish from adjacent high-signal-intensity CSF.**

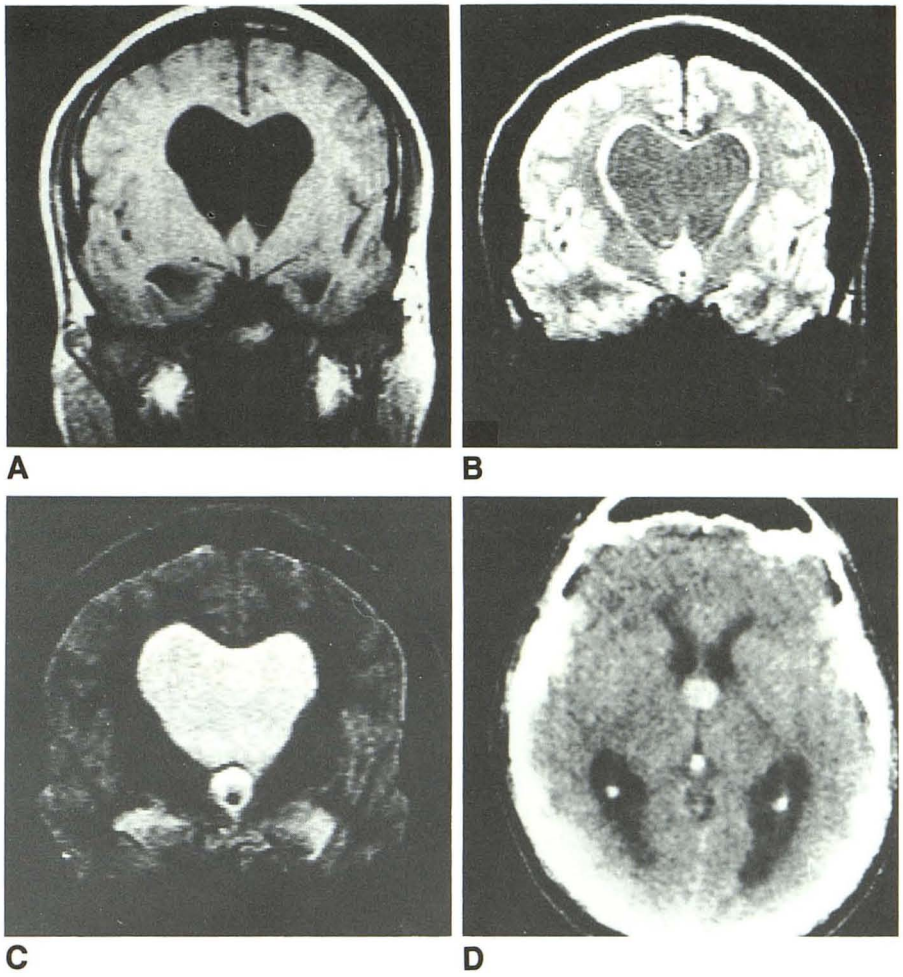

Fig. 2.—Case 2: Colloid cyst.
A, Coronal spin-echo MR image (500/32). Homogeneous mass with intensity similar to white matter is shown in anterosuperior third ventricle. Lateral ventricles are dilated.
B, Coronal spin-echo MR image (2000/60). Mass has small internal area of hypointensity and peripheral hyperintensity.
C, Coronal spin-echo MR image (2000/120). Intensity of mass is now similar to intensity of CSF in lateral ventricles. Hypointensity is more pronounced.
D, Noncontrast CT scan shows hyperdense mass in anterosuperior third ventricle. CT was obtained 4 days after the MR. No surgical procedure was done during the interim. Lateral ventricles are decompressed, indicating intermittent nature of the obstruction of the foramina of Monro.

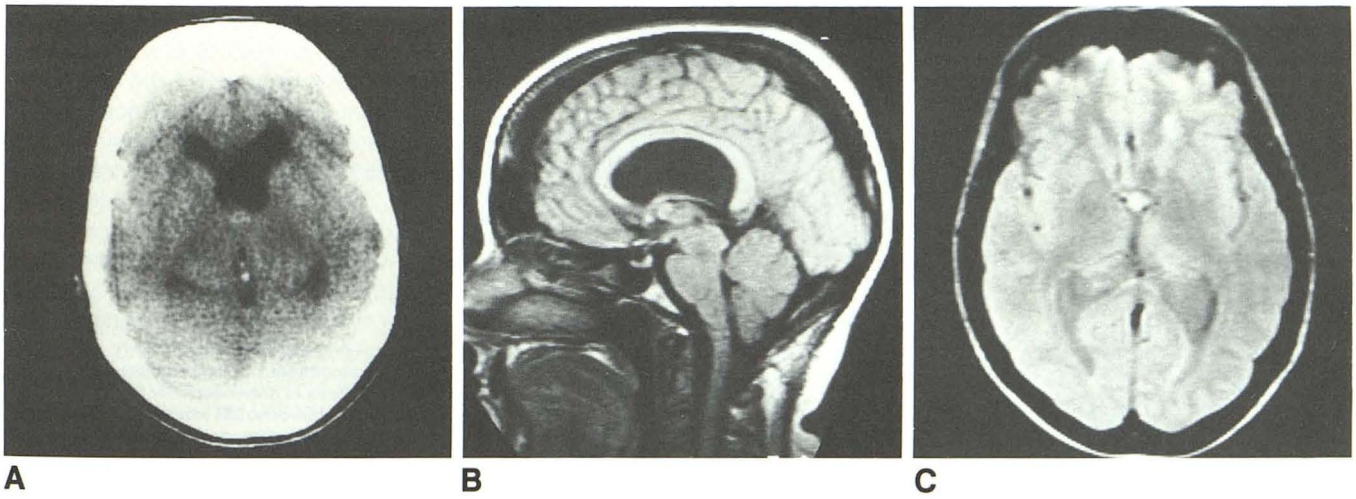

Fig. 3.—Case 3: Colloid cyst.
A, Noncontrast CT scan shows slightly hyperdense mass in anterosuperior third ventricle.
B, Sagittal spin-echo MR image (500/38). Homogeneous mass isointense with gray matter is seen in anterosuperior third ventricle.
C, Axial spin-echo MR image (2000/60). Mass appears homogeneously hyperintense without an internal low-intensity focus.

neous mass that was isointense with gray matter on short TR (Fig. 3B) and hyperintense relative to gray matter on long TR/long TE (Fig. 3C). Surgical resection of the mass revealed a thin-walled colloid cyst of the ASTV.

Case 4

A 31-year-old man presented with an 18-month history of bifrontal headaches. The weekend prior to admission the headaches became worse. Physical examination was normal. The CT and MR findings were similar to those described in case 3. CT-guided stereotactic aspiration yielded mucoid material and fragments of columnar epithelium consistent with a diagnosis of colloid cyst. On CT the mass measured 1.7 cm before aspiration and 1.2 cm after aspiration.

Case 5

A 54-year-old man presented with a 2-year history of headaches, poor memory, and occasional blurred vision. Funduscopic examination and visual fields were normal. A noncontrast CT scan showed a 0.7-cm diameter homogeneous hyperdense mass in the ASTV, without hydrocephalus. No enhancement was seen after administration of IV contrast material. MR showed a mass that was lower in intensity than gray matter on short TR images and markedly hypointense on long TR/long TE images. No operative procedure was performed in this case. On the basis of the CT appearance, this mass was presumed to be a colloid cyst.

Case 6

A 32-year-old woman presented with a 1-month history of headaches, syncopal episodes, and seizures. Funduscopic and visual field examinations were normal. A noncontrast CT scan showed a 1.4-cm diameter mass, isodense with brain, in the ASTV. A calcification was seen in the mass (Fig. 4A). There was slight enhancement of the mass after IV contrast administration. Short TR MR images showed a homogeneous mass isointense with white matter (Fig. 4B). On long TR/long TE sequences the mass was largely homogeneous and hyperintense relative to gray matter (Figs. 4C and 4D). The calcification was difficult to appreciate on MR. An arteriogram showed no evidence of tumor vascularity. A CT-guided stereotactic aspiration of the mass yielded solid tissue. The histologic diagnosis was astrocytoma. Subsequent open surgical resection of the mass revealed a low-grade astrocytoma inside the posterior margin of the septum pellucidum.

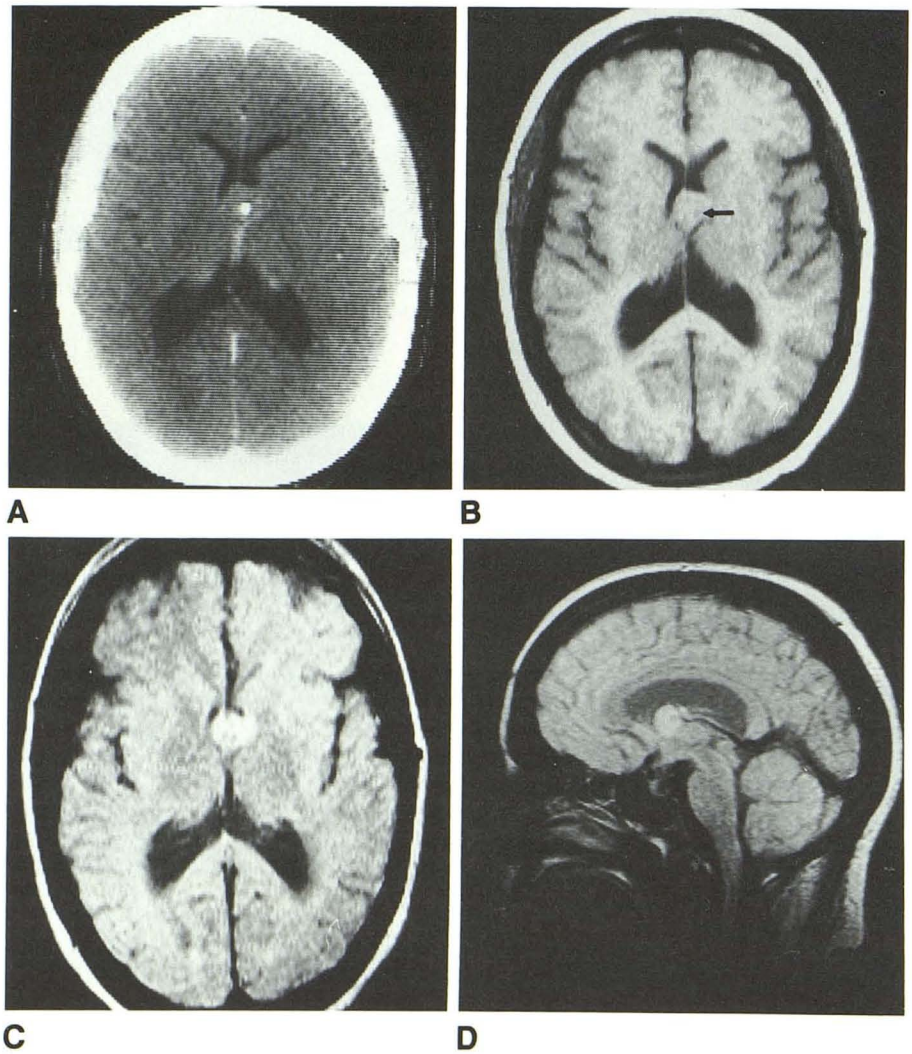

Fig. 4.—Case 6: Astrocytoma.

***A*, Noncontrast CT scan shows calcification within a mass in anterosuperior third ventricle.**

***B*, Axial spin-echo MR image (500/32). A mass isointense with white matter is seen. An area of slightly decreased signal (*arrow*), which corresponds to the calcification shown on CT, is seen posteriorly in the mass.**

***C* and *D*, Axial (*C*) and sagittal (*D*) spin-echo MR images (2000/60). Mass is almost homogeneously hyperintense except for a small area of decreased signal posteriorly.**

Discussion

The goal of therapy in the treatment of masses of the ASTV is to relieve the obstruction of the foramina of Monro. Open surgical resection of the mass may be performed with almost no risk of mortality [15]. However, significant morbidity may result because of injury to structures exposed in approaching the third ventricle. Memory disorders, convulsions, hemiplegia, impairment of consciousness, and visual field loss are among the deficits that may result [16]. Stereotactic aspiration may be performed if the mass is a colloid cyst. Excellent results with essentially no morbidity or mortality have been reported [5, 9, 10]. To date, most stereotactic aspirations have been performed by using CT guidance; however, guidance devices for use with MR imaging systems are currently under development [17].

Colloid cysts originate from folding of the primitive neuroepithelium, which gives rise to the choroid plexus and ependyma [18]. Shuangshoti et al. [18] have shown that the contents of the cysts are secretory and breakdown products of the epithelial lining of the cyst, including old blood, foamy cells, fat, hemosiderin-laden macrophages, cholesterol crystals, and CSF. Ions within the mucin of one third-ventricle colloid cyst included sodium, magnesium, calcium, copper, silicon, iron, and phosphorous [19]. Variations in the amount and distribution of these secretory and breakdown products and ions in colloid cysts would account for their varied appearances on CT and MR.

On CT, colloid cysts are usually hyperdense before IV contrast administration and often show mild enhancement after contrast is given, but the cyst may occasionally be isodense or hypodense [6–8, 13]. Dense contrast enhancement suggests a diagnosis other than colloid cyst, such as meningioma, choroid plexus papilloma, or craniopharyngioma. When MR contrast agents become more widely available the CT enhancement characteristics of masses of the ASTV will assume a less important role.

CT evidence of calcification in a colloid cyst is uncommon, with Ganti et al. [6] reporting calcification in one of 14 cases and Brooks and El Gammal [4] in one of six cases. CT is superior to MR for demonstration of intracranial calcifications [20]. In case 6, CT showed an unequivocal calcification in the astrocytoma; MR did not. There were no other MR, CT, or angiographic features to distinguish the astrocytoma from the colloid cyst.

On short TR MR images, the colloid cysts we studied were homogeneous and equal to or lower than white matter in intensity. This differs from the central hypointensity, peripheral hyperintensity reported by Roosen et al. [13] and Scotti et al. [14]. On long TR/long TE, one cyst in our study (case 2) showed internal hypointensity and peripheral hyperintensity, three others became uniformly hyperintense, and one appeared uniformly hypointense. The hypointense areas are due to structures with a short T2 relaxation time. A high concentration of paramagnetic ions causing a magnetic susceptibility effect could account for the low signal [14]. The high-signal-intensity areas of the cysts on the spin-density and long TR/long TE images are largely the result of the short T1 relaxation time of the cysts' contents [12]. If the T1 relaxation time is very short, medium or high signal intensity may also be seen on the short TR images.

The wall of a colloid cyst consists of connective tissue containing sparse neutrophils, lymphocytes, plasma cells, and macrophages [18]. We were unable to identify the walls of the colloid cysts on the MR or CT images. The curving cyst walls may have been too thin to be resolved because of partial volume averaging.

We found the MR and CT appearance of the colloid cysts useful in predicting the presence of thin fluid, but this did not ensure complete aspiration of the contents of the cysts. Rivas and Lobato [10] found that low-density colloid cysts on CT images indicated the contents would be easier to aspirate than if the cysts were hyperdense, because the hyperdense cysts contained thicker colloid material than the hypodense or isodense cysts. Hall and Lunsford [7] did not find the CT appearance of colloid cysts helpful in predicting success of aspiration. The cyst in our case 1 contained thin fluid that was hypodense on CT. This cyst was slightly hypointense on the short TR MR image and uniformly hyperintense on spin-density and long TR/long TE sequences. This signal intensity behavior suggests the presence of relatively simple fluid containing little substance with minimal shortening of the T1 relaxation time of the fluid. The cysts with more viscous contents (cases 2, 3, and 4) were medium in intensity on the short TR images and hyperdense on CT. However, the cyst with thin fluid in case 1 was not as completely aspirated as one of the cysts with viscous contents (case 2). This was probably because, in addition to viscosity, success of aspiration can be influenced by position of the needle in the cyst and displacement of the cyst wall away from the aspiration needle.

Hydrocephalus of the lateral ventricles is usually seen with symptomatic masses of the ASTV [6–8]. CT may occasionally fail to show a mass of the ASTV in the presence of hydrocephalus [8, 21], but MR can show the mass when CT has not [21].

In summary, MR can localize accurately masses of the ASTV. Colloid cysts have varied appearances on MR images, reflecting differences in the contents of the cysts, and they cannot be reliably distinguished from other masses of the ASTV. Success of stereotactic aspiration of colloid cysts could not be predicted by either MR or CT.

REFERENCES

1. Chan RC, Thompson GB. Third ventricular colloid cysts presenting with acute neurological deterioration. *Surg Neurol* **1983**;19:358–362
2. Leestma JE, Konakci Y. Sudden unexpected death caused by neuroepithelial (colloid) cyst of the third ventricle. *J Forensic Sci* **1981**;26:486–491
3. McDonald JA. Colloid cyst of the third ventricle and sudden death. *Ann Emerg Med* **1982**;11:365–367
4. Brooks BS, El Gammal T. Lesions at the foramen of Monro: evaluation by computed tomography, angiography and pneumoencephalography. *South Med J* **1983**;76:1515–1523
5. Donauer E, Moringlane JR, Ostertag CB. Colloid cysts of the third ventricle. Open operative approach or stereotactic aspiration? *Acta Neurochir* (Wien) **1986**;83:24–30
6. Ganti SR, Antunes JL, Louis KM, Hilal SK. Computed tomography in the diagnosis of colloid cysts of the third ventricle. *Radiology* **1981**;138:385–391
7. Hall WA, Lunsford LD. Changing concepts in the treatment of colloid cysts.

An 11-year experience in the CT era. *J Neurosurg* **1987**;66:186–191
8. Michels LG, Rutz D. Colloid cysts of the third ventricle. A radiologic-pathologic correlation. *Arch Neurol* **1982**;39:640–643
9. Mohadjer M, Teshmar E, Mundinger F. CT-stereotaxic drainage of colloid cysts in the foramen of Monro and the third ventricle. *J Neurosurg* **1981**;67:220–223
10. Rivas JJ, Lobato RD. CT-assisted stereotaxic aspiration of colloid cysts of the third ventricle. *J Neurosurg* **1985**;62:238–242
11. Sackett JF, Messina AV, Petito CK. Computed tomography and magnification vertebral angiotomography in the diagnosis of colloid cysts of the third ventricle. *Radiology* **1975**;116:95–100
12. Kjos BO, Brant-Zawadzki M, Kucharczyk W, Kelly WM, Norman D, Newton TH. Cystic intracranial lesions: magnetic resonance imaging. *Radiology* **1985**;155:363–369
13. Roosen N, Gahlen D, Stork W, et al. Magnetic resonance imaging of colloid cysts of the third ventricle. *Neuroradiology* **1987**;29:10–14
14. Scotti G, Scialfa G, Colombo N, Landoni L. MR in the diagnosis of colloid cysts of the third ventricle. *AJNR* **1987**;8:370–372
15. Nitta M, Symon L. Colloid cysts of the third ventricle. A review of 36 cases. *Acta Neurochir* (Wien) **1985**;76:99–105
16. Yamamoto I, Rhoton AL Jr, Peace DA. Microsurgery of the third ventricle: part 1. Microsurgical anatomy. *Neurosurgery* **1981**;8:334–356
17. Thomas DGT, Davis CH, Ingram S, Olney JS, Bydder GM, Young IR. Stereotaxic biopsy of the brain under MR imaging control. *AJNR* **1986**;7:161–163
18. Shaungshoti S, Roberts MP, Netsky MG. Neuroepithelial (colloid) cysts. Pathogenesis and relation to choroid plexus and ependyma. *Arch Pathol Lab Med* **1965**;80:214–224
19. Donaldson JO, Simon RH. Radiodense ions within a third ventricular colloid cyst. *Arch Neurol* **1980**;37:246
20. Oot RF, New PFJ, Pile-Spellman J, Rosen BR, Shoukimas GM, Davis KR. The detection of intracranial calcifications by MR. *AJNR* **1986**;7:801–809
21. El Gammal T, Allen MB Jr, Brooks BS, Mark EK. MR evaluation of hydrocephalus. *AJNR* **1987**;8:591–597