

Are your **MRI contrast agents** cost-effective?

Learn more about generic **Gadolinium-Based Contrast Agents**.



FRESENIUS
KABI

caring for life

AJNR

Spontaneous resolution of arteriovenous malformation without hemorrhage.

P Megison, H H Batjer, P D Purdy and D S Samson

AJNR Am J Neuroradiol 1989, 10 (1) 204

<http://www.ajnr.org/content/10/1/204.citation>

This information is current as
of April 19, 2024.

Spontaneous Resolution of Arteriovenous Malformation Without Hemorrhage

Hook and Johansen [1] reported the first case of spontaneous resolution of an angiographically followed arteriovenous malformation (AVM). Since then other cases of partial or complete resolution have been reported [2–9].

Case Report

The patient was a 25-year-old, right-handed man who had been hyperactive and nervous as a child. A grand mal seizure disorder had developed when he was 15. A brain scan and CT scan at that time showed a small, calcified, left posterior temporal lesion. The patient was told that it was inoperable because of its location, and anticonvulsants were prescribed. In May 1984, poor seizure control led to repeat CT and angiography (Figs. 1A and 1B), which showed a small, calcified, left posterior temporal AVM with a diameter of 1.5 to 2.0 cm that was fed by the left posterior temporal branch of the middle cerebral artery. Again he was told that the lesion was inoperable. After 2 years of continued seizures, the patient was referred to our institution. He had had no previous episodes of headache, nausea, vomiting, or meningismus associated with his seizures. Repeat angiography (Fig. 1C) showed no evidence of arteriovenous malformation, early draining, or other abnormal vascular changes. Dense calcification was noted in the left temporal area on plain skull films, and this was even more obvious on CT scans (Fig. 1D).

Discussion

Few cases of complete, spontaneous regression of angiographically proved AVMs have been reported [1–7, 9]. Only two cases without previous intracerebral hemorrhage have been described [3, 7]. One patient was a 4-year-old child with intractable seizures. CT and angiography revealed an avascular, minimally enhancing mass, and at surgery a thrombosed AVM was found. The second patient had an associated glioma within the AVM. Seizures in these cases could represent numerous small hemorrhages, but no definite evidence was cited for clinical subarachnoid hemorrhage. Our case represents angiographically and CT-documented resolution of an AVM with dense calcification and no previous evidence of hemorrhage.

It has been speculated that spontaneous resolution of AVMs could be caused by thrombosis associated with hemorrhage; decreased flow associated with elongation of abnormal vessels, turbulence, or emboli; or intrinsic changes in the vessel wall leading to hypercoagulability [1, 4, 7, 8]. Omojola et al. [7] pointed out that moderate to large AVMs with a single arterial feeder and solitary venous drainage were the most common in the previously reported cases.

The malformation in our case was fed by a single middle cerebral artery branch and drained into the vein of Labbé.

The natural history of AVMs studied via serial angiography has been reported by three separate groups [1, 4, 10]. Fifty-one percent of the malformations enlarged, 37% remained unchanged, 6% became smaller, and 6% spontaneously disappeared after 4–7 years. Of the three patients whose AVMs resolved, two had numerous hemorrhages, and one was also treated with radiation therapy [1, 4]. The literature suggests that occasionally AVMs do regress spontaneously, but not without significant morbidity from repeated hemorrhages. Despite the rarity of spontaneous resolution, it is probably unwise to subject patients with long-standing diagnoses of AVM to surgical procedures without current radiographic studies confirming persistent patency.

Phillip Megison
H. Hunt Batjer
Phillip D. Parry
Duke S. Samson
University of Texas Health Science Center at Dallas
Dallas, TX 75235

REFERENCES

1. Hook O, Johansen C. Intracranial arteriovenous aneurysms: a followup study with particular attention to their growth. *Arch Neurol Psychiatry* 1958;80:39–54
2. Couforti P. Spontaneous disappearance of cerebral arteriovenous angioma. *J Neurosurg* 1971;34:432–434
3. Dyck P. Spontaneous thrombosis of an arteriovenous malformation. *Neurosurgery* 1977;1:287–290
4. Kuwahara S, Shima T, Ishikawa S. A clinical study of AVMs with reference of their enlargement or regression: a follow-up study with angiography and CT scan. *Neurol Med Chir (Tokyo)* 1979;19:149–161
5. Levine J, Misko JC, Sere JL, Snodgrass RG. Spontaneous angiographic disappearance of a cerebral arteriovenous malformation. *Arch Neurol* 1973;28:195–196
6. Nukui H, Miyagi O, Mitsuka S. Long term follow-up study by cerebral angiography in cases with arteriovenous malformation of the brain. *Neurol Med Chir (Tokyo)* 1982;22:125–132
7. Omojola ME, Fox AJ, Vinuela FV, Drake CG. Spontaneous regression of intracranial arteriovenous malformations. *J Neurosurg* 1982;57:818–822
8. Patterson JH, McKissock W. A clinical survey of intracranial angioma with special reference to their mode of progression and surgical treatment. *Brain* 1956;79:233–266
9. Sartor K. Spontaneous closure of cerebral arteriovenous malformation demonstrated by angiography and computed tomography. *Neuroradiology* 1978;15:95–98
10. Wilson CB, Stein BM. *Intracranial arteriovenous malformations*. Baltimore: Williams & Wilkins, 1984:12–23

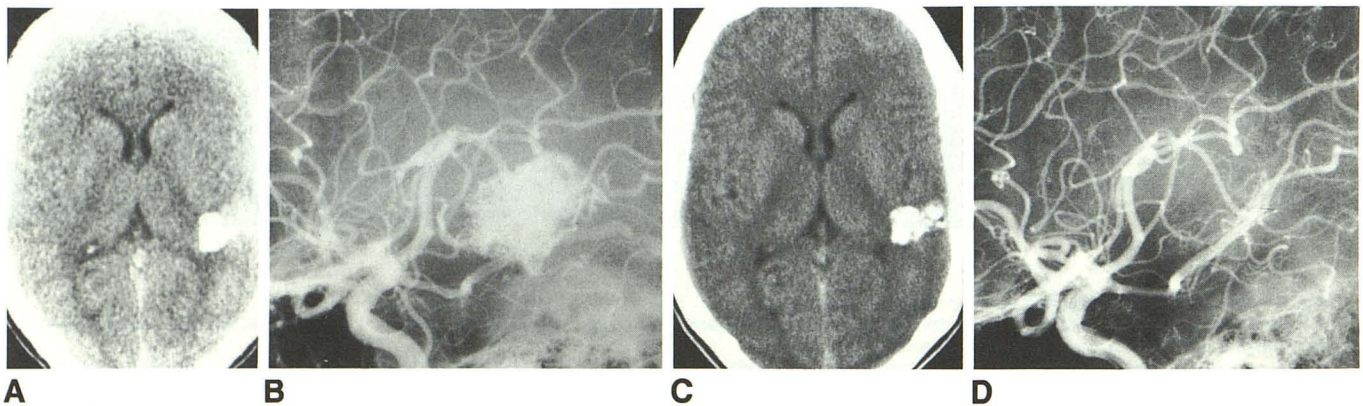


Fig. 1.—A–D, Radiologic evaluation in May 1984 (A and B) and August 1986 (C and D) of a man with an arteriovenous malformation (AVM). A, Unenhanced CT scan shows calcific, enhancing posterior temporal lesion, which showed minimal enhancement after injection of contrast medium. B, Lateral projection of left carotid angiogram shows AVM irrigated by posterior temporal branch of middle cerebral artery and draining into vein of Labbé. C, Unenhanced CT scan shows that left posterior temporal lesion is densely calcified. No enhancement was seen after injection of contrast medium. D, Lateral projection of left carotid angiogram shows resolution of AVM.