

Generic Contrast Agents

Our portfolio is growing to serve you better. Now you have a *choice*.



FRESENIUS
KABI

[VIEW CATALOG](#)

AJNR

CT and MR of Germinoma in the Basal Ganglia

Yoji Komatsu, Kiyoshi Narushima, Eiki Kobayashi, Reiko Ebihara, Takao Enomoto, Tadao Nose and Yutaka Maki

AJNR Am J Neuroradiol 1989, 10 (5 suppl) S9-S11
http://www.ajnr.org/content/10/5_suppl/S9.citation

This information is current as
of May 11, 2025.

CT and MR of Germinoma in the Basal Ganglia

Yoji Komatsu,^{1,3} Kiyoshi Narushima,¹ Eiki Kobayashi,¹ Reiko Ebihara,² Takao Enomoto,³ Tadao Nose,³ and Yutaka Maki³

Primary intracranial germinomas constitute about 1% of primary intracranial neoplasms [1]. They occur commonly in the pineal and suprasellar regions in childhood, and they usually present with symptoms related to increased intracranial pressure or hypothalamic dysfunction [2–5]. They rarely develop in the basal ganglia, and only 16 cases have been reported with CT findings [6–13]. In some reports, CT findings were characterized by the presence of cerebral atrophy [7, 9, 11, 14, 15]. All of the previous cases were diagnosed after dementia or hemiparesis developed. Because the germinoma is radiosensitive and potentially curable, early diagnosis is important [16–22]. We present two cases with their radiologic features, especially CT and MR features, and review the radiologic findings of the previously reported cases.

Case Reports

Case 1

An 8-year-old boy came to our hospital with complaints of dementia and left hemiparesis. He had been a full-term baby and developed normally until his parents found mild left hemiparesis when he was 5 years old. The hemiparesis increased and dementia appeared. Initially, a brain CT scan at a hospital showed no abnormality, and the physician diagnosed cerebral palsy (Fig. 1A). His condition, however, deteriorated progressively. When he was 7 years old, a second CT scan was performed at another hospital; the pineal body was now calcified. A third CT, 1 year later, showed asymmetric anterior horns of the lateral ventricles and slightly increased density in right basal ganglia (Fig. 1B).

He was referred to our hospital for further examinations and treatment. Dementia (intelligence quotient was less than 40%; his intelligence was the same as a 2-year-old) and left hemiparesis with rigidity were observed. Serum human chorionic gonadotropin (HCG) level was increased. CT scans revealed a high-density mass with small low-density points in the basal ganglia bilaterally (left side dominant) and cortical atrophy (Figs. 1C and 1D). MR imaging with a spin-echo sequence (1800/70/4 [TR/TE/excitations]) showed the mass as a high-intensity lesion. Heterogeneous low intensity was seen with an inversion-recovery sequence (1400/420/30/4 [TR/IR/TE/excitations]) (Figs. 1E and 1F). Gd-DTPA enhanced the tumor

(Fig. 1G). A stereotactic biopsy was carried out. The pathologic diagnosis was two-cell-pattern germinoma (Fig. 1H), and 50 Gy of radiation therapy was performed. His dementia and hemiparesis slowly improved. Two years after the radiation therapy, neither CT nor MR showed any evidence of tumor.

Case 2

A 13-year-old boy was admitted to our hospital with complaints of dementia and involuntary movement. His birth and developmental history were normal. Myotonic involuntary movement occurred in his right hand when he was 11 years old. The involuntary movements increased, then dysarthria and dementia developed. The diagnosis was psychogenic reaction, and he came to our hospital to undergo further examinations. His serum HCG level was increased. CT showed a lesion of slightly high density in the left basal ganglia with asymmetry of anterior horns of lateral ventricles. Left hemispheric atrophy was also observed. The mass enhanced with IV contrast (Figs. 2A and 2B). MR imaging showed a mass of slightly high intensity with the spin-echo sequence (1800/70) and heterogeneous low intensity with the inversion-recovery sequence (1400/420/30) (Figs. 2C and 2D). He was pathologically diagnosed as having two-cell-pattern germinoma in the basal ganglia by stereotactic biopsy, and 50 Gy of radiation therapy was performed. There is no evidence of recurrence for 3 years, but his neurologic deficits remain unchanged.

Discussion

Germinomas do occur in the basal ganglia rarely. They are usually recognized after neurologic deficits develop. Although cerebral atrophy is said to be one of the important radiologic and pathologic features of basal ganglia germinoma, this atrophy is only a result of the tumor affecting the connecting fibers and not a direct sign of the tumor [7, 9, 11, 14, 15]. Because of the potential curability of the tumor and incomplete neurologic recovery of the patient with advanced germinoma in the basal ganglia, early detection and treatment of the tumor are desirable [16–22].

Germinomas are thought to arise from a midline streaming

Received July 21, 1988; revision requested September 8, 1988; revision received December 11, 1988; accepted December 28, 1988.

¹ Department of Neurosurgery, Tsukuba Memorial Hospital, Ibaraki 305, Japan.

² Department of Radiology, Tsukuba Memorial Hospital, Ibaraki 305, Japan.

³ Present address: Department of Neurosurgery, Institute of Clinical Medicine, University of Tsukuba, Tsukuba Science City, Ibaraki 305, Japan. Address reprint requests to Y. Komatsu at University of Tsukuba.

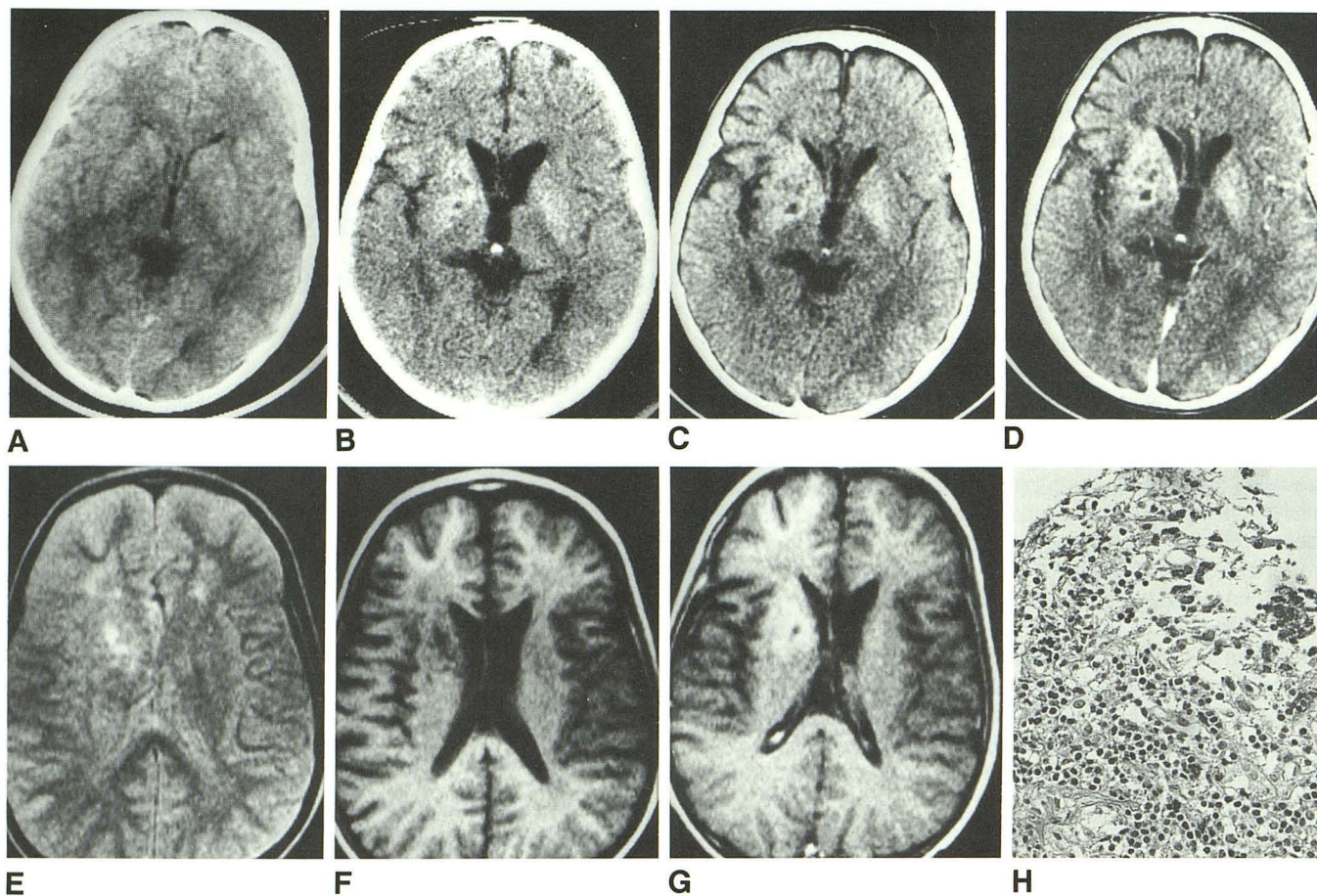


Fig. 1.—A, 6-year-old boy. Initial CT shows no abnormality.

B, The third CT, taken when the patient was 8 years old, shows high-density lesion in right basal ganglia and asymmetric anterior horns of lateral ventricles.

C, CT on admission to our hospital shows high-density mass in right basal ganglia and atrophy in right sylvian fissure area. Left basal ganglia also shows high density.

D, Mass enhances after IV injection of contrast material.

E, MR with spin-echo sequence (1800/70/4) shows the mass as a high-intensity lesion.

F, MR with inversion-recovery sequence (1400/420/30/4) shows a heterogeneous low intensity.

G, Mass enhances after IV injection of Gd-DTPA with inversion-recovery sequence.

H, Pathologic diagnosis is two-cell-pattern germinoma. (H and E, $\times 200$)

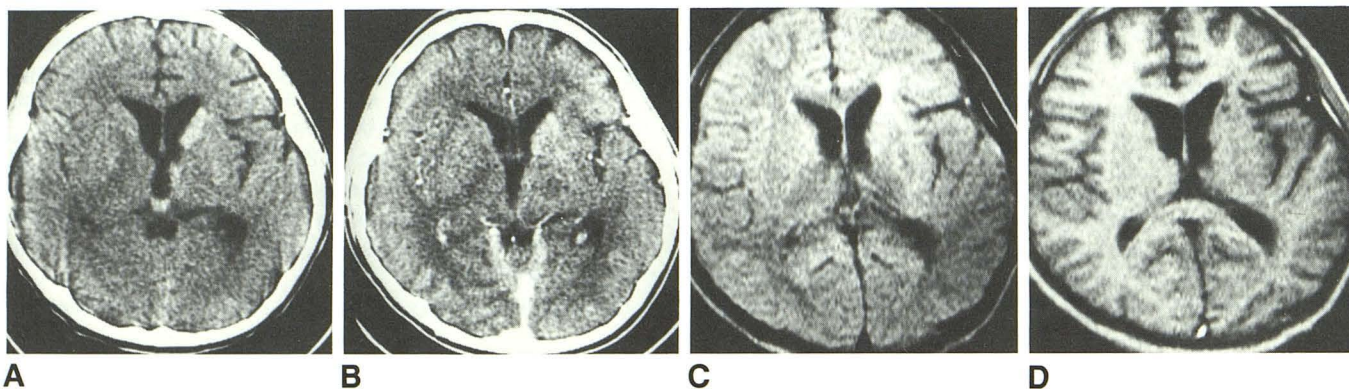


Fig. 2.—A, 13-year-old boy. CT shows high-density lesion in left basal ganglia with asymmetry of anterior horns of lateral ventricles.

B, Mass enhances.

C, MR with spin-echo sequence (1800/70) shows mass as lesion of slightly high intensity.

D, MR with inversion-recovery sequence (1400/420/30) shows only heterogeneous, low-intensity lesion with no mass effect and suggests atrophy in sylvian fissure area.

of totipotential cells very early in rostral neural tube development. This accounts for their pineal and suprasellar position. Third-ventricle development may cause deviation of ectopic germ cells from the midline and may cause their occurrence in the basal ganglia. In our first case, the neoplasm finally appeared bilaterally. We speculate that the tumor cells spread to the other side along the connecting fibers.

All 16 cases of basal ganglia germinoma reported with CT findings [6–13] have been Japanese. A high incidence of pineal tumors among Japanese is well documented, but the reason is unknown [23, 24]. The clinical courses of these cases have a common feature: all were diagnosed as having basal ganglia germinoma 1 or more years after the first symptoms appeared. When the diagnoses were made, characteristic CT findings were high-density masses in the basal ganglia and cerebral cortical atrophy. Symptoms of dementia or motor dysfunction continued despite radiotherapy.

The CT findings were retrospectively reviewed in only three reported cases. Yamada et al. [7] reported that the first sign was high density of the basal ganglia and that the mass effect and hemispheric atrophy appeared later. Kobayashi et al. [8] reported normal findings in the first CT examination, which was performed 2 years before the final diagnosis. Soejima et al. [13] reported that the first abnormal finding on CT was an area of slightly high density in the basal ganglia without mass effect. We reviewed retrospectively four CT scans over 4 years in our first case. The first CT scan was performed 1 year after the symptoms appeared and showed no abnormality. A mild sign of a mass (asymmetric anterior horns of the lateral ventricles) was seen in the third CT scan, which was taken in the third year after symptoms appeared. The tumor grew as a high-density mass, and cortical atrophy developed in the fourth year; then the brain tumor was detected. At this time, a postcontrast study showed tumor enhancement.

In the early stage, plain CT may not show any abnormality despite neurologic symptoms. The first sign in our case 1 was mild asymmetry of anterior horns of the lateral ventricles and an area of slightly high density in the basal ganglia. Next, the density of the mass became higher and cortical atrophy showed. We think that careful interpretation of CT scans can detect mild organic changes caused by the germinoma in the basal ganglia at an early stage.

MR imaging of basal ganglia germinoma has not been reported previously. MR findings in our two cases are identical. The tumor shows as heterogeneous low intensity with inversion-recovery sequence (T1-weighted image) and high intensity with spin-echo sequence (T2-weighted image). The mass enhances after Gd-DTPA administration. These findings are not specific for germinoma; however, they show neoplastic change in the basal ganglia, which later causes cortical atrophy. We cannot say exactly when MR would detect the tumor, but MR may have some advantage over CT in the early detection of the tumor.

Because germinomas usually occur in childhood, we prefer not to use contrast material for CT scanning. Thus, accuracy without the use of contrast material may be another advantage of using MR for early detection of basal ganglia germinoma.

Addendum

Since this manuscript was submitted, two new cases of basal ganglia germinoma have been described (Kobayashi T, Yoshida J, Kida Y. Bilateral germ cell tumors involving the basal ganglia and thalamus. *Neurosurgery* 1989;24:579–583).

REFERENCES

1. Aguila LA, Chou SM, Bay JW. Primary intracranial germinoma presenting as lower cranial nerve involvement: case report and review of the literature. *Neurosurgery* 1984;14:475–479
2. Takeuchi J, Handa H, Nagata I. Suprasellar germinoma. *J Neurosurg* 1978;49:41–48
3. Zimmerman RA, Bilaniuk LT, Wood JH, Bruce DA, Schut L. Computerized tomography of pineal, parapineal, and histologically related tumors. *Radiology* 1980;137:669–677
4. Joona R, Kendal BE. Diagnosis and management of pineal tumor. *J Neurosurg* 1983;58:654–665
5. Tanaka R, Takeda N, Ueki K, Itoh J, Honda H. Computerized tomography in the diagnosis and management of pineal region tumor. *Neurol Med Chir (Tokyo)* 1980;20:1103–1114
6. Ikeda Y, Higuchi H, Chin M, Shimura T, Nakazawa S. A case of thalamic germinoma with crossed aphasia in a dextral. *Neurol Surg* 1980;8:850–864 (in Japanese)
7. Yamada H, Imamura K, Sakai N, et al. Intracerebral germinoma developing in the right basal ganglia—report of a case followed up by CT scan and review of the literature. *Brain Nerve* 1980;32:387–392 (in Japanese)
8. Kobayashi T, Kageyama N, Kida Y, Yoshida J, Shibuya N, Okumura K. Unilateral germinomas involving the basal ganglia and thalamus. *J Neurosurg* 1981;55:55–62
9. Mabuchi S, Abe H, Nakagawa Y, Aida T, Tashiro K, Tsuru M. Germinoma originating in the basal ganglia—report of two cases. *Neurol Surg* 1982;10:977–982 (in Japanese)
10. Moriyama T, Teramoto S, Kitajima H, Yonekura M, Nakamura M, Matsumura H. Primary intracranial germ cell tumor in the right basal ganglia and its vicinity. *Neurol Surg* 1983;11:73–80 (in Japanese)
11. Mutoh K, Kim KM, Tomizawa T, Takao T, Okuno T, Yamashita J. A case of basal ganglia germinoma with characteristic CT findings. *No to Hattatsu* 1985;17:453–458 (in Japanese)
12. Nonaka T, Shimabukuro H, Oguro K, Sato F, Masuzawa N. Germ cell tumors originating in the basal ganglia and thalamus. *Neurol Med Chir (Tokyo)* 1987;27:1098–1103 (in Japanese)
13. Soejima T, Takeshita I, Yamamoto H, Tsukamoto Y, Fukui M, Matsuoka S. Computed tomography of germinomas in basal ganglia and thalamus. *Neuroradiology* 1987;29:366–370
14. Nakagawa Y, Hamazima I, Iwasaki Y, Yada K, Kunita H. Ipsilateral cerebral atrophy caused by ectopic pinealoma: report of a case. *No to Hattatsu* 1973;25:69–75 (in Japanese)
15. Kwak RC, Satoh S, Suzuki J. Ipsilateral cerebral atrophy with thalamic tumor of childhood. *J Neurosurg* 1978;48:443–449
16. Inoue Y, Takeuchi T, Tamaki M, Nin K, Hakuba A, Nishimura S. Sequential CT observations of irradiated intracranial germinomas. *AJR* 1979;132:361–365
17. Jenkin RDT, Simpson WJK, Keen CW. Pineal and suprasellar germinoma. *J Neurosurg* 1978;48:99–107
18. Sung D, Harisiadis L, Chang CH. Midline pineal tumors and suprasellar germinomas: highly curable by irradiation. *Radiology* 1978;128:745–751
19. Waga S, Handa H, Yamashita J. Intracranial germinomas: treatment and results. *Surg Neurol* 1979;11:167–172
20. Abay EO, Laws ER, Grado GL, et al. Pineal tumors in children and adolescents. *J Neurosurg* 1981;55:889–895
21. Rao YTR, Medini E, Haselow RE, Jones TK, Levitt SH. Pineal and ectopic pineal tumors: the role of radiation therapy. *Cancer* 1981;48:708–713
22. Rich TA, Cassady JR, Strand RD, Winston KR. Radiation therapy for pineal and suprasellar germ cell tumors. *Cancer* 1985;55:932–940
23. Araki C, Matsumoto S. Statistical reevaluation of pinealoma and related tumors in Japan. *J Neurosurg* 1969;30:146–149
24. Sato Y, Matsuoka Y, Nakamura T. Treatment of primary intracranial germinomas. *Neurol Med Chir (Tokyo)* 1987;27:841–847 (in Japanese)