

Are your **MRI contrast agents** cost-effective?

Learn more about generic **Gadolinium-Based Contrast Agents**.



FRESENIUS
KABI

caring for life

AJNR

A simple method for spinal localization in MR imaging.

R Tien, T H Newton, W P Dillon and M W McDermott

AJNR Am J Neuroradiol 1989, 10 (6) 1232

<http://www.ajnr.org/content/10/6/1232.citation>

This information is current as
of May 10, 2024.

A Simple Method for Spinal Localization in MR Imaging

Robert Tien,^{1,2} T. Hans Newton,¹ William P. Dillon,¹ and Michael W. McDermott³

MR imaging has become a powerful tool in the study of the spinal canal and its contents. In spite of the many advantages of this imaging technique over previous methods, the problem of spinal localization remains when imaging the upper, mid, and lower thoracic spine. Identification of the correct anatomic level in these regions holds obvious implications for planning therapy [1]. By using gelatin cod liver oil capsules as a surface marker, the problem of spinal localization can be easily overcome. The second cervical vertebra and the L5-S1 junction are used as anatomic reference points on preliminary scout films, which include the surface marker. Sagittal T1-weighted scout images with a large field of view are obtained to cover

the area of interest as well as to serve as a reference point, such as the C2 or the L5-S1 level (Figs. 1 and 2). The surface marker, which is visualized as a prominent bright spot, can then be correlated with a particular vertebral body to allow accurate localization when imaging the rest of the thoracic spine. This technique is simple and safe for overcoming the problem of spinal localization.

REFERENCE

1. Zimmerman RA, Bilaniuk LT. Imaging of tumors of the spinal canal and cord. *Radiol Clin North Am* 1988;26:965-966

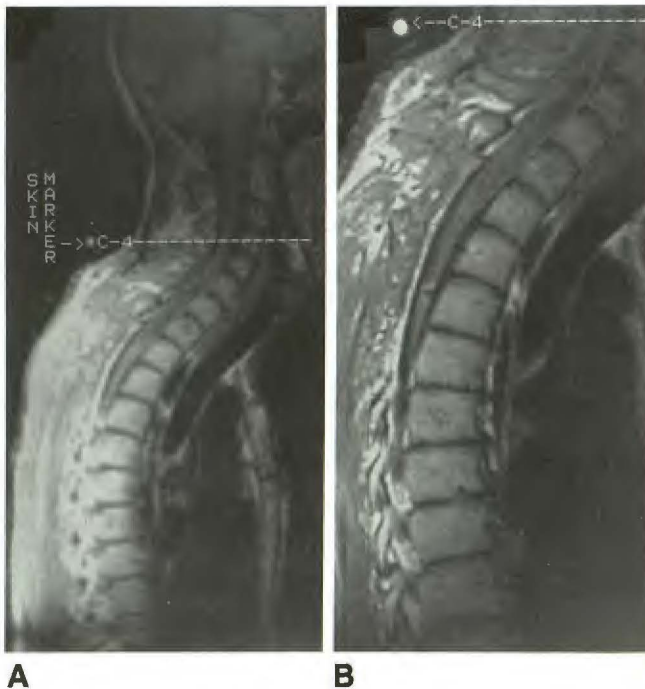

Fig. 1.—A, On sagittal localizer, surface marker (cod liver oil capsule) is at C4 level.

B, Sagittal T1-weighted image of thoracic spine shows surface marker clearly. It can be localized to level of C4 from image in A. Subsequently, any thoracic upper or mid-vertebral body can be accurately identified by using this reference point.

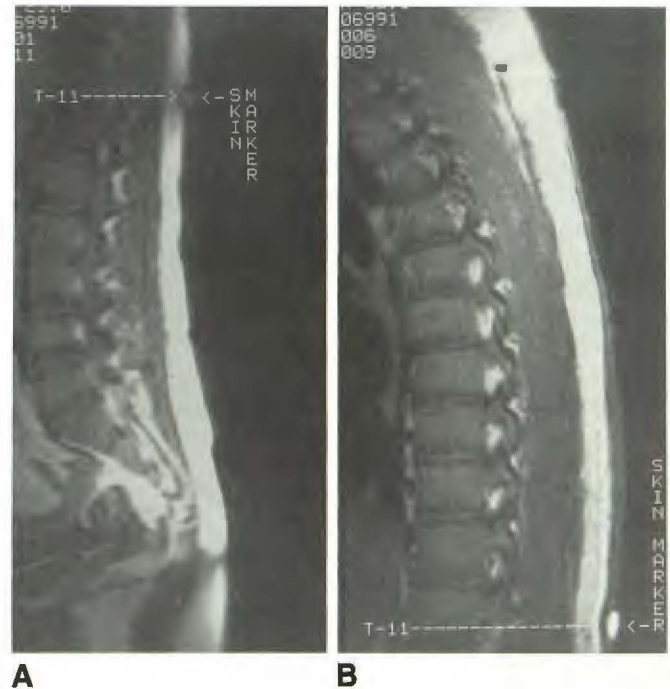


Fig. 2.—A, On sagittal localizer, surface marker is at T11 level.

B, On sagittal T1-weighted image of mid and lower thoracic spine, the surface marker (T11 from image in A) enables identification of correct level.

Received April 25, 1989; accepted April 26, 1989.

¹ Department of Radiology, Neuroradiology Section, University of California, San Francisco, CA 94143.

² Present address: Department of Radiology, University of California San Diego Medical Center, 225 Dickinson St., San Diego, CA 92103. Address reprint requests to R. Tien.

³ Department of Neurosurgery, Division of Neuro-Oncology, University of California, San Francisco, CA 94143.