

Are your **MRI contrast agents** cost-effective?

Learn more about generic **Gadolinium-Based Contrast Agents**.



FRESENIUS  
KABI

caring for life

# AJNR

## **Spinal cord ischemia after resection of thoracoabdominal aortic aneurysms: MR findings in 24 patients.**

M E Mawad, V Rivera, S Crawford, A Ramirez and W Breitbach

*AJNR Am J Neuroradiol* 1990, 11 (5) 987-991

<http://www.ajnr.org/content/11/5/987>

This information is current as of April 19, 2024.

# Spinal Cord Ischemia After Resection of Thoracoabdominal Aortic Aneurysms: MR Findings in 24 Patients

Michel E. Mawad<sup>1</sup>  
 Victor Rivera<sup>2</sup>  
 Stanley Crawford<sup>3</sup>  
 Ariel Ramirez<sup>2</sup>  
 Wini Breitbach<sup>2</sup>

MR images of the thoracic spinal cord were made in 24 patients who developed signs and symptoms of spinal cord ischemia or infarction following surgery for a thoracoabdominal aortic aneurysm. Findings consisted primarily of four different patterns of signal abnormalities in the distribution of the anterior spinal artery. These abnormalities were identified as types A–D, depending on the degree of involvement of the gray matter and surrounding white matter. We found good correlation between the distribution of the signal abnormalities in the cord, the severity of the neurologic deficits, and the clinical outcome.

MR is the imaging method of choice for diagnosing spinal cord ischemia or infarction. A thorough knowledge of the spinal cord arterial territories is crucial for characterizing ischemic MR signal abnormalities and for differentiating them from other causes of myelopathy.

*AJNR* 11:987–991, September/October 1990; *AJR* 155: December 1990

Spinal cord ischemia or infarction is a rare clinical disorder that presents with signs and symptoms referable primarily to the lower thoracic cord and conus medullaris, and often results in the rapid onset of paraplegia and bowel and bladder dysfunction. It affects predominantly the older age group, particularly in the presence of risk factors such as atherosclerosis, diabetes, and hypertension. A major predisposing factor for spinal cord ischemia or infarction is the presence of a large thoracoabdominal aortic aneurysm involving the intercostal artery, which gives rise to the anterior spinal artery or artery of Adamkiewicz. All patients included in the present study had a thoracoabdominal aortic aneurysm and became symptomatic following surgical repair of the aneurysm. The diagnosis of spinal cord ischemia is based on the abrupt onset of the clinical symptoms and the predisposing factors. Nevertheless, other possible causes of lower thoracic myelopathy need to be excluded. MR has become the imaging method of choice for evaluating spinal cord ischemia, because it reliably excludes other causes of myelopathy such as extramedullary compressive lesions, intramedullary expansile neoplasms, or cavities. More important, it detects subtle signal abnormalities intrinsic to the spinal cord, which corroborate the clinical suspicion of spinal cord ischemia.

## Materials and Methods

Forty patients developed symptoms of spinal cord ischemia following resection and graft replacement of thoracoabdominal aortic aneurysms. The patients consisted of 25 males and 15 females, 16 to 89 years old. In 24 patients, MR studies were obtained on a Siemens Magnetom 1.0-T scanner: these patients comprise the subjects of this report. Scanning parameters included sagittal T1-weighted images, 450/25/2 (TR/TE/excitations); axial T1-weighted images, 450/25/2; and axial T2-weighted double-echo images, 3000/90/1. Slice thickness was 4–5 mm, with an interslice gap of 1 mm.

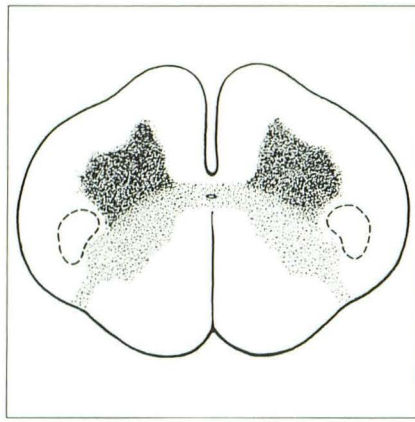
Received September 23, 1989; revision requested December 20, 1989; revision received April 18, 1990; accepted April 26, 1990.

<sup>1</sup> Department of Radiology, The Methodist Hospital, Baylor College of Medicine, 6565 Fannin, M.S. 033, Houston, TX 77030. Address reprint requests to M. E. Mawad.

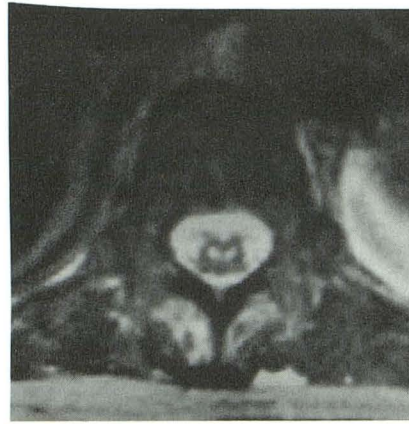
<sup>2</sup> Department of Neurology, The Methodist Hospital, Baylor College of Medicine, Houston, TX 77030.

<sup>3</sup> Department of Cardiovascular Surgery, The Methodist Hospital, Baylor College of Medicine, Houston, TX 77030.

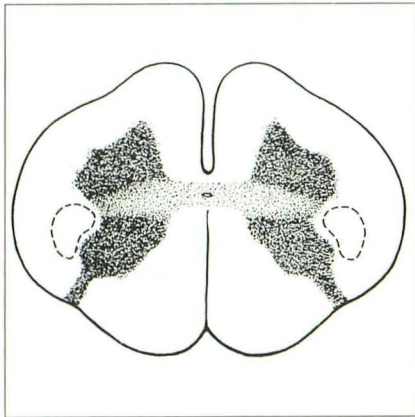
0195–6108/90/1105–0987  
 © American Society of Neuroradiology



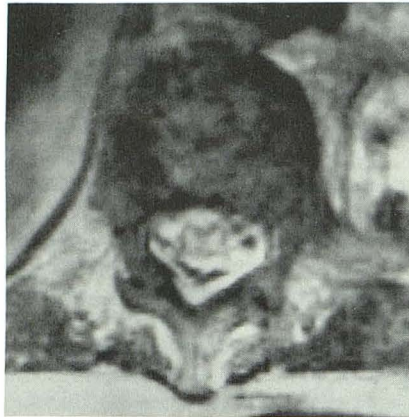A



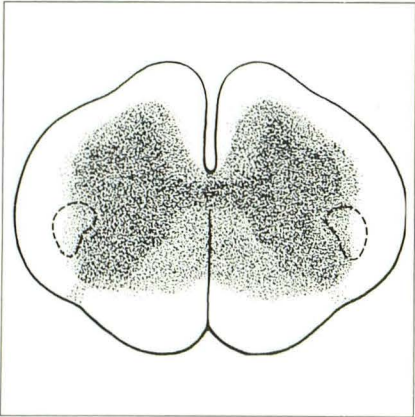
B



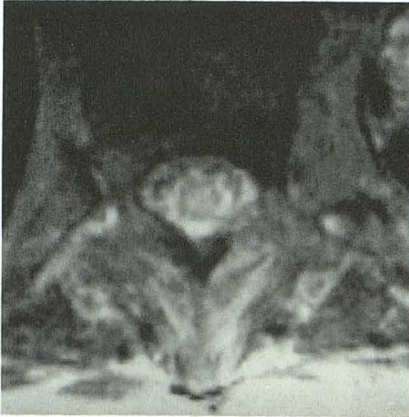C



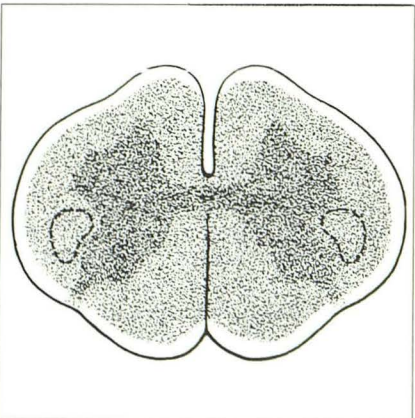
D



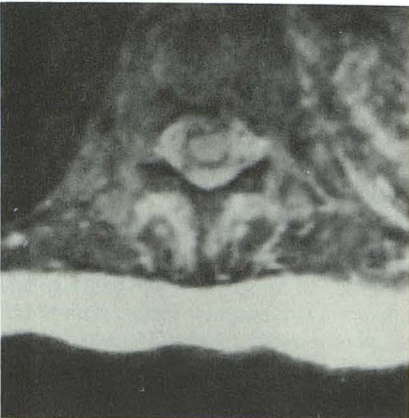E



F



G



H

Fig. 1.—Patterns of MR signal abnormalities in spinal cord ischemia.

A and B, Type A: focal signal abnormality involving primarily the anterior horns of the gray matter: "owl's eyes" pattern. Schematic (A) and axial T2-weighted MR image, 3000/90/1, (B).

C and D, Type B: signal abnormality involving both the anterior and posterior horns of the gray matter. Schematic (C) and axial T2-weighted MR image, 3000/90/1, (D).

E and F, Type C: signal abnormality involving the entire gray matter and the adjacent central white matter. Schematic (E) and axial T2-weighted MR image, 3000/90/1, (F).

G and H, Type D: diffuse signal abnormality involving the entire cross section of the spinal cord. Schematic (G) and axial T2-weighted MR image, 3000/90/1 (H).

**TABLE 1: Clinical/MR Correlation in Spinal Cord Ischemia (n = 17)**

Initial Clinical Presentation	Location of Aneurysm	Location of MR Abnormality	Somatosensory Evoked Potential	MR Signal Abnormalities	Motor Function <sup>a</sup>
Spinal cord TIA (4)	Midthoracic	1 = Low thoracic 3 = Low thoracic and conus	Abnormal	Focal, limited to gray matter	Ambulatory (5/5)
Spinal cord RIND (1)	Midthoracic	Low thoracic	Abnormal	Focal, limited to gray matter	Ambulatory (5/5)
Completed spinal cord stroke (12)	Midthoracic and thoracoabdominal	1 = Low thoracic and conus 5 = Conus 5 = Mid-, low thoracic and conus	Abnormal	Diffuse, involving both gray and white matter	Nonambulatory (0/5)

Note.—RIND = reversible ischemic neurologic deficit.

<sup>a</sup> Motor function assessed on the muscle strength scale (range, 0–5).

## Results

MR studies were abnormal in 17 patients, which correlated well with the results of the somatosensory evoked potential studies, which were abnormal in all 17 (see Table 1). All the signal abnormalities seen on the MR studies were found in the low thoracic cord and conus medullaris, regardless of the severity of the clinical findings. The MR signal abnormalities in the spinal cord were best seen on the axial proton-density-weighted (short TE/long TR) and T2-weighted (long TE/long TR) scans. The T1-weighted studies were equivocal at best; occasionally they showed ill-defined signal abnormalities intrinsic to the spinal cord manifested primarily by irregular and heterogeneous foci of prolongation of T1 without definite enlargement of the spinal cord. The abnormalities on the double-echo studies were more striking and were classified into four patterns depending on the distribution of the signal abnormalities inside the spinal cord (Fig. 1).

Table 1 correlates the findings between the initial clinical presentation, location of the operated aneurysms, MR signal abnormalities, results of the somatosensory evoked potential studies, and the clinical outcome.

All patients who developed spinal cord ischemia after aortic surgery and had abnormal MR scans also had predisposing risk factors such as hypertension, diabetes mellitus, atherosclerosis, chronic obstructive pulmonary disease, or a history of cerebral infarction. The majority of these patients had aneurysms of the descending aorta reaching to or extending below the diaphragm. Three major groups of neurologic signs and symptoms related to spinal cord ischemia can be identified: spinal cord TIAs manifested by transient motor deficit and sphincter dysfunction that resolve without residual neurologic deficit, spinal cord reversible ischemic neurologic deficit with minor residual neurologic deficit (motor = 4/5 on the muscle strength scale), and completed spinal cord stroke with devastating clinical outcome including flaccid paraplegia and complete sphincter dysfunction. All of the completed spinal cord strokes occurred in patients with thoracic and thoracoabdominal aortic aneurysms.

## Discussion

Spinal cord ischemia or infarction is a rare clinical disease that affects primarily the older age group usually with a

devastating outcome. Patients with atherosclerosis, hypertension, diabetes, or a history of cerebral stroke are at higher risk of developing spinal cord ischemia than are others in the same age group. Most cases of spontaneous spinal cord ischemia occur in patients with a thoracoabdominal aortic aneurysm; the presumed mechanism is the occlusion of the intercostal artery giving rise to the anterior spinal artery. Dissecting thoracoabdominal aortic aneurysms, especially those with a left-sided false lumen, are associated with a higher incidence of spinal cord ischemia, because in 85% of the population the anterior spinal artery arises from the left lower intercostal vessels.

Thirty-one pairs of radicular arteries [1, 2] penetrate the spinal canal through the intervertebral foramina; approximately seven or eight of these 62 radicular branches contribute to the vascularization of the spinal cord and define three major spinal arterial territories: cervicothoracic, midthoracic, and thoracolumbar (Fig. 2).

The cervicothoracic territory includes the cervical spinal cord, its brachial plexus enlargement, and the first two or three thoracic segments. This territory is richly supplied by the anterior spinal artery arising from the intracranial vertebral arteries, the midcervical radicular branches of the vertebral artery, and the branches of the costocervical trunk.

The midthoracic territory is usually supplied by a radicular branch arising at about the T7 level; it comprises the fourth to eighth segments of the thoracic cord.

The thoracolumbar territory includes, in addition to the lower thoracic segments, the lumbar enlargement, which relates to the lumbosacral plexus. This segment derives its blood supply from a single artery described in 1882 by Adamkiewicz. In about 75% of the cases, this artery originates from the ninth, 10th, 11th, or 12th intercostal arteries. In about 10% of cases, it arises from the first or second lumbar arteries. In about 15% of cases it arises from the higher intercostal vessels (i.e., from T5 through T8). When the artery of Adamkiewicz originates from a high intercostal vessel, there usually is a supplemental arterial supply to the conus medullaris from a smaller radicular branch originating more inferiorly.

When they reach the surface of the spinal cord, the radicular arteries form two distinct systems of intrinsic blood supply to the spinal cord (Fig. 3). The first system is a posterolateral

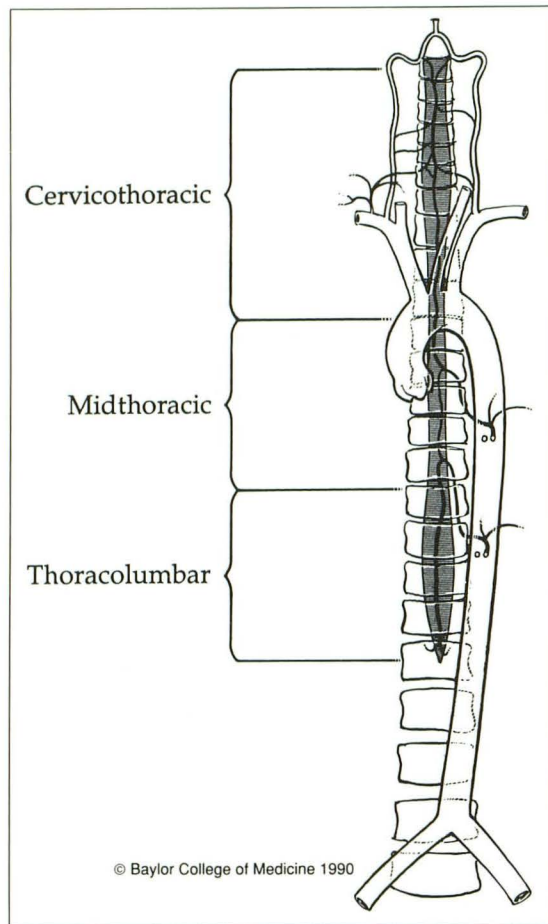


Fig. 2.—Schematic showing arterial territories of spinal cord.

and peripheral plexus formed primarily by the two posterior spinal arteries that run longitudinally along the posterolateral sulcus of the cord and are richly interconnected by anastomotic channels [3]. This is a centripetal vascular territory with penetrating branches that supply from one third to one half of the outer rim of the spinal cord. The second arterial system intrinsic to the spinal cord is a centrifugal system formed by numerous alternating central arteries that arise from the anterior spinal artery, run horizontally in the central sulcus, and turn alternately to the right and left [4]. This centrifugal system supplies the central gray matter and an adjacent mantle of central white matter, which includes the corticospinal tracts (Fig. 4).

The number of central arteries supplying each segment of the spinal cord varies with the region of the cord [5]. They are most numerous in the thoracolumbar segment and least numerous in the upper thoracic segment. The intrinsic arterial blood supply to the spinal cord is directly proportional to the cross-sectional area of the gray matter [6], which is most abundant in the thoracolumbar segment and has a much higher metabolic rate than the white matter. Therefore, in normal conditions, the blood flow to the spinal cord is highest in the thoracolumbar segment, which has the highest concen-

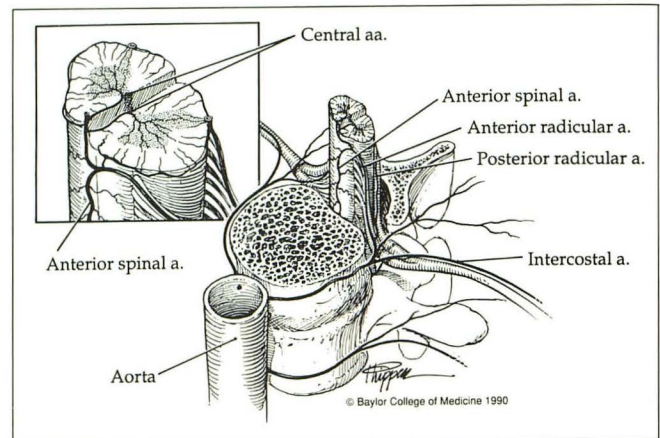


Fig. 3.—Schematic showing intrinsic blood supply of spinal cord.

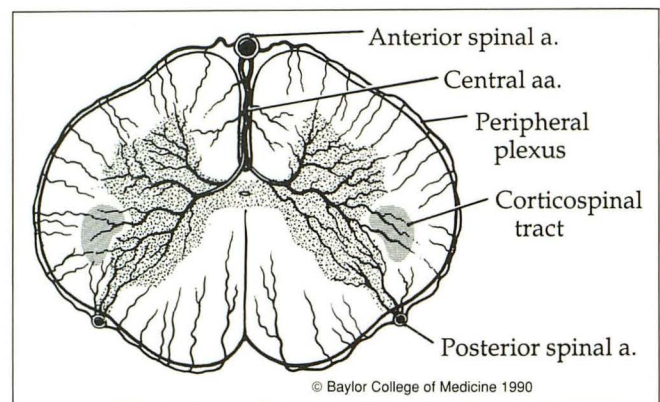


Fig. 4.—Schematic showing cross-sectional territory of anterior spinal artery.

tration of central arteries owing to the relative abundance of gray matter. Consequently, the same segment is the most vulnerable to hypoperfusion, particularly the gray matter that corresponds to the lumbar enlargement of the spinal cord. Ischemia or infarction in the distribution of the anterior spinal artery rapidly leads to cytotoxic and vasogenic edema in the gray matter with subsequent increase in mobile water. This is manifested by a focal increase in the proton density and a lengthening of the T2 relaxation time, which appears as distinct foci of increased signal intensity on the short TE/long TR and long TE/long TR pulse sequences. The signal abnormalities start in the anterior horns of the gray matter and, with increasing severity of ischemia, spread posteriorly to involve the posterior horns. Ultimately, the ischemic changes and corresponding MR signal abnormalities extend laterally to the posterolateral funiculi of the spinal cord, including the crossed corticospinal tracts. In severe cases, the whole cross section of the spinal cord is infarcted. The patterns of signal abnormality described above reflect a temporal sequence of ischemic changes that can often be recognized as distinct, separate stages. The MR appearance, however, is frequently a mixture of patterns, particularly in the patients with completed spinal cord stroke. The early stage of signal abnor-

malities, which is limited to the anterior horns of the gray matter and has an "owl's eyes" appearance, is the most characteristic of the four patterns and the most often recognized.

It becomes evident from the above discussion that axial double-echo MR studies are necessary for the diagnosis of spinal cord ischemia, since the geographic distribution of the signal abnormalities within the gray matter cannot be accurately displayed on sagittal scans. In addition, well-positioned scans with cardiac gating and motion-suppression gradients, as well as proper patient sedation, are necessary to avoid artifactual signal abnormalities in the center of the cord.

There seems to be a correlation between the distribution of the MR signal abnormalities and the severity of the clinical symptomatology seen in spinal cord ischemia. Cases in which the increased signal intensity was limited to the anterior horns of the gray matter had some preservation of motor function and a better clinical outcome than those in which the signal abnormalities were more diffuse and involved the adjacent central white matter. This region of the white matter may be supplied by either the centrifugal arterial system dependent on the anterior spinal artery or the centripetal peripheral system arising from the posterior spinal arteries. The collateral arterial circulation and the presence of small accessory anterior spinal arteries arising from the lower thoracic intercostal or upper lumbar vessels play a major role in the prevention of spinal cord ischemia when the anterior spinal artery is occluded. Infarction of the spinal cord related to aortic disease or corrective aortic surgery depends almost solely on the individual variation in spinal cord arterial blood supply and its potential collaterals. It would be beneficial to know the level of origin of the anterior spinal artery and the potential for collateral circulation to the lower thoracic cord in patients with thoracoabdominal aortic aneurysm undergoing surgical correction. This would, however, require spinal arteriography, which becomes technically difficult, if not dangerous, in patients with atherosclerotic aorta and a thoracoabdominal aneurysm.

Several theories have been advanced to explain the pathogenesis of spinal cord ischemia following corrective aortic surgery, and these involve major technical factors [7]. Hypoperfusion in the abdominal aorta due to clamping seems to play a major role in inducing spinal cord ischemia, particularly when the period of clamping exceeds a certain time limit. Several authors have recommended protective measures during surgery, such as hypothermia, left heart bypass, or jump grafts to avoid significant blood pressure drop in the aorta distal to the clamp. Others have abandoned these measures with no significant change in the occurrence of spinal cord ischemia following aortic surgery [8]. The declamping syndrome after declamping of the infrarenal aorta is another possible technical factor responsible for spinal cord ischemia. It may be circumvented by moderate volume loading prior to declamping in an effort to avoid hypoperfusion of the spinal cord.

Spinal cord tamponade by increased pressure of the CSF

during clamping of the aorta may also lead to spinal cord ischemia during aortic surgery [9, 10]. Clamping of the aorta leads to an increase in intracranial pressure, which is followed by a shift of CSF into the spinal subarachnoid space and a subsequent rise in the spinal CSF pressure. This rise in CSF pressure can tamponade the spinal cord at a time when its blood supply is compromised, resulting in spinal cord ischemia.

## Conclusions

Spinal cord ischemia or infarction involves primarily the lower thoracic cord and conus medullaris. It affects predominantly the central gray matter in a somewhat predictable fashion. In our series, all cases resulted from corrective surgery on the aorta to repair a thoracoabdominal aortic aneurysm. In these circumstances the onset of motor deficit in the lower extremities, particularly when associated with sphincter dysfunction, is strongly suggestive of spinal cord ischemia. MR of the lower thoracic cord and conus medullaris has become the imaging method of choice—not only to detect signal abnormalities intrinsic to the cord but also to exclude other causes of thoracic myelopathy. The abnormal signal intensities start in the territory of the anterior spinal artery and spread to the adjacent central white matter. The extent of signal abnormalities correlates well with the severity of the clinical findings and the potential for recovery. The frequency of spinal cord ischemia or infarction following corrective surgery of the aorta remains unpredictable given the individual variation of the spinal cord blood supply. Despite the refinement of surgical techniques and the various protective measures to diminish its risk, the rate of occurrence of this complication has perhaps reached an irreducible minimum.

## REFERENCES

1. Lazorthes G, Gouaze A, Zadeh JO, et al. Arterial vascularization of the spinal cord. *J Neurosurg* 1971;35:253-269
2. Lazorthes G, Poulhes J, Bastide G, et al. La vascularization arterielle de la moelle. *Neurochirurgie* 1958;4:3-19
3. Gillilan L. The arterial blood supply of the human spinal cord. *J Comp Neurol* 1958;110:75-103
4. Herren RY, Alexander L. Sulcal and intrinsic blood vessels of human spinal cord. *Archives of Neurology & Psychiatry* 1939;41:678-687
5. Woollam DHM, Millen JW. The arterial supply of the spinal cord and its significance. *J Neurol Neurosurg Psychiatr* 1955;18:97-102
6. Suh TH, Alexander L. Vascular system of the human spinal cord. *Arch Neurol Psychiatry* 1939;41:660-676
7. Ross RT. Spinal cord infarction in disease and surgery of the aorta. *Can J Neurol Sci* 1985;12:289-295
8. DeBaKey ME, McCullom CH, Crawford ES, et al. Dissection and dissecting aneurysm of the aorta: twenty year follow-up of five hundred twenty-seven patients treated surgically. *Surgery* 1982;92:118-134
9. Brusoni B, Colombo A, Merlo L, et al. Hemodynamic and metabolic changes induced by temporary clamping of the thoracic aorta. *Eur Surg Res* 1978;10:206-216
10. Blaisdell FW, Cooley DA. The mechanism of paraplegia after temporary thoracic occlusion and its relationship to spinal fluid pressure. *Surgery* 1962;51:355-361