AJNR

This information is current as of October 11, 2024.

Effects of gadopentetate dimeglumine administration after osmotic blood-brain barrier disruption: toxicity and MR imaging findings.

S M Roman-Goldstein, P A Barnett, C I McCormick, M J Ball, F Ramsey and E A Neuwelt

AJNR Am J Neuroradiol 1991, 12 (5) 885-890
http://www.ajnr.org/content/12/5/885

Effects of Gadopentetate Dimeglumine Administration After Osmotic Blood-Brain Barrier Disruption: Toxicity and MR Imaging Findings

Simon M. Roman-Goldstein[1,2]
Peggy A. Barnett[2]
Christopher I. McCormick[2]
Melvyn J. Ball[3]
Fred Ramsey[4]
Edward A. Neuwelt[2]

Osmotic blood-brain barrier disruption with intraarterial chemotherapy has been shown to be beneficial in the treatment of malignant brain tumors. Imaging blood-brain barrier disruption is necessary to document the extent and degree of disruption and to correlate disruption with drug delivery. The present study evaluated blood-brain barrier disruption with gadopentetate dimeglumine-enhanced MR imaging and the associated toxicity of gadopentetate dimeglumine administration. Blood-brain barrier disruption was performed in seven dogs for imaging analysis and 17 dogs for toxicity evaluation. In the absence of gadopentetate dimeglumine administration, blood-brain barrier disruption could not be imaged. Enhanced MR imaging with a gadopentetate dimeglumine dose of 0.1 mmol/kg provided good images of disruption at an imaging time of 3 hr after disruption. However, when gadopentetate dimeglumine was given intravenously in conjunction with osmotic blood-brain barrier disruption, there was a statistically significant ($p = .02$) dose-dependent increase in the frequency of seizures, with 50% of the animals who received 0.1 mmol/kg and 75% who received 0.2 mmol/kg developing delayed seizures. Our findings show that, as with ionized iodinated CT contrast agents, gadopentetate dimeglumine is associated with toxicity when used in conjunction with osmotic blood-brain barrier disruption in dogs. Such toxicity may be a contraindication to the use of gadopentetate dimeglumine for monitoring patients with osmotically induced disruption of the blood-brain barrier.

***AJNR* 12:885–890, September/October 1991**

Received October 16, 1990; revision requested January 28, 1991; revision received March 21, 1991; accepted March 25, 1991.

Presented in part at the annual meeting of the American Society of Neuroradiology, Orlando, March 1989.

This work was supported by the Veterans Administration Merit Review Grant, the National Institutes of Health Grant No. CA31770, the National Institutes of Health Grant No. 1 RO1 NS27757-01A1, and a grant from the Medical Research Foundation of Oregon.

[1] Departments of Diagnostic Radiology and Neurology, Oregon Health Sciences University, Portland, OR 97201.

[2] Department of Neurology and Division of Neurosurgery, Oregon Health Sciences University, 3181 S.W. Sam Jackson Park Rd., Portland, OR 97201-3098. Address reprint requests to E. A. Neuwelt.

[3] Department of Pathology, Oregon Health Sciences University, Portland, OR 97201.

[4] Department of Statistics, Oregon State University, Corvallis, OR 97331.

0195-6108/91/1205-0885
© American Society of Neuroradiology

Osmotic blood-brain barrier (BBB) disruption is a therapeutic procedure enabling greater delivery of antineoplastic agents to brain and brain tumors. Clinical studies have shown BBB disruption in association with chemotherapy to be a promising treatment for brain tumors [1, 2].

A crucial step in the treatment protocol is imaging the anatomic extent and degree of BBB disruption that can be correlated with the quantity of drug delivery. Currently, radionuclide imaging with ^{99m}Tc-glucoheptonate is used to monitor osmotic BBB disruption [3]. This method suffers from a lack of spatial resolution and, thus, detailed information regarding the disrupted area. Iodinated enhanced CT scanning gives a better measure of disruption resulting from moderate differences in Houndsfield units from the disrupted hemisphere to the nondisrupted hemisphere. However, ionized iodinated contrast material is epileptogenic and is associated with an increased frequency of seizures when given across the disrupted BBB in brain tumor patients [3–5]. MR imaging has excellent spatial resolution and semiquantitative measurements can be obtained. The purpose of the current study was to determine the minimum concentration of gadopentetate dimeglumine (Magnevist, Berlex Imaging, Wayne, NJ) necessary to monitor BBB disruption by MR and to evaluate the neurotoxicity associated with increased delivery following BBB disruption. These studies may also be relevant to other clinical situations in which major alterations occur in the BBB, such as after major trauma, infections, or vascular insults.

Materials and Methods

Osmotic BBB Disruption in Dogs

Adult conditioned dogs (20–25 kg) were anesthetized with sodium thiopental (20 mg/kg), intubated with an endotracheal tube, and ventilated with a Harvard animal respirator (Harvard Apparatus Company, Inc., Millis, MA). Valium was administered IV (5 mg) and IM (5 mg). Anesthesia was maintained with a 60% nitrous oxide to oxygen mixture and supplemental sodium thiopental (1–3 mg/kg, IV) given at 15–20 min intervals. An IV catheter (18 g) was used for anesthetic drug infusion and fluid management. Arterial blood gases were maintained at a pCO_2 of 25–35 mm Hg and a pO_2 >70 mm Hg (Instrumentation Laboratory, Boston, MA). Heart rate via an esophageal stethoscope, blood pressure, temperature, and urine output were monitored. Atropine sulphate (0.015 mg/kg, IV) was administered to prevent stimulation of the carotid body and Lasix (5–8 mg, IV) (Furosemide, Hoechst-Roussel Pharmaceuticals, Inc., Summerville, NJ) was given to compensate for the 1.5% increase in brain water normally associated with osmotic BBB opening.

BBB disruption was performed by using the technique described previously by Neuwelt et al. [6, 7]. The left internal carotid artery was surgically exposed and cannulated with a 16-gauge catheter via the common carotid artery. Evans blue-albumin (EBA) (2%, 3 ml/kg, IV) was administered 15 min before barrier opening to provide a dye marker of the barrier opening. EBA is known to bind tightly but reversibly to plasma albumin, and does not normally penetrate the tight junctions between cerebral endothelial cells. Mannitol (25%) (Abbott Laboratories, North Chicago, IL) at 37°C was filtered (0.20 μm, Nalge Company, Rochester, NY) and then infused into the left internal carotid artery at a rate of 1.5 ml/sec for 30 sec.

Grading of Disruption

In imaging studies, BBB disruption was graded at the time of sacrifice by direct visualization of the EBA staining in the anterior cerebral artery (ACA), middle cerebral artery (MCA), and posterior cerebral artery (PCA) territories of both the nondisrupted hemisphere and disrupted hemisphere according to the following scale: grade 0 = no staining; grade 1+ = just noticeable staining; grade 2+ = moderate blue staining; and grade 3+ = dark blue staining. For the imaging studies, animals were sacrificed within 3 hr of BBB disruption. For the toxicity studies, the time from disruption to sacrifice varied from 5 to 45 days and, therefore, the success of BBB disruption in the ACA, MCA, and PCA territories bilaterally was graded as present (+) or absent (−). In previous canine studies, staining of brain parenchyma has been shown to persist for at least 45 days after disruption [6, 7].

Imaging Studies

BBB disruption was imaged on a 1.5-T Signa scanner (General Electric, Milwaukee, WI). After sacrifice the brain was harvested and T1-weighted 300–600/20/2 images were obtained. Different repetition times were used in order to obtain a measurement of T1. Proton density images were obtained with sequences of 2000/35/2 or 2000/20,40/2. T2-weighted images were obtained with sequences of 2000/70/2 or 2000/60,80/2. The linear head coil was used in all brain imaging studies. All scans had a 256 × 256 matrix and a 3-mm slice thickness. Images were acquired in two animals who were not given gadopentetate dimeglumine. Other animals received IV gadopentetate dimeglumine immediately after osmotic BBB disruption in the following doses: 0.01 mmol/kg (n = 1); 0.05 mmol/kg (n = 2); 0.1 mmol/kg (n = 1); and 0.2 mmol/kg (n = 1). One animal given 0.05 mmol/kg was imaged 0.5 hr after BBB disruption while all others were imaged 3 hr after disruption. Three hours would be the earliest time in which a brain tumor patient undergoing a BBB procedure and intraarterial chemotherapy could safely undergo MR imaging [1, 2].

On gadopentetate dimeglumine-enhanced MR images, disruption was graded by comparing the disrupted hemisphere to that of the nondisrupted hemisphere on a scale analogous to that of EBA grading with 0 = no difference; 1+ = barely visible enhancement; 2+ = easily visible enhancement; and 3+ = intensely visible enhancement. On the basis of previous experience, we would consider a 2+ enhancement to be an acceptable grade for imaging BBB disruption [3, 5]. An MR ratio was calculated in the following manner: T1 measurements were obtained in corresponding regions of interest in the nondisrupted hemisphere and disrupted hemisphere in four contiguous slices by using the three-parameter portion of the image analysis program on the Signa unit. The sum of the T1 values of the nondisrupted hemisphere was divided by the sum of the T1 values of the disrupted hemisphere, resulting in the MR disruption ratio.

Toxicity Evaluation

BBB disruption was performed in 13 animals followed by IV gadopentetate dimeglumine for neurotoxicity evaluation. Each animal was given a single IV dose of gadopentetate dimeglumine immediately after disruption at one of the following doses: 0.01 mmol/kg (n = 1); 0.05 mmol/kg (n = 1); 0.1 mmol/kg (n = 6); 0.2 mmol/kg (n = 6). The control group consisted of four animals undergoing BBB disruption without gadopentetate dimeglumine.

It was hypothesized that if gadopentetate dimeglumine caused toxicity there would be increased toxicity with increased doses of gadopentetate dimeglumine. Probability analysis was used to test this hypothesis against a null hypothesis of no relationship between toxicity and the gadopentetate dimeglumine dose. For neurotoxicity evaluation, as in previous studies, animals were observed for 30–45 days after administration of gadopentetate dimeglumine unless toxicity necessitated earlier sacrifice [7]. Evidence of neurotoxicity in the canine studies included the following parameters: signs of neurologic dysfunction, signs of visual dysfunction, changes in gross motor function or behavior, and neuropathologic changes in the brain at necropsy.

After each animal was sacrificed the brain was removed and the disruption was recorded as being present or absent on the basis of EBA staining. The brain was fixed in formalin for histopathologic examination. Approximately 1 week after fixation 0.5-cm coronal sections were prepared and inspected grossly. Histologic sections of any gross lesions were prepared and stained with hematoxylin and eosin (H and E). In addition, histologic sections of cerebral cortex, white matter, basal ganglia, and brainstem were routinely prepared and reviewed. One section was taken from the frontal lobe in the ACA and MCA distribution, including the white matter of the corona radiata extending to the angle of the lateral ventricle. A second section included the posterior hippocampus, adjacent temporal lobe, thalamus, putamen, and adjacent structures. A third section was obtained through the pons or medulla and the adjacent half of the cerebellar hemisphere. All pathologic specimens were prepared and reviewed by a neuropathologist. In two animals receiving 0.2 mmol/kg, serial serum chemistries, complete blood counts, and clotting parameters were obtained to evaluate possible changes associated with gadopentetate dimeglumine administration. Laboratory values were obtained on the following schedule: prior to BBB disruption (control), twice daily for 4 days, followed by once daily for 6 days, then weekly until sacrifice.

Results

Imaging Studies

Using noncontrast-enhanced MR imaging we were unable to document disruption on a proton density- or T2-weighted image (Fig. 1). A minimum dose of 0.1 mmol/kg of gadopentetate dimeglumine, the standard clinical dose, was necessary to obtain an acceptable enhanced image at 3 hr after BBB disruption. A dose of 0.2 mmol/kg provided excellent imaging of disruption at 3 hr (Fig. 2). The calculated MR ratio corresponded with the qualitative visual grade of the MR image. A 3+ MR visual grade corresponded with a ratio of 1.5. The MR ratios showed small differences in animals with less than a 3+ disruption and did not substantially aid in differentiating between a 1+ and a 2+ disruption. The results of the EBA grade, visual MR grade, and MR ratios appear in Table 1.

Toxicity Studies

BBB disruption was obtained in 16 of 17 animals studied. The clinical and pathologic results are summarized in Table 2. IV gadopentetate dimeglumine given in association with osmotic BBB disruption was associated with neurotoxicity manifested primarily by the delayed onset of intractable seizures. Twelve animals were included in the probability analysis of the dose response of gadopentetate dimeglumine given in association with BBB disruption. There were three control animals, none of whom developed seizures, and nine animals who received gadopentetate dimeglumine, of whom five developed seizures, 50% of those given 0.1 mmol/kg and 75% of those given 0.2 mmol/kg. We were able to control the seizures with IM phenobarbital in only animals 17 and 23.

The dose-response curve is displayed as Figure 3, which shows an increase in toxicity with increasing gadopentetate dimeglumine dose. To determine if this pronounced dose response might have occurred by chance (the null hypothesis), we examined all possible outcomes to see which ones exhibit dose-dependent increases in toxicity. We found that less than 2% of the possible outcomes show a dose response as strong or stronger than that shown in Figure 3. Therefore, there is statistical evidence in favor of an increasing relationship between toxicity and gadopentetate dimeglumine dose.

Five dogs were excluded from the statistical analysis. In one, animal 15, we did not successfully disrupt the BBB. Two animals were sacrificed the day of disruption due to symptoms of uncal herniation (animals 10 and 19). Two other animals died from a bleeding diathesis possibly caused by the gadopentetate dimeglumine (animals 18 and 22).

Neuropathologic findings were generally minimal. Three dogs showed acute hypoxic encephalopathy (animals 12, 13, and 20). These lesions occurred within 24 hr of the sacrifice in a nondisrupted area of the brain and are of uncertain significance. Of the two animals who clinically demonstrated symptoms of uncal herniation, only one showed pathologic findings that confirmed the herniation (animal 19) while the other just showed some acute hippocampal hemorrhage (animal 10). Some experimental animals (16 and 17) showed small subacute areas of necrosis that were occasionally hemorrhagic in the areas of the brain where the barrier was opened (Fig. 4). According to pathologic dating, these lesions occurred from 2 days to 3 weeks prior to sacrifice and probably not on the day of the procedure. The lesions could not be dated as to whether they occurred before or after the onset of seizures. Two animals (18 and 22) developed extensive bleeding from their incision site. We were unable to isolate a bleeding source upon reexploration of the neck wounds. In two subsequent animals a clinically occult delayed thrombo-

Fig. 1.—*A*, Proton density-weighted transaxial MR image (2000/35/2) in animal 2 imaged 0.5 hr after blood-brain barrier disruption shows no difference in signal intensity between areas of disrupted left cerebral hemisphere and nondisrupted right cerebral hemisphere.

***B*, T2-weighted MR image (2000/70/2) in same animal shows no difference again between disrupted left hemisphere and nondisrupted right hemisphere.**

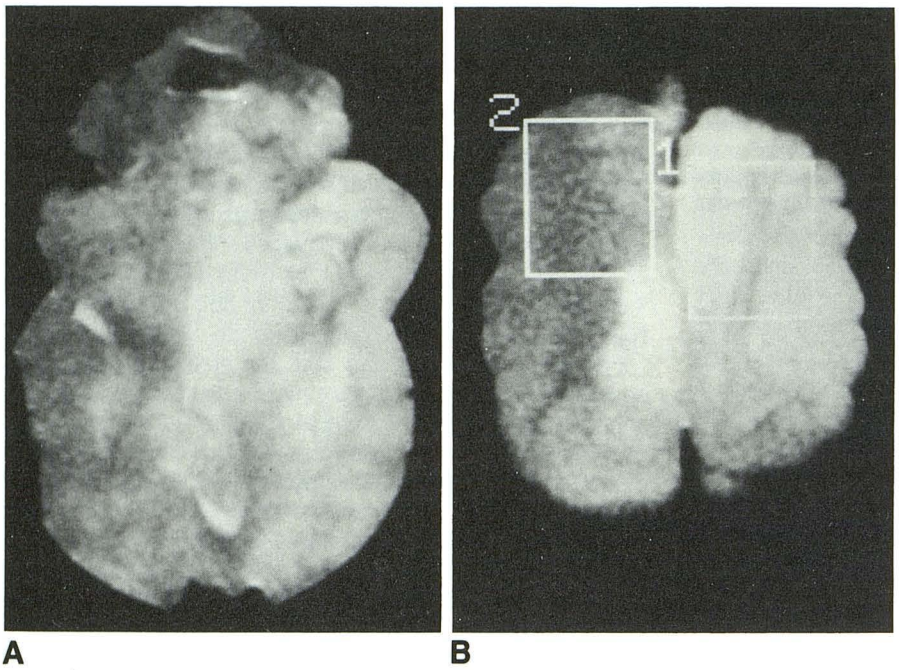

Fig. 2.—*A*, T1-weighted transaxial MR image (350/20/2) in animal 7 given 0.2 mmol/kg gadopentate dimeglumine intravenously after blood-brain barrier disruption and imaged 3 hr after disruption shows marked enhancement in disrupted left cerebral hemisphere.

B, T1-weighted image of same animal shows an example of how calculations were done for the MR ratio. The measured T1 value in area 1 in left cerebral hemisphere measured 274 vs 567 in area 2 in the nondisrupted right cerebral hemisphere, which shows T1 shortening due to enhancement in disrupted cerebral hemisphere.

TABLE 1: Correlation of MR Enhancement and Contrast Dose Following Blood-Brain Barrier Disruption

Animal No.	IV Contrast Dose	Time Between Disruption and Imaging (hr)	EBA Grade	MR Grade	MR Ratio
1	0	1.0	2+	0	ND
2	0	0.5	3+	0	ND
3	0.01	3.0	3+	0	1.03
4	0.05	0.5	3+	2+	1.16
5	0.05	3.0	3+	1+	1.07
6	0.1	3.0	3+	2+	1.13
7	0.2	3.0	3+	3+	1.49

Note.—EBA = Evans blue-albumin, ND = not done.

cytopenia occurred. One animal (23) had a control platelet count of 275,000 and a platelet nadir of 35,000 8 days after BBB disruption while the other (24) had a control value of 228,000 with a minimum 48,000 2 days after BBB disruption. In both animals the thrombocytopenia reversed spontaneously. No other laboratory abnormalities were identified.

Discussion

MR imaging without contrast enhancement did not provide visual imaging of the osmotic BBB disruption with T2-weighted images. Twice the clinical dose of gadopentetate dimeglumine (0.2 mmol/kg, IV) provided excellent imaging at 3 hr after disruption, which is the earliest feasible time a human patient could be scanned safely, while a smaller dose (0.05 mmol/kg) only allowed imaging of BBB disruption at 0.5 hours after disruption but did not show acceptable enhancement at 3 hr. In clinical procedures, the earliest time to obtain a scan is 3 hr after BBB disruption and general anesthesia; thus, a critical time point for the present MR evaluation. These imaging results agree with a prior MR study of osmotic BBB disruption, which showed that noncontrast MR was not able to image osmotic BBB disruption while gadopentetate dimeglumine-enhanced T1-weighted MR imaging could show disruption with a dose of 0.25 mmol/kg of gadopentetate dimeglumine [8]. In the present study, calculating the MR ratio served to corroborate the visual grading system and to establish the potential of semiquantitative calculations.

The neurotoxicity of gadopentetate dimeglumine has not been tested in conjunction with BBB disruption. Many drugs that have acceptable toxicity systemically are unacceptably toxic to the CNS [4, 7]. The BBB serves to protect the brain from drug toxicity. BBB disruption followed by IV drug administration yields as much as a 10-fold increase in drug delivery to the brain [6, 9].

The findings in one study [10] showed some neurotoxicity in a rodent model when gadopentetate dimeglumine was given intrathecally; this was manifested by loss of coordination in doses of 17–1233 mmol/kg. Using a primate model, other researchers [11] showed no toxicity when gadopentetate dimeglumine was given intrathecally in doses varying from 0.125 to 25 mmol/kg. No pathologic examination was performed in either of these two studies, and the duration of observation before sacrifice was not clearly stated. Therefore, according to the two studies reviewed, it is unclear whether intrathecal gadopentetate dimeglumine can be safely administered. When an agent is given intrathecally, the amount of brain penetration is variable [12, 13]. In contrast, penetration following BBB disruption results in a more uniform delivery throughout the brain. Results from studies involving intrathecal administration cannot be used to assess a drug's safety when given in association with BBB disruption.

It has been noted that in humans a dose of 0.1 mmol/kg of IV gadopentetate dimeglumine is without significant toxicity when given systemically [14, 15]; however, it is associated with a 0.1% rate of occurrence of seizures, which have been attributed to the patient's underlying disease. Administration of gadopentetate dimeglumine was associated with EEG changes in 6% of patients who had normal EEGs prior to injection [14]. Thus, gadopentetate dimeglumine may lower the seizure threshold. Seizures were not reported when ga-

TABLE 2: Clinical and Pathologic Results of Animals Following Blood-Brain Barrier (BBB) Disruption

Animal No.	IV Contrast Dose	Clinical Results	Microscopic Pathology	Time Between Disruption and Sacrifice (days)
8	0	Normal	None	54
9	0	Normal	None	45
10[a]	0	Uncal herniation	Acute microscopic hemorrhage, left hippocampal cortex	0
11	0	Normal	Small subacute infarct in left frontal white matter and thalamus	40
12	0.05	Normal	Acute focal hypoxic encephalopathy, left temporal cortex	43
13	0.1	Normal	Acute hypoxic-ischemic encephalopathy involving cerebellar Purkinje cells	40
14	0.1	Normal	None	45
15[b]	0.1	Normal	None	43
16	0.1	Seizures 12 days after BBB disruption; ineffective anticonvulsant therapy	Small subacute infarct, left frontal lobe	14
17	0.1	Seizures 19 days after BBB disruption; anticonvulsant therapy	Acute microscopic infarct, left and right frontal white matter	40
18[c]	0.1	Died 4 days after BBB disruption from chronic bleeding	Acute hemorrhagic infarct, left occipital lobe; acute bland infarcts, right frontal white matter and left hippocampus	4
19[a]	0.2	Uncal herniation	Acute pontine hemorrhage; acute hemorrhagic infarct, left occipital lobe	0
20	0.2	Seizures 5 days after BBB disruption; unable to control seizures with anticonvulsant therapy	Acute hypoxic ischemic encephalopathy in cerebellar Purkinje cells	14
21	0.2	Normal	None	40
22[c]	0.2	Seizures and acute bleeding 5 days after BBB disruption	Acute hemorrhagic necrotic lesions, left frontal and temporal cortex in left hippocampus and left mesencephalon	5
23	0.2	Immediate onset unilateral focal motor seizures, which resolved in a few days; seizures recurred intermittently at 15 days	None	33
24	0.2	Focal motor seizures 14 days after BBB disruption; ineffective anticonvulsant therapy	Acute mild cortical edema, left frontal and parietal lobes	16

Note.—Acute changes are defined as those occurring within 2 days of sacrifice. Subacute lesions occurred 3 days to 3 weeks before sacrifice. Using probability analysis, we found a statistically significant dose-dependent increase in toxicity ($p < .02$).

[a] Not included in statistical analysis because the animal died the day of disruption from uncal herniation. This is an occasional complication in the animal studies, since a constant infusion rate is used for barrier disruption.

[b] Not included in statistical analysis because no disruption was obtained.

[c] Not included in statistical analysis because animals died of a bleeding diathesis and did not complete study.

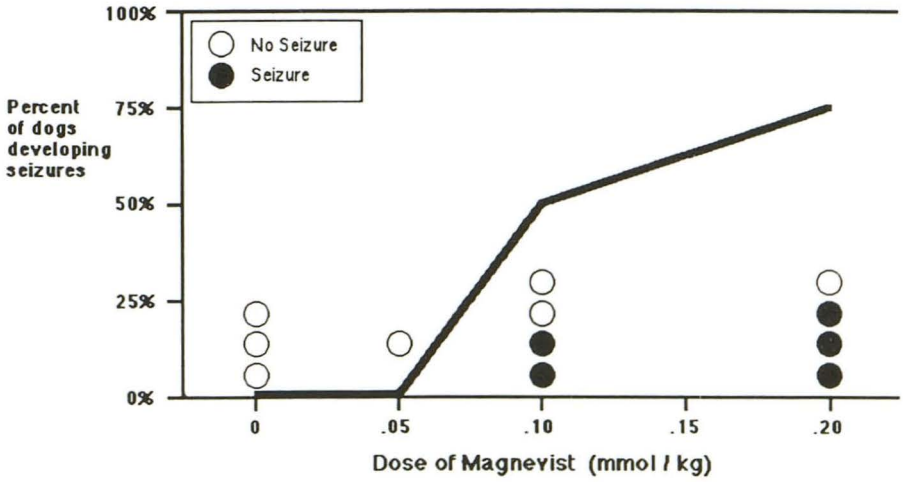

Fig. 3.—Graph shows percentage of dogs that developed seizures vs the dose of IV gadopentate dimeglumine given immediately after blood-brain barrier disruption. This graph shows an increasing frequency of seizures with an increasing dose of gadopentate dimeglumine, which was statistically significant ($p = .02$).

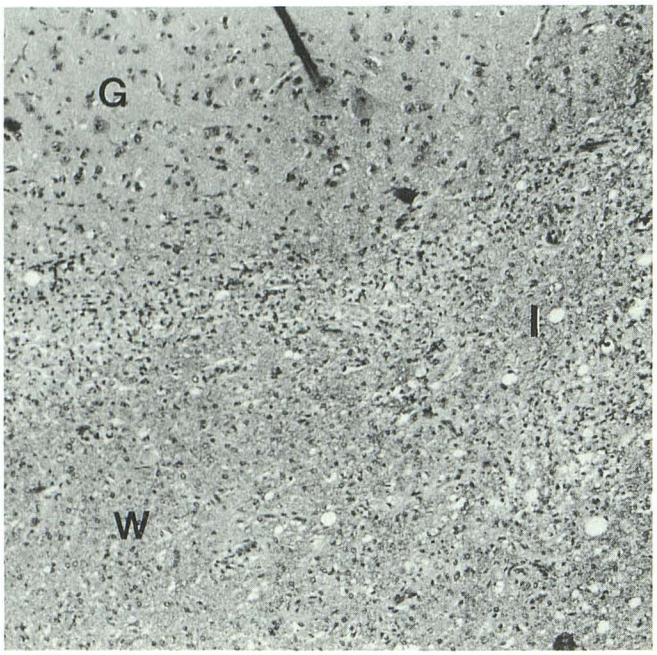

Fig. 4.—Histologic section of left frontal lobe in animal 16 shows small subacute infarct at gray-white junction. I = infarct; G = gray matter; W = white matter. (H and E, original magnification ×250).

dopentetate dimeglumine was given to patients with enhancing intraaxial lesions, even though there is some alteration in BBB permeability. We hypothesized that seizures occurred in our animals because a much greater quantity of gadopentetate dimeglumine was delivered throughout the ipsilateral hemisphere compared with uptake in the focal area of an enhancing lesion. In our canine model no underlying seizure disorder or intracranial lesions were present and the seizures were a result of gadopentetate dimeglumine delivery across the disrupted barrier.

Pathologic examination showed small areas of necrosis in areas of BBB disruption in some of the experimental animals who had seizures. One control animal who did not develop seizures also showed small areas of necrosis. We have observed such lesions occasionally in the past and thought that emboli from the carotid catheterization or the mannitol infusate may be responsible. It is unclear from our data if the pathologic abnormalities are a cause of the seizures, a result of the seizures, or unrelated to the seizures. This is consistent with prior studies, which showed the pathology associated with epilepsy is quite variable and often does not reveal the cause of the seizures [16, 17].

Two animals developed hemorrhage as a result of coagulopathy. There was a delayed subclinical reversible thrombocytopenia in two additional dogs in whom serial platelet counts were followed. We did not expect any problems with platelets or other coagulation parameters at the onset of this study, and we only obtained serial coagulation studies in the last two animals. In human studies, gadopentetate dimeglumine has not been described as causing thrombocytopenia, but platelet counts have never been obtained for more than 24 hr after injection [14, 18]. Gadopentetate dimeglumine has been reported to inhibit platelet aggregation and may modify both the intrinsic pathway of coagulation and fibrin formation [19]. Our data suggest that gadopentetate dimeglumine administered in conjunction with osmotic BBB disruption results in a delayed reversible thrombocytopenia in dogs. Serial studies of platelet counts in patients after IV injection of gadopentetate dimeglumine would confirm whether this phenomenon also occurs in humans.

In conclusion, osmotic BBB disruption can be monitored with a paramagnetic substance such as gadopentetate dimeglumine, but this contrast agent is associated with neurotoxicity and may cause coagulation abnormalities in dogs. Such neurotoxicity may be clinically relevant when there is a major compromise of BBB integrity.

ACKNOWLEDGMENTS

We thank Scott Goodnight who aided in analyzing the hematology lab values; Fran Stronko, Patrice Manley, and Kathy Griffith for scanning the animals; and Patricia Butler for preparing the manuscript.

REFERENCES

1. Neuwelt EA, Frenkel EP, Gumerlock MK, Braziel R, Dana B, Hill SA. Developments in the diagnosis and treatment of primary CNS lymphoma: a prospective series. *Cancer* **1986**;58:1609–1620
2. Neuwelt EA, Howieson J, Frenkel EP, et al. Therapeutic efficacy of multiagent chemotherapy with drug delivery enhancement by blood-brain barrier modification in glioblastoma. *Neurosurgery* **1986**;19:573–582
3. Neuwelt EA, Specht HD, Howieson J, et al. Osmotic blood-brain barrier modification: clinical documentation by enhanced CT scanning and/or radionuclide brain scanning. *AJNR* **1983**;4:907–913
4. Neuwelt EA, Pagel M, Barnett P, Glasberg M, Frenkel EP. Pharmacology and toxicity of intracarotid adriamycin administration following osmotic blood-brain barrier modification. *Cancer Res* **1981**;41:4466–4470
5. Neuwelt EA, Maravilla KR, Frenkel EP, Barnett P, Hill S, Moore RJ. Use of enhanced computerized tomography to evaluate osmotic blood-brain barrier disruption. *Neurosurgery* **1980**;6:49–56
6. Neuwelt EA, Frenkel EP, Rapoport S, Barnett P. Effect of osmotic blood-brain barrier disruption on methotrexate pharmacokinetics in the dog. *Neurosurgery* **1980**;7:36–43
7. Neuwelt EA, Glasberg M, Frenkel E, Barnett P. Neurotoxicity of chemotherapeutic agents after blood-brain barrier modification: neuropathological studies. *Ann Neurol* **1983**;14:316–324
8. Runge VM, Price AC, Wehr CJ, Atkinson JB, Tweedle MF. Contrast enhanced MRI: evaluation of a canine model of osmotic blood-brain barrier disruption. *Invest Radiol* **1985**;20:830–844
9. Neuwelt EA, Frenkel E, D'Agostino AN, et al. Growth of human lung tumor in the brain of the nude rat as a model to evaluate antitumor agent delivery across the blood-brain barrier. *Cancer Res* **1985**;45:2827–2833
10. Weinmann H-J, Brasch RC, Press W-R, Westbey GE. Characteristics of gadolinium-DTPA complex: a potential NMR contrast agent. *AJR* **1984**; 142:619–624
11. Di Chiro G, Knop RH, Girton ME, et al. MR cisternography and myelography with Gd-DTPA in monkeys. *Radiology* **1985**;157:373–377
12. Rapoport SI, Ohno K, Pettigrew KD. Drug entry into the brain. *Brain Res* **1979**;172:354–359
13. Sage MR, Wilcox J, Evill CA, Benness GT. Brain parenchyma penetration by intrathecal ionic and nonionic contrast media. *AJNR* **1982**;3:481–483
14. Goldstein HA, Kashanian FK, Blumetti RF, Holyoak WL, Hugo FP, Blumenfield DM. Safety assessment of gadopentetate dimeglumine in U.S. clinical trials. *Radiology* **1990**;174:17–23
15. Russell EJ, Schaible TF, Dillon W, et al. Multicenter double-blind placebo controlled study of gadopentetate dimeglumine as an MR contrast agent: evaluation in patients with cerebral lesions. *AJNR* **1989**;10:53–63
16. Hauser WA, Kurland LT. The epidemiology of epilepsy in Rochester, Minnesota, 1935 through 1967. *Epilepsia* **1975**;16:1–66
17. Mathieson G. Pathology of temporal lobe foci. In: Penry JK, Daly DD, eds. *Advances in neurology*, vol. 11. New York: Raven, **1975**:163–184
18. Laniado M, Weinmann HJ, Schorner W, Felix R, Speck U. First use of Gd-DTPA/dimeglumine in man. *Physiol Chem Physics Med NMR* **1984**; 16:157–165
19. Corot C, Belleville J, Paul J, Baguet J, Amiel M, Eloy R. In vitro interactions of gadolinium DOTA meglumine and gadolinium DTPA meglumine on hemostasis. *Invest Radiol* **1988**;23:S261–S263