

## MR Imaging in Cryptococcal Spondylitis

We report a case of cryptococcal spondylitis in an immunocompetent woman. The MR and CT findings in cryptococcal spondylitis may mimic those seen in tuberculous spondylitis.

### Case Report

A previously healthy 42-year-old black woman had posterior mid-thoracic tenderness; a right-sided paraspinous soft-tissue mass; and progressive, bilateral leg weakness. On examination she was afebrile and had reduced strength in both lower extremities. Chocolate-colored pus was aspirated from the paraspinous soft-tissue mass. The results of a complete blood cell count and CSF analysis were normal. Chest radiographs showed infiltrates in the lower lobes and hilar adenopathy. Sputum culture yielded only *Pseudomonas multiphilia*. Cultures for fungi and mycobacteria were negative.

MR showed an abscess in the dorsal chest wall communicating with collections in the right paravertebral and prevertebral spaces and the epidural compartment (Fig. 1A). Prevertebral extension of the process was evident from T8 to T10. T2-weighted images (2000/80/1 [TR/TE/excitations]) showed compression of the spinal cord at T9–T10, increased signal intensity within T9 and T10, and mild loss of height of T9 (Figs. 1B and 1C). Neither loss of height nor increased signal intensity was seen at the T8–T9 or T9–T10 disk levels. T1-weighted (800/11/2) fat-suppressed (ChemSat, GE Medical Systems, Milwaukee, WI) images obtained after administration of gadopentate dimeglumine showed enhancement of T8, T9, and T10 and the T9–T10 disk. The enhancement of T8 and the T9–T10 disk suggested sites of infection not appreciated on the unenhanced MR images (Figs. 1D and 1E). After chest CT showed calcified hilar and mediastinal lymphadenopathy, tuberculous spondylitis was suggested as the most likely diagnosis.

Surgical drainage of the abscess led to significant clinical improve-

ment. Examination of the initial aspirate and of the surgical specimens revealed neither caseating granulomata or acid-fast bacilli. Both the aspirate and the surgical specimens contained abundant fungi, and cultures grew *Cryptococcus neoformans* only. The patient's serum was positive for cryptococcal antigens at 1:16,384. Tests of her serum for HIV antibodies were negative.

A follow-up chest radiograph obtained 3 months after completion of therapy with amphotericin B showed no change in the bilateral basal interstitial infiltrates or the hilar and mediastinal lymphadenopathy. Obliteration of the T9–T10 disk space was evident, with marked loss of height of T9 and T10.

### Discussion

Most cases of infectious spondylitis are due to *Staphylococcus aureus*. *Mycobacterium tuberculosis* accounts for a small proportion of cases, and fungal agents are even more unusual. Fungal infections are more frequent in persons who are immunocompromised, although cryptococcal spondylitis has been reported in immunocompetent patients [1, 2].

Cryptococcal spondylitis is quite rare. In a review of the literature, Lie et al. [3] found only 11 documented cases up to 1989. To our knowledge, our case is the first one that has been evaluated with MR. Cryptococcal spondylitis may mimic tuberculous spondylitis clinically and radiologically [4]. Loss of disk height and increased signal intensity of the disk and adjacent vertebral bodies (on T2-weighted images) is typical of pyogenic spondylitis [5]. Multilevel involvement, relative preservation of disk height, normal signal intensity of the disk, destruction of the dorsal and transverse elements, and large paravertebral and subligamentous abscesses are characteristic of tuberculous spondylitis [5, 6] and were noted in our patient. However, contrast-enhanced images showed disk involvement that

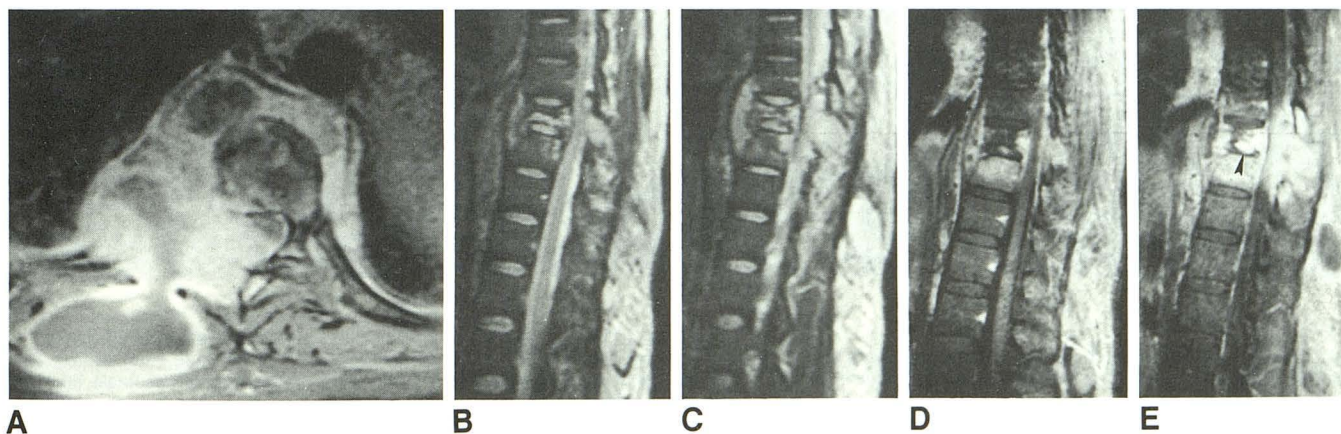


Fig. 1.—Cryptococcal spondylitis.

A, Axial fat-suppressed T1-weighted contrast-enhanced MR image (1000/11/2) shows right-sided dorsal abscess communicating with paravertebral, prevertebral, and epidural collections. Note compression of thecal sac.

B and C, Contiguous T2-weighted sagittal MR images (2000/80/1) show increased signal intensity in bodies of T9 and T10 and in dorsal spinous process of T9. Epidural disease with compression of spinal cord and prevertebral subligamentous fluid (abscess) is also evident at T9–T10 levels. Note normal height and signal intensity of T8 and of T8–T9 and T9–T10 disks.

D and E, Contiguous sagittal fat-suppressed T1-weighted contrast-enhanced MR images (800/11/2) show focal enhancement within T9–T10 disk (arrowhead); T8, T9, and T10 vertebral bodies; and the epidural compartment.

was not apparent on unenhanced images. The value of contrast-enhanced T1-weighted images in the evaluation of spinal infection has been elucidated by Post et al. [7]. We routinely use fat-suppressed contrast-enhanced T1-weighted images in cases of suspected spinal infection. In our experience, this technique facilitates differentiation of enhancing epidural abscesses from epidural fat. It also may show abnormal enhancement in regions of bone that have normal signal intensity on unenhanced images, thereby suggesting additional sites of infection.

The cause of the calcified hilar and mediastinal lymphadenopathy in this patient remains speculative. These findings are unusual with pulmonary cryptococcal infection. Cultures of the patient's sputum were negative for fungi, but sputum cultures positive for *Cryptococcus* are rare even in pathologically proved cases [8]. Tuberculosis was excluded clinically. Pulmonary sarcoidosis can be associated with calcified hilar and mediastinal adenopathy. In a review of skeletal cryptococcosis, Chleboun and Nade [2] reported that 20% of patients who had cryptococcosis had coincident sarcoidosis. As neither the thoracic lymphadenopathy nor the basal infiltrates resolved after successful antifungal therapy, coincident pulmonary sarcoidosis cannot be excluded in our patient. However, she refused further workup.

Joel K. Curé

David R. Mirich

Medical University of South Carolina  
Charleston, SC 29425

#### REFERENCES

1. Zach TL, Penn RG. Localized cryptococcal osteomyelitis in the immunocompetent host. *Pediatr Infect Dis J* **1986**; 5:601-602
2. Chleboun J, Nade S. Skeletal cryptococcosis. *J Bone Joint Surg [Am]* **1977**; 59-A:509-514
3. Lie KW, Yu YL, Cheng IKP, Woo E, Wong WT. Cryptococcal infection of the lumbar spine. *J R Soc Med* **1989**; 83:172-173
4. Koshi G, Doss S, Selvapandians AJ, Myers RM. Cryptococcosis "masquerading" as tuberculosis of the spine. *Indian J Pathol Bacteriol* **1961**; 7:264-271
5. Thrush A, Enzmann D. MR imaging of infectious spondylitis. *AJNR* **1990**; 11:1171-1180
6. Smith AS, Weinstein MA, Mizushima A, et al. MR imaging characteristics of tuberculous spondylitis vs vertebral osteomyelitis. *AJNR* **1989**; 10:619-625, *AJR* **1989**; 153:399-405
7. Post MJD, Sze G, Quencer RM, Eismont FJ, Green BA, Gahbauer H. Gadolinium-enhanced MR in spinal infection. *J Comput Assist Tomogr* **1990**; 14:721-729
8. Paré JAP, Fraser RG. *Synopsis of diseases of the chest*. Philadelphia: Saunders, **1983**: 313