

MR-Guided Aspiration and Drainage of a Nasopharyngeal Mucus Retention Cyst

MR imaging is an effective method for evaluation of the nasopharynx because of its excellent soft-tissue contrast resolution and the relative lack of motion in this area. The recent development of MR-compatible instruments [1] has made it possible to use MR-guided fine-needle aspiration in the extracranial head and neck to obtain specimens for cytologic examination [2–4]. We present a case of nasopharyngeal mucus retention cyst that was manifested as a mass and was diagnosed on the basis of the results of MR-guided needle aspiration.

Case Report

A 40-year-old man had a 9-month history of right-sided headache. MR imaging showed a small ovoid lesion with a well-demarcated margin in the right lower nasopharynx just anterolateral to the longus coli muscle. The lesion was isointense with the mucosa on T1-weighted images (Fig. 1A) and hyperintense on T2-weighted images (Fig. 1B). The levator palatini muscle was slightly displaced anteriorly, and the surrounding structures, including the parapharyngeal fat, were intact. No evidence of lymphadenopathy or middle ear effusion was present.

Nasopharyngoscopy did not show any mucosal abnormality, and multiple biopsies were performed around the area of the eustachian tube. Histopathologic examination showed no evidence of specific disease.

MR-guided needle aspiration was performed 1 month after the first MR study. Via the subzygomatic approach, a 22-gauge MR-compatible needle (E-Z-EM, Inc., Westbury, NY) was inserted into the lesion. The T1-weighted image at the level of the needle showed the needle tract as a linear signal void (Fig. 1C). The needle tip was located accurately in the lesion, and about 2 ml of tenacious mucoid fluid was aspirated. Images obtained after aspiration showed a decrease in the

size of the lesion (Fig. 1D). Cytologic examination of the aspirated fluid showed no cellular component.

The patient's symptoms improved with conservative treatment after aspiration.

Discussion

Although mucus retention cysts are common in the maxillary antrum and have no clinical significance, they are rare in the nasopharynx. Retention cysts involving the minor salivary glands are found infrequently in the oral cavity [5] and, to our knowledge, no reports describing the MR features of retention cysts of the nasopharynx have been published.

Most lesions arising in the nasopharynx are malignancies [5]. The site of origin may be mucosal or submucosal, and direct observation and biopsy of small lesions may not be possible. In our case, the lesion was submucosal. No abnormality could be found on endoscopy, and the results of multiple blind biopsies did not indicate a diagnosis.

Fine-needle aspiration is a safe and accurate method for the diagnosis of head and neck lesions. With MR-compatible instruments, MR can be used to guide needle placement in deep-seated lesions.

Although it is not possible to predict the histologic features of a lesion on the basis of the MR findings, certain clues to the nature of a lesion, including fluid accumulation, can be obtained by analyzing the signal intensities. Accumulations of mucous fluid, as in a mucus retention cyst, may have high protein concentrations with various signal intensities on T1- and T2-weighted images. It is well known that the T1 and T2 relaxation times are shortened as protein concentration increases [6]. Proteinaceous fluid may have high signal intensity on both T1- and T2-weighted images, whereas high concentrations of protein may have low signal intensities [6]. In our case, the

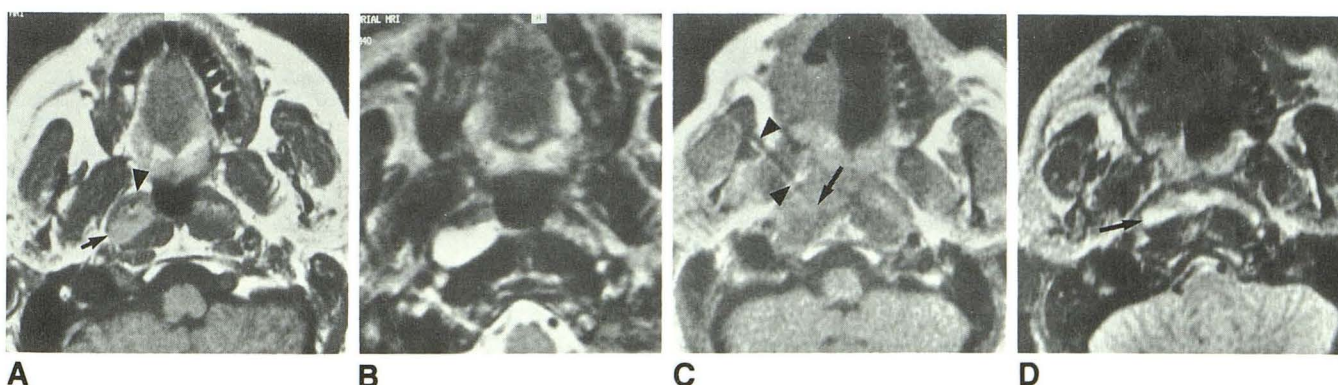


Fig. 1.—MR-guided aspiration of nasopharyngeal mucus retention cyst.

A, Axial T1-weighted MR image (SE 500/30) at level of soft palate shows small well-demarcated intermediate-signal lesion (arrow). Levator palatini muscle (arrowhead) is slightly displaced anteriorly without evidence of infiltration.

B, Axial T2-weighted MR image (SE 3000/90) at same level as A shows lesion has a very high signal intensity.

C, Axial T1-weighted MR image (SE 500/28) obtained after needle insertion shows needle track as a signal void (arrowheads). Needle tip (arrow) is located within lesion.

D, Axial T2-weighted MR image (SE 2000/84) obtained after needle aspiration shows decreased size of lesion (arrow) as compared with B.

smooth and clearly defined margin of the lesion; homogeneous signal intensities; and intermediate and high signal intensities on T1- and T2-weighted images, respectively, suggested an accumulation of proteinaceous fluid. Generally a retention cyst requires no treatment, but in this case, definitive diagnosis was necessary because of the persistent headache and the failure to obtain satisfactory biopsy material by using standard techniques.

Moon Hee Han
*Seoul National University College of Medicine
Seoul 110-744, Korea*
University of California, Los Angeles, School of Medicine
Los Angeles, CA 90024-1721
Bradley Jabour
James Andrews
Robert Lufkin
Lester Layfield
Donald Becker
William Hanafée
*University of California, Los Angeles, School of Medicine
Los Angeles, CA 90024-1721*

REFERENCES

1. Lufkin R, Teresi L, Hanafée W. New needle for MR-guided aspiration cytology of the head and neck. *AJR* **1987**;149:380-382
2. Lufkin R, Teresi L, Chiu L, Hanafée W. A technique for MR-guided needle placement. *AJR* **1988**;151:193-196
3. Duckwiler G, Lufkin RB, Teresi L, et al. Head and neck lesions: MR-guided aspiration biopsy. *Radiology* **1989**;170:519-522
4. Lufkin R, Layfield L. Coaxial needle system of MR- and CT-guided aspiration cytology. *J Comput Assist Tomogr* **1989**;13:1105-1107
5. Fredrickson JM. Oral cavity, oropharynx, nasopharynx. In: Cummings CW, ed. *Otolaryngology: head and neck surgery*. St. Louis: Mosby, **1986**:1501-1502
6. Som PM, Dillon WP, Fullerton GD, Zimmerman RA, Rajagopalan B, Marom Z. Chronically obstructed sinonasal secretions: observation on T1 and T2 shortening. *Radiology* **1989**;172:515-520