AJNR

Aneurysm of the azygos pericallosal artery: diagnosis by MR imaging and MR angiography.

J Cinnamon, J Zito, D J Chalif, M T Gorey, K S Black, D M Scuderi and R A Hyman

AJNR Am J Neuroradiol 1992, 13 (1) 280-282
http://www.ajnr.org/content/13/1/280.citation

This information is current as of October 11, 2024.

Aneurysm of the Azygos Pericallosal Artery: Diagnosis by MR Imaging and MR Angiography

Jay Cinnamon,[1] Joseph Zito,[3] David J. Chalif,[2] Michael T. Gorey,[1] Karen S. Black,[1] Donna Maria Scuderi,[1] and Roger A. Hyman[1]

Summary: We present a case of an aneurysm of an azygos pericallosal artery diagnosed on conventional MR imaging and MR angiography, and confirmed with conventional angiography and at surgical exploration.

Index terms: Arteries, Callosal (pericallosal); Aneurysm, magnetic resonance

The azygos pericallosal artery represents a rare anatomic variant where only a single enlarged pericallosal artery is present instead of the usual two. The azygos pericallosal artery divides in the region of the genu of the corpus callosum, sending out branches to supply the mesial surfaces of both cerebral hemispheres. Although rare, with a reported incidence of between 0.2% and 4% (1–3), its greatest significance rests in the high frequency of berry aneurysms noted to occur at its bifurcation.

Case Report

A 41-year-old woman with no significant history of past medical or psychological problems presented to medical attention complaining of a single episode of right body (face, arm, leg) weakness and numbness that lasted for 1 hr and then resolved. These symptoms may have been associated with an anxiety attack. At the time of her neurologic evaluation, her physical examination and laboratory blood analyses were noted to be unremarkable. The patient then underwent magnetic resonance (MR) imaging.

MR imaging was carried out on a 1.5 T system (Magnetom, Siemens AG, Erlangen, Germany). Axial images were acquired using spin echo (SE) pulse sequences of 3000/20/1 and 3000/90/1. Sagittal images were acquired using a SE pulse sequence of 400/15/3. These images revealed a single prominent midline vessel paralleling the usual course of the pericallosal artery. This vessel appeared to trifurcate just above the anterior body of the corpus callosum, at which point an aneurysm was suspected (Fig. 1). The MR imaging also demonstrated a small lipoma of the cerebellar vermis, but was otherwise unremarkable. MR angiography (MRA) was then carried out in axial, sagittal, and coronal orientations using a 3D-FISP sequence of 40/7/1, flip angle of 15, with flow compensation in the readout and slice-select directions. The results of this supported the initial impression (Fig. 2). A conventional angiogram was then performed with selective injections into both internal carotid arteries. Cut film imaging was carried out in posteroanterior and lateral projections. These images confirmed the findings seen on the MR study (Fig. 3). At surgery, a bulbous, aneurysmal trifurcation of the azygos pericallosal artery was encountered. Clipping was not possible without sacrificing one or more of the distal vessels. Accordingly, the lesion was wrapped and reinforced with muslin gauze.

Discussion

The anatomy and associated anomalies of the anterior cerebral arteries were studied by Baptista (1) who noted that the anomalies of the pericallosal arteries fall into three categories. The first category consists of the azygos pericallosal artery, where a single pericallosal artery is present from which branch vessels arise to supply the mesial surfaces of both cerebral hemispheres. The second category is a bihemispheric pericallosal artery, where two distinct pericallosal arteries are present, although one is hypoplastic and the other compensates by supplying portions of the contralateral hemisphere in addition to its ipsilateral hemisphere. The third category is that of a triplicate pattern, where in addition to the

Received May 10, 1991; final acceptance June 26 (no revision necessary).

[1] Department of Radiology, North Shore University Hospital, 300 Community Drive, Manhasset, NY 11030; and Cornell University Medical College, New York, NY. Address reprint requests to R. A. Hyman.

[2] Department of Neurosurgery, North Shore University Hospital, Manhasset, NY 11030; and Cornell University Medical College, New York, NY.

[3] Lakeville Magnetic Imaging, Manhasset, NY 11030.

AJNR 13:280–282, Jan/Feb 1992 0195-6108/92/1301-0280 © American Society of Neuroradiology

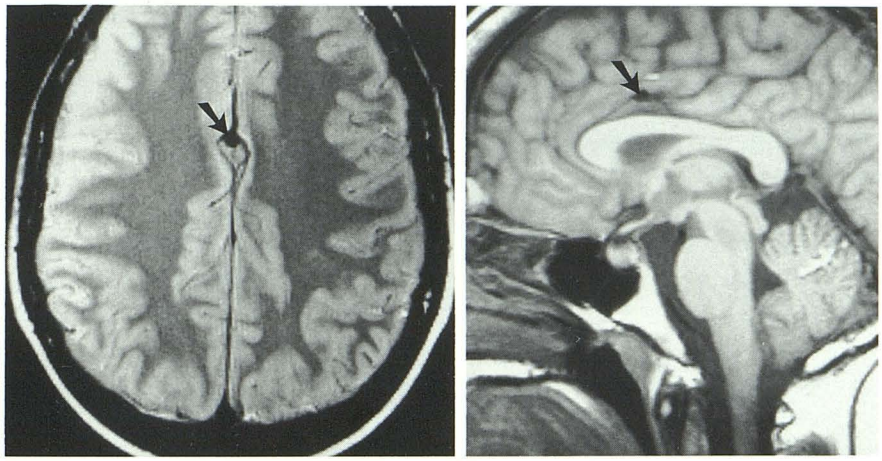

A B

Fig. 1. *A* and B, Axial 3000/20/1 and midline sagittal 400/15/3 SE MR images demonstrate a prominent midline vessel in the course of the pericallosal artery with an apparent aneurysm at its trifurcation (*arrows*). Note is also made of a cerebellar vermian lipoma on the sagittal image.

A B C

Fig. 2. *A*, *B*, and *C*, MR angiogram images in lateral, oblique, and frontal projections demonstrate an aneurysm at the trifurcation of the azygos pericallosal artery.

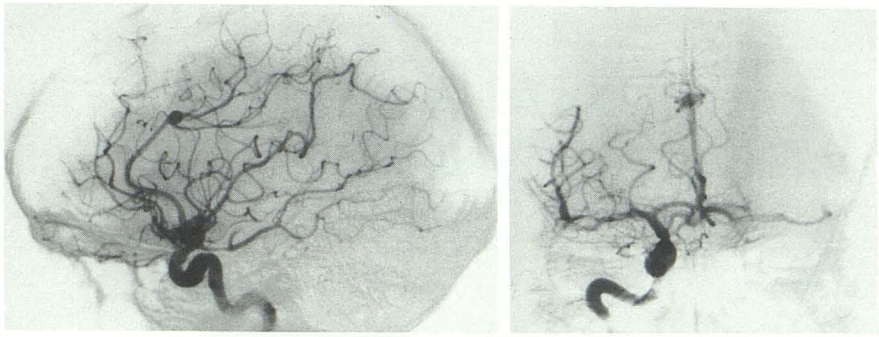

A B

Fig. 3. *A* and *B*, Lateral and posteroanterior images from conventional angiogram of selective right internal carotid artery injection confirm the MRA findings.

normal pericallosal arteries, there is a third accessory artery that arises from the anterior communicating artery and supplies portions of the mesial surfaces of one or both hemispheres.

Studies have indicated that the incidence of azygos pericallosal arteries in the general population is between 0.2% and 4% (1–3). The higher value of 4%, however, was based on a study of 107 angiograms rather than anatomical dissection and the authors concede that that figure may inadvertently include cases of bihemispheric pericallosal arteries that at times can appear angiographically indistinguishable from a true azygos artery (2).

Bihemispheric pericallosal arteries are thought to be somewhat more common. Baptista found 45 such cases among 381 brains (12%) (1) and Huber et al found three times as many bihemispheric variants as azygos vessels in a retrospective review of 7782 angiograms (3).

The clinical significance of these anomalies is twofold: 1) the existence of either an azygos or bihemispheric vessel can explain the presence of bilateral ischemic changes in the setting of occlu-

sion of the vessel; and 2) the high incidence of associated berry aneurysms. Multiple reports have supported the latter association (3–5). In particular, Huber et al found that, upon review of 17 cases where there was either an azygos or bihemispheric pericallosal artery, seven had aneurysms (41.1%) (3). Four of these 17 cases appeared to be true azygos arteries and two of these four patients were noted to have associated aneurysms (50%).

MR imaging and MRA provide a noninvasive means of investigating vascular anomalies and aneurysms, with the advantage of imaging in numerous projections. Although current MRA cannot achieve the resolution of conventional angiography, in this case, diagnostic information was actually obtained by the MR imaging and MRA and subsequently confirmed by conventional angiography.

References

1. Baptista AU. Studies on the arteries of the brain. II. The anterior cerebral artery: some anatomic features and their clinical implications. *Neurology* 1963;13:825–835
2. LeMay M, Gooding CA. The clinical significance of the azygos anterior cerebral artery. *Am J Roentgenol* 1966;98:602–610
3. Huber P, Braun J, Hirschmann D, Agyeman JF. Incidence of berry aneurysms of the unpaired pericallosal artery: angiographic study. *Neuroradiology* 1980;19:143–147
4. Katz RS, Horoupian DS, Zingesser L. Aneurysm of azygous anterior cerebral artery. *J Neurosurg* 1978;48:804–808
5. Kondo A, Koyama T, Ishikawa J, Iwaki K, Yamasaki T. Ruptured aneurysm of an azygos anterior cerebral artery. *Neuroradiology* 1979;17:227–229