

### Diffusion-Weighted MR Imaging and Ischemic Stroke

Marc Fisher<sup>1,3</sup> and Christopher H. Sotak<sup>2</sup>

Magnetic resonance imaging (MR) of ischemic cerebrovascular events with standard T1- and T2-weighted spin-echo techniques is widely employed. Standard MR demonstrates vascular changes such as the absence of a flow void and the presence of arterial enhancement within 2–4 hours of ischemic stroke onset in some cases (1). The earliest morphologic change in the brain parenchyma, swelling, is visible at the same timepoint, but obvious, quantifiable signal changes within the brain parenchyma are usually not detectable for 6–12 hours. Recent reports suggest that computerized tomography (CT) can demonstrate early parenchymal abnormalities with almost equal effectiveness (2, 3). Both standard MR and CT cannot reliably outline the extent of ischemic stroke injury during the first few hours. The ability to reliably image the location and extent of ischemic stroke within the first few hours would have an enormous impact on clinical diagnostic accuracy and might provide a useful adjunctive method to assign and assess therapy.

Diffusion-weighted MR imaging (DWI) is a new methodology that can apparently quantitatively demonstrate the extent of ischemic injury very rapidly. DWI signals are generated by evaluating the translational movement (Brownian motion) of water molecules, abundantly present in cerebral tissue, as compared to standard T1- and T2-weighted MR where image contrast is related to differences in T1- and T2-relaxation times, proton density, and flow (4). Diffusion weighting of an MR study can be accomplished by integrating strong, short dephasing and rephasing magnetic field gradients into the standard spin-echo imaging pulse sequence (5). DWI studies in experimental stroke models were initially performed by Moseley et al in a cat permanent middle cerebral artery occlusion (MCAO) model (6). Hyperinten-

sity on DWI, corresponding to the ischemic region at postmortem, was observed as early as 45 minutes after stroke onset. The same group, using a reversible MCAO model in rats, observed DWI changes 14 minutes after vascular occlusion and demonstrated that these abnormalities on DWI reverted to normal when the occlusion was removed after 33 minutes (7). Standard T2-weighted MR was unremarkable at these early timepoints, while <sup>31</sup>P and <sup>1</sup>H MR spectroscopy demonstrated changes compatible with ischemic injury within the region of DWI abnormality. Minematsu et al, using the same rat MCAO occlusion model, quantitatively evaluated DWI in early ischemic stroke (8). They observed that DWI ischemic lesion areas at 30 minutes after stroke onset (Fig. 1) were highly correlated with the area of infarction demonstrable at postmortem in permanently occluded animals. In a second experiment, Minematsu et al reperfused their animals after 1 or 2 hours of temporary ischemia (9). DWI studies were performed during and after occlusion and the DWI lesion areas (hyperintense regions) were compared. Within 1 hour of temporary occlusion, 55% of the DWI lesion area observed during occlusion reverted to normal on the postreperfusion DWI studies ( $P < .01$ ). With 2 hours of temporary occlusion, only 17% of the prereperfusion DWI lesion area was reversible. Postmortem infarct areas were highly correlated with the postocclusion DWI area of hyperintensity. These animal stroke model studies demonstrate that DWI can rapidly reveal the location and extent of ischemic brain injury and that DWI can be used to document the reversibility of ischemic injury by reperfusion.

The study by Chien et al extends these animal DWI studies to stroke patients, although at a later timepoint (10). The authors demonstrate that

---

<sup>1</sup> The Medical Center of Central Massachusetts, Worcester, MA, and the Department of Neurology and Radiology, The University of Massachusetts Medical Center, Worcester, MA.

<sup>2</sup> Department of Radiology, University of Massachusetts Medical Center, and the Department of Biomedical Engineering, Worcester Polytechnic Institute, Worcester, MA.

<sup>3</sup> Address reprint requests to Marc Fisher, MD, The Medical Center of Central Massachusetts, 119 Belmont Street, Worcester, MA 01605.

**Index Terms:** Brain, infarction; Magnetic resonance, diffusion weighted scanning; Commentaries

AJNR 13:1103–1105, July/Aug 1992 0195-6108/92/1304-1103 © American Society of Neuroradiology



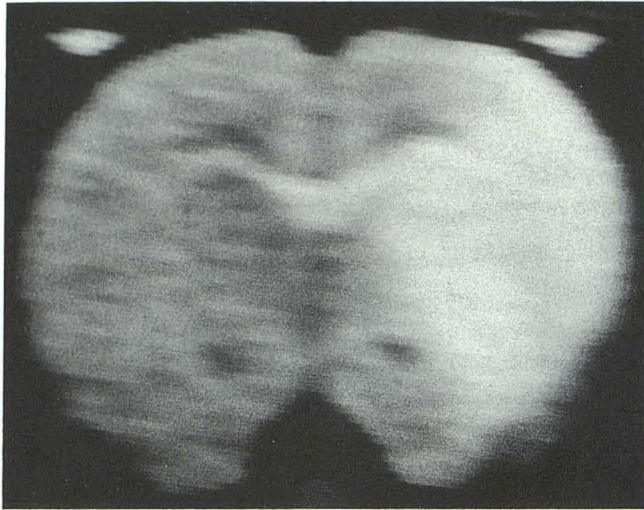


Fig. 1. A diffusion-weighted image at 30 minutes after stroke onset in a rat demonstrating hyperintensity in the territory of the occluded middle cerebral artery.

DWI studies can be reliably performed without great difficulty or artifacts, as early as 10 hours after stroke onset. At the subacute to chronic timepoints after stroke, which were measured, the DWI studies revealed varying differences of the apparent diffusion coefficient (ADC) of water within regions of homogeneous hyperintensity on standard T2-weighted images. The regional ADC differences suggest variations in the tissue consequences and responses to ischemic injury. This preliminary human stroke DWI study needs to be extended to evaluate DWI changes in humans within 3–4 hours after stroke onset.

Such early human stroke DWI studies will hopefully provide evidence that DWI can accurately characterize the extent and location of early ischemic injury, when standard MR shows little or no parenchymal abnormality. Additionally, early DWI studies may provide a mechanism to predict which ischemic tissue is salvageable or irreversibly injured. As noted by Chien et al (10), the ADC changes vary within subacute or chronic ischemic lesion and it is likely that ADC values also vary in hyperacute lesions. Irreversibly damaged tissue might have a lower ADC than salvageable tissue and this distinction could be made by ADC mapping. Such a possibility is suggested from the data in Minematsu's 1 and 2 hour DWI reversible ischemia studies in rats. It was observed that the signal intensity ratio between ischemic and normal tissue varied within the ischemic lesion and that a signal intensity ratio beyond a certain point identified ischemic regions that never reverted to normal after reperfusion.

Chien et al found an increase in the ADC of infarcted tissue when DWI studies were performed days or weeks after stroke onset. In animals, the ADC in ischemic tissue is reduced when DWI is performed minutes to a few hours after vascular occlusion. Knight et al observed an increase in DWI within the ischemic region when rats were serially studied over 48 hours (11). It is likely that the ADC results observed by Chien et al (10) reflect these serial changes and, presumably, very early DWI studies of human stroke will show a reduced ADC that should increase over time. The precise mechanisms responsible for the early reduction and later increase of the ADC within ischemic tissue are uncertain. The early ADC reduction is presumed to represent the rapid accumulation of intracellular water (cytotoxic edema) resulting from the failure of high-energy metabolism and cellular osmoregulation, although definitive correlation between DWI changes and cellular abnormalities remains lacking (4, 5). Other potential mechanisms for the early DWI changes in ischemic tissue include a local reduction of tissue temperature or reduced perfusion, leading to less molecular motion. These other possible explanations appear unlikely.

The ability to detect and quantify ischemic stroke lesions within a few hours from onset will afford both the clinician and radiologist invaluable information. Based upon the history and neurologic examination, an ischemic lesion can be difficult to localize and quantify. Early DWI studies should be able to provide this information in most cases, but clinical-radiologic correlation studies must be performed to validate the promise suggested by the animal DWI experiments. Very early DWI demonstration of ischemic regions can also be used to evaluate therapeutic intervention. Two groups have employed DWI studies as an *in vivo* marker of treatment response in animal stroke models (12, 13). Quantitative demonstration of differences in DWI ischemic lesion area provides a method to assess therapeutic response within a few hours of stroke onset. Serial DWI studies might be useful as therapeutic endpoints in conjunction with traditional clinical outcome scales.

DWI studies can be combined with perfusion imaging to evaluate parenchymal ischemia and the state of tissue perfusion. Magnetic susceptibility contrast agents interfere with the acquisition of relative T2\*-weighted signal (14). Thus, perfused brain will transiently appear hypointense



and nonperfused areas will appear relatively hyperintense. Regions of perfusion deficits correlate well with areas of ischemic injury, demonstrated by DWI in experimental stroke studies (12). Perfusion imaging with ultrafast acquisition techniques can be used to quantitatively evaluate cerebral blood volume and regional cerebral blood flow (15). These two MR modalities, DWI and perfusion imaging, should provide a plethora of important information in ischemic stroke patients and many more clinical research studies such as the one reported by Chien et al (10) are eagerly anticipated. A new era for the very early evaluation of ischemic cerebrovascular disorders appears to be dawning.

## References

1. Yuh WTC, Crain MR, Loes DJ, Greene GM, Ryals TJ, Sato Y. MR imaging of cerebral ischemia: findings in the first 24 hours. *AJNR* 1991;12:621-629
2. Horowitz SH, Zito JL, Donnarumma R, Patel M, Alvir J. Computed tomographic-angiographic findings within the first five hours of cerebral infarction. *Stroke* 1991;22:1245-1253
3. Mohr JP, Biller J, Hillal SK, et al. MR vs CT imaging in acute stroke (abstr). *Stroke* 1992;23:142
4. LeBihan D. Molecular diffusion nuclear magnetic resonance imaging. *Magn Reson Q* 1991;7:1-30
5. LeBihan D, Breton E, Lallemand D, Aubin ML, Vignaud J, Laval-Jeantet M. Separation of diffusion and perfusion in intravoxel incoherent motion MR imaging. *Radiology* 1988;168:497-505
6. Moseley ME, Kucharczyk K, Mintorovitch J, et al. Diffusion-weighted MR imaging of acute stroke: correlation of T2-weighted and magnetic susceptibility-enhanced MR imaging in cats. *AJNR* 1990;11:423-429
7. Mintorovitch J, Moseley ME, Chileuich L, Shimizu H, Cohen Y, Weinstein PR. Comparison of diffusion and T2-weighted MRI for the early detection of cerebral ischemia and reperfusion in rats. *Magn Reson Med* 1991;18:39-50
8. Minematsu K, Fisher M, Li L, Sotak CH, Davis MA, Fiandaca MS. Diffusion-weighted magnetic resonance imaging: rapid quantitative detection of focal brain ischemia. *Neurology* 1992;42:235-240
9. Minematsu K, Li L, Fisher M, Sotak CH, Davis MA. Diffusion-weighted MRI displays reversible and irreversible injury in a temporary ischemic stroke model (abstr). *Stroke* 1992;23:145
10. Chien D, Kwong KK, Gress DR, Buoanno FS, Buxton RS, Rosen BR. MR diffusion imaging of cerebral infarction in humans. *AJNR* 1992;13:1097-1102
11. Knight RA, Ordidge RJ, Helpert JA, Chepp M, Rodolosi LC, Peck D. Temporal evolution of ischemic damage in rat brain measured by proton nuclear magnetic resonance imaging. *Stroke* 1991;22:802-808
12. Kucharczyk J, Mintorovitch J, Moseley ME, et al. Ischemic brain damage: reduction by sodium-calcium ion channel modulator RS-87476. *Radiology* 1991;179:221-227
13. Minematsu K, Fisher M, Li L, Sotak CH, Knapp AG, Davis MA. A non-competitive NMDA antagonist, CNS 1102 reduces ischemic injury in-vivo and post-mortem infarction area (abstr). *Neurology* 1992;42(suppl 3):292
14. Rosen BR, Belliveau JW, Vereia JM, Brady TJ. Perfusion imaging with NMR contrast agents. *Magn Reson Med* 1990;14:249-265
15. Belliveau JW, Kennedy DW, McKinstry RC, et al. Functional mapping of the human visual cortex by magnetic resonance imaging. *Science* 1991;254:716-718