AJNR

Orbital mesenchymal chondrosarcoma.

K H Choi, M S Sung, K S Shinn and Y W Bahk

AJNR Am J Neuroradiol 1992, 13 (4) 1253-1255
http://www.ajnr.org/content/13/4/1253.citation

This information is current as
of October 11, 2024.

Orbital Mesenchymal Chondrosarcoma

Kyu H. Choi,[1] Mi S. Sung,[1] Kyung S. Shinn,[1] and Yong W. Bahk[1]

Summary: The authors describe the CT and plain film appearance of orbital mesenchymal chondrosarcoma in a 21-year-old woman and 28-year-old man, ie, large expansile masses with "heavy" or "stippled" calcifications and no evident erosion of bone.

Index terms: Orbits, neoplasms; Orbits, computed tomography

Mesenchymal chondrosarcoma is rare in the extraskeletal system and is even more unusual in the orbit. There is little difficulty making a histologic diagnosis because it consists of islands of well-differentiated cartilage surrounded by undifferentiated mesenchymal cells arranged in a hemangiopericytoma-like pattern (1–5). We have seen two identical cases of orbital mesenchymal chondrosarcoma in the last 2 years, and this article describes the findings on radiography and computed tomography (CT).

Case 1

A 21-year-old woman exhibited a severe right exophthalmos and loss of vision for several months. Because of her schizophrenic mental status, a reliable medical history could not be obtained. Physical examination on admission revealed that light perception by her exophthalmic right eye was absent with eversion of bulbar conjunctiva. Occular motility was relatively well preserved. On skull films, mottled calcifications were detected within the anteriorly protruded orbital mass. CT revealed a huge intraorbital mass with heavy central calcifications causing widening of the bony orbit (Fig. 1A). The globe was displaced inferiorly. Based on the CT findings, the differential diagnostic considerations were round cell sarcoma, meningioma, neurofibroma, or cavernous hemangioma.

Two weeks after admission, exenteration of the right orbit was performed, followed by reconstructive surgery. When orbital space was entered by using lateral approach, loosely encapsulated tumor mass was found in the retrobulbar space. The orbital bulb was somewhat shrunken and deviated inferiormedially. Slight erosion of the lateral and superior orbital rim was noticed. Extraocular muscles and conjunctiva were free of tumor invasion. The specimen consisted of the orbital bulb attached to the optic nerve and a retrobulbar mass which measured 5.5 × 4 × 4 cm. The mass was partially encapsulated by a yellowish-gray external material. On serial section, it was found to contain calcifications and necrotic areas (Figs. 1B and 1C). The patient was discharged several days after an uneventful postoperative course.

Case 2

A 28-year-old man suffered from a severe exophthalmos, occasional pain, and blindness of the right eye for 1 year. Physical examination on admission revealed a tender protruding mass approximately 5 cm in size in the right eye. Laboratory findings were all negative. Anterioposterior projection of the orbit demonstrated large round calcifications overlying the widened right orbit (Fig. 2A). On CT taken after intravenous injection of the iodine contrast medium, there was a relatively well-marginated, slightly enhancing soft-tissue mass that contained central heavy calcifications in the expanded extrabulbar orbital space (Figs. 2B and 2C). The globe was found to be markedly displaced inferiormedially. Because of CT appearances similar to those of case 1, the same differential possibilities, in addition to mesenchymal chondrosarcoma, were entertained.

The patient underwent exenteration of the mass and globe, followed by reconstructive surgery using the temporalis muscle. Lateral approach was also used to expose the orbital space. There was a 5 × 4 × 4 cm sized retrobulbar mass that partially encircled hardened globe. The tumor, the globe, and the optic nerve were removed en bloc.

Discussion

Chondrosarcoma may be classified as two types: differentiated (conventional) and mesenchymal. Both are capable of arising as primary tumors in bones and soft tissues (6). Mesenchymal chondrosarcoma has a predilection for the bone and rarely occurs in the extraskeletal soft

Received June 17, 1991; revision requested July 15; revision accepted October 16.

[1] All authors: Department of Radiology, Kangnam St. Mary's Hospital, Catholic University, Medical College, 505 Banpo Dong, Suhcho-Ku, Seoul, Korea. Address reprint requests to K. H. Choi.

AJNR 13:1253–1255, Jul/Aug 1992 0195-6108/92/1304-1253 © American Society of Neuroradiology

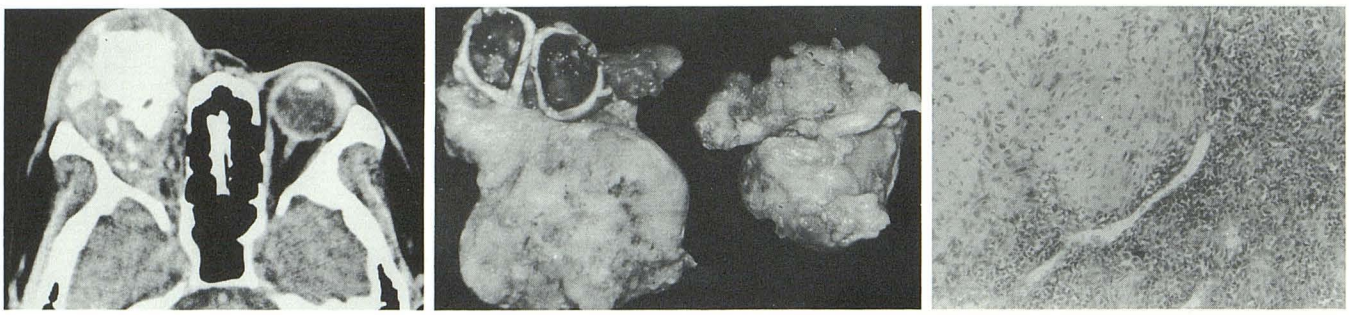

A B C

Fig. 1. Twenty-one-year-old woman. *A*, Axial noncontrast CT section of the orbit shows a large expansile mass with heavy calcifications. Note the lack of bony destruction.

B, Bisected orbital bulb and large retrobulbar mass. The bulb was to be shrunken with retinal hemorrhage and intravitreous tumor invasion. The mass contains heavy central calcifications with necrotic areas.

C, Islands of cartilage are surrounded by small undifferentiated cells arranged in a hemangiopericytoma-like pattern (hematoxylineosin).

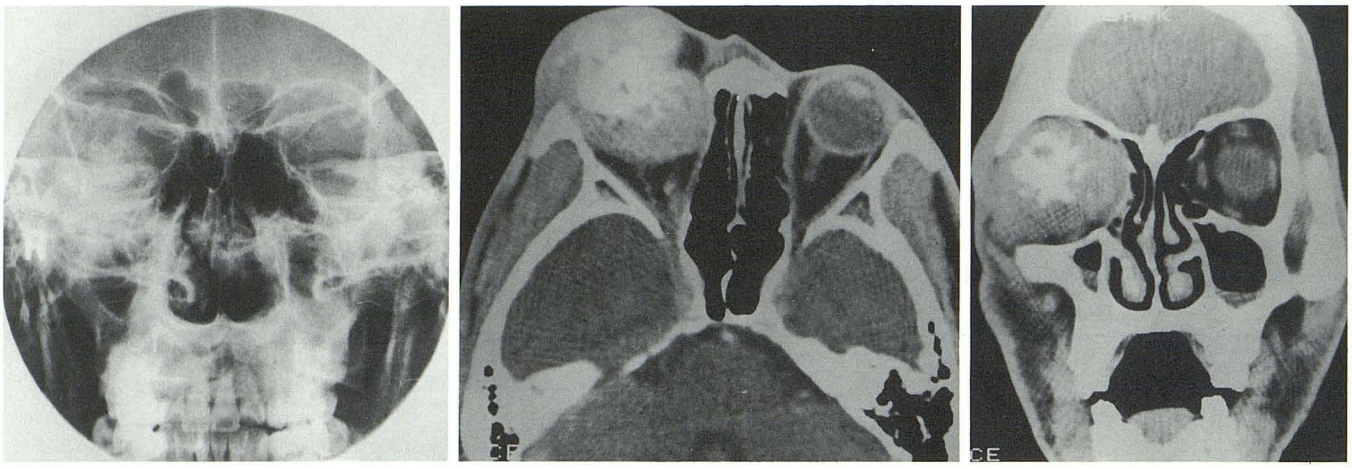

A B C

Fig. 2. Twenty-nine-year-old man.

A, Anteroposterior projection of the orbit shows stippled calcifications overlying the right orbit.

B and *C*, Axial CT section of the orbit (*B*) with intravenous contrast material shows same findings as in case 1. Note again marked orbital expansion without bony erosion. Coronal section (*C*) shows the heavily calcified protruding mass.

tissue (1–4). Common skeletal sites of involvement are the pelvic bone, the femur, the vertebrae, the mandible, and the rib. In extraskeletal sites, the cranial or spinal meninges, and the lower extremity are most frequently affected. Orbital involvement is so rare that, to the best of our knowledge, less than 15 cases have been reported in the literature (2, 3, 6–8). In a review of 111 cases of bone and soft-tissue mesenchymal chondrosarcoma by Nakashima et al (2), frequent sites of extraskeletal involvement were, in descending order, the cranial and spinal meninges, the lower extremity, and the orbit in a single patient among 39 total extraskeletal cases. They also reviewed 132 previously reported cases of mesenchymal chondrosarcoma, exclusive of cases included in their series, of which seven orbital cases were found in the 57 extraskeletal sites.

The peak age for tumor development is in the second and third decades with slightly higher incidence in women. The common radiographic findings for skeletal lesions are osteolytic destructions with mottled calcifications resembling conventional chondrosarcoma. The usual appearances of extraskeletal lesions on plain roentgenograms are flocculent or stippled calcifications within the tumor mass (2–4). There are few publications concerning CT findings of mesenchymal chondrosarcomas in extraskeletal sites. Although it is premature to draw any conclusions from our two cases, CT will definitely help pinpoint the site of tumor origin and narrow down differential diagnosis, since the tumors in our cases were thought to most likely arise in the retroglobal intraconal soft tissue, and could be further characterized by their relation to the surrounding

structures, their large central calcifications, and the absence of bony erosion. Entities that should be differentiated from orbital mesenchymal chondrosarcoma include meningioma, soft-tissue round-cell sarcoma, neurinoma, calcified granulomatous infection, and metastasis.

In a typical case, orbital mesenchymal chondrosarcoma poses no problem for histologic diagnosis to one familiar with this disease because of characteristic microscopic features. Undifferentiated mesenchymal cells, interspersed mesenchymal cells, and areas of abrupt transition from mesenchymal cells to cartilage arranged in a hemangiopericytoma-like pattern (1–5) are seen. Ewing tumor, small-cell osteosarcoma, and synovial sarcoma may also simulate mesenchymal chondrosarcoma pathologically.

Radical resection, if possible, seems to offer the best result. Radiation and/or chemotherapy can be used in conjunction with resection or as an alternative mode of therapy (2–4); however, the value of radiation or chemotherapy or both is not yet convincingly established. The prognosis of mesenchymal chondrosarcoma is usually poor. Long-term follow-up seems to be essential because the clinical course may be protracted and local recurrence or metastasis sometimes occurs even after more than 20 years. In a group of 23 patients from the Mayo Clinic, the 5-year survival rate was 54.6% and the 10-year survival rate was 27.3% (2). In follow-up analysis of 35 patients by Huvos et al (4), median survival was 37.9 months. Our two patients have been followed up and free of local recurrence or distant metastasis over 2 years after surgery.

References

1. Jakobiec FA, Font RL. Mesenchymal tumors. In: Spencer WH, ed. *Ophthalmic pathology*. Philadelphia: Saunders, 1986:2554–2603
2. Nakashima Y, Unni KK, Shives TC, et al. Mesenchymal chondrosarcoma of bone and soft tissue: a Review of 111 cases. *Cancer* 1986; 57:1444–1453
3. Salvador AH, Beabout JW, Dahlin DC. Mesenchymal chondrosarcoma: observations on 30 new cases. *Cancer* 1971;28:605–615
4. Huvos AG, Rosen G, Dabska M, Marcove RC. Mesenchymal chondrosarcoma: a Clinicopathological analysis of 35 patients with emphasis on treatment. *Cancer* 1983;51:1230–1237
5. Bloch DM, Bragoli AJ, Collins DN, Batsakis JG. Mesenchymal chondrosarcomas of the head and neck. *J Laryngol Otol* 1979;93: 405–412
6. Cardenas-Ramirez L, Albores-Saavedra J, Buen SD. Mesenchymal chondrosarcoma of the orbit: report of the first case in orbital location. *Arch Opthalmol* 1971;86:410–413
7. Sevel D. Mesenchymal chondrosarcoma of the orbit. *Br J Opthalmol* 1974;58:882–887
8. Shimo-Oku M, Okamoto N, Ogita Y, Sashikata T. A case of mesenchymal chondrosarcoma of the orbit. *Acta Ophthalmol* 1980;58: 831–840