

Are your **MRI contrast agents** cost-effective?

Learn more about generic **Gadolinium-Based Contrast Agents**.



FRESENIUS
KABI

caring for life

AJNR

Neuroepithelial (colloid) cyst of the cerebellar vermis containing a xanthogranuloma.

M Tada, M Koiwa, Y Chono, M Nemoto, T Kashiwaba, H Abe and K Miyasaka

AJNR Am J Neuroradiol 1993, 14 (4) 951-953

<http://www.ajnr.org/content/14/4/951>

This information is current as of May 4, 2024.

Neuroepithelial (Colloid) Cyst of the Cerebellar Vermis Containing a Xanthogranuloma

Mitsuhiro Tada,^{1,4} Mitsuyuki Koiwa,³ Yoshimi Chono,³ Masato Nemoto,³ Takeshi Kashiwaba,³ Hiroshi Abe,¹ and Kazuo Miyasaka²

Summary: A case of a neuroepithelial cyst of the cerebellar vermis is presented. The cyst contained a viscous fluid and a xanthogranulomatous nodule. The fluid showed high signal on T1- and low signal on T2-weighted MR images. The xanthogranuloma showed mixed intensities with partial contrast enhancement. The correlation of the cyst contents and MR signals is discussed.

Index terms: Cerebellum, vermis; Brain, cysts; Cerebellum, magnetic resonance

Neuroepithelial (colloid) cysts represent 0.25% to 1% of intracranial tumors. Although most frequent in the third ventricle (1–9), they are found rarely in other parts throughout the neu-

axis, including ventricular system, subarachnoid space, and brain parenchyma. Neuroradiologic findings vary depending on the location and cyst contents. We describe a case of a neuroepithelial cyst located in the cerebellar vermis, whose contents gave neuroradiologic findings simulating a cerebellar hemangioblastoma.

Case Report

The patient was a 44-year-old woman who presented with a dull pain in the occipital region, nausea, and unsteady gait for a month. Physical and neurologic examination revealed a port wine nevus in the right side of the upper

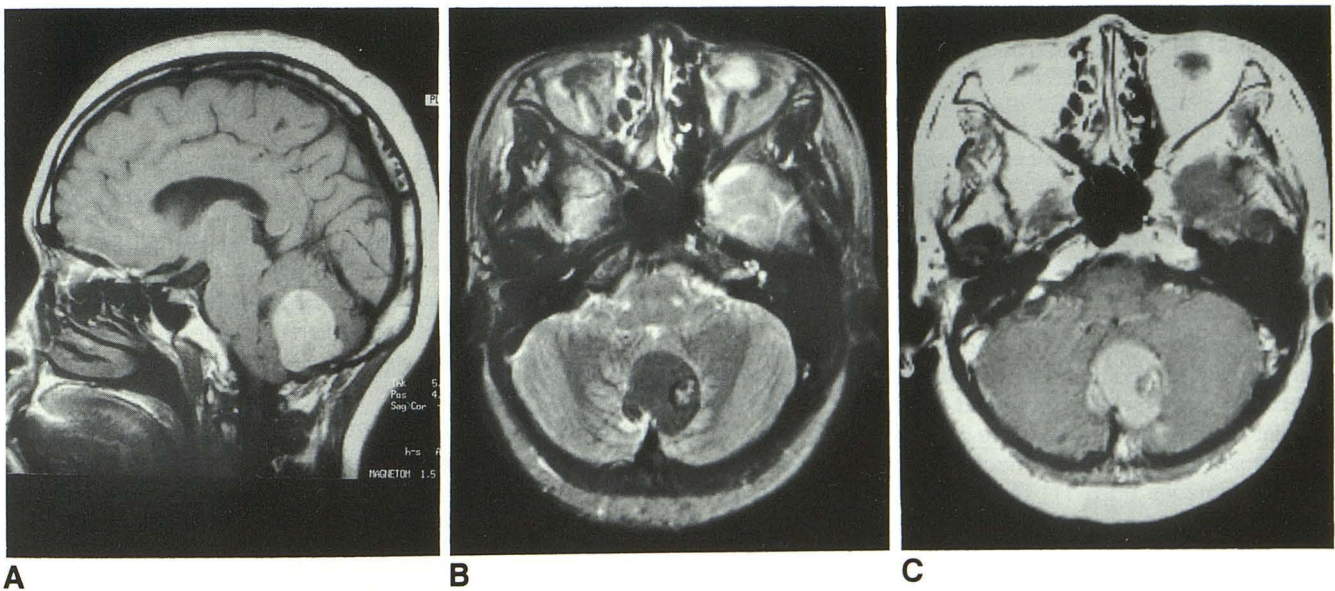


Fig. 1. A, Sagittal T1-weighted MR image, 600/15 (TR/TE), shows hyperintense cyst in the cerebellar vermis. B, Axial T2-weighted image (3000/90) shows hypointense cyst content and nodule with mixed intensity. C, Axial T1-weighted image with Gd-DTPA enhancement shows a partial enhancement in the nodule in the cyst.

Received May 15, 1992; accepted after revision August 20.

¹ Department of Neurosurgery and ² Department of Radiology, Hokkaido University School of Medicine, Sapporo, Japan.

³ Kashiwaba Neurosurgical Hospital, Sapporo, Japan.

⁴ Address reprint requests to Mitsuhiro Tada, MD, Department of Neurosurgery, Hokkaido University School of Medicine, North-15 West-7, Sapporo, 060, Japan.

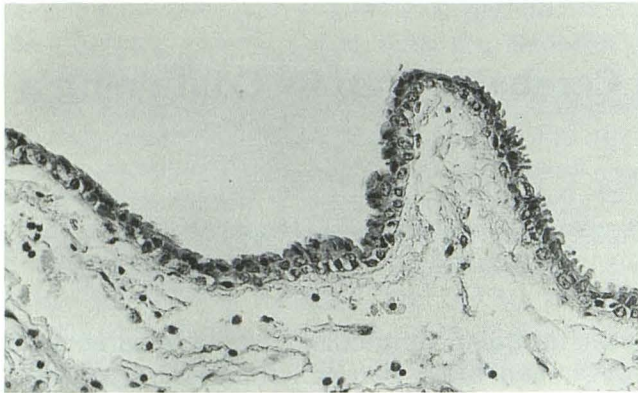
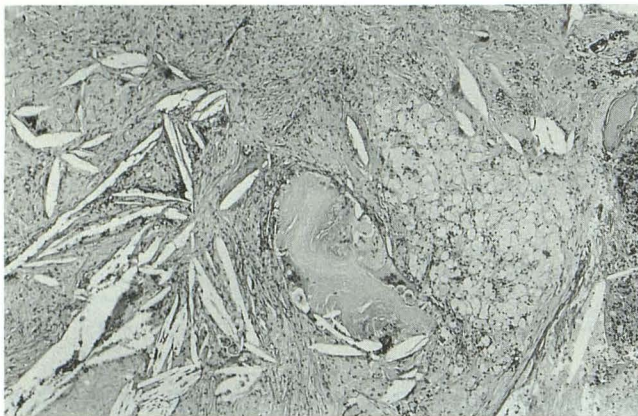
**A****B**

Fig. 2. A, Photomicrograph of the cyst wall (hematoxylineosin stain, original magnification $\times 200$). It consists of inner columnar epithelial layer and outer loose connective tissue.

B, Photomicrograph of the xanthogranuloma (hematoxylineosin, $\times 40$). Foamy macrophages, foreign-body giant cells, and other inflammatory cells are seen in a fibrotic granulation tissue with clefts of cholesterol crystal.

lip and a mild truncal ataxia. Computed tomography (CT) scan showed a round mass of increased density in the cerebellar vermis which contained a small round isodense nodule. On magnetic resonance (MR), this mass was hyperintense on T1-weighted images and hypointense on T2-weighted images (Fig. 1). The small nodule in the mass showed a hypointensity on T1- and mixed intensity on T2-weighted images. The nodule showed only slight contrast enhancement on CT and MR. Bilateral vertebral angiography revealed an expansive avascular lesion. Preoperative possible diagnosis was a cystic hemangioblastoma with hemorrhage.

A suboccipital craniectomy was performed; a brownish-green cystic mass was found within the inferior vermis. The cyst wall had a thin arachnoidlike membrane and contained yellowish green turbid fluid that rapidly coagulated in air. Adjacent to the left inside wall of the cyst a 1-cm-sized ivory-colored mass was found. It was easily removed from the cyst cavity. Pathologic examination revealed that the wall of the cyst consisted of inner columnar

epithelial layer and outer loose connective tissue (Fig. 2A). The nodular mass contained fibrotic granulation tissue, foamy macrophages, foreign-body giant cells, other inflammatory cells, and clefts of cholesterol crystal, forming a typical xanthogranuloma (Fig. 2B).

The patient was discharged from the hospital 2 weeks after the surgery without any neurologic symptoms. The MR taken 1 year later showed no recurrence of the tumor; the patient is now in good health.

Discussion

Cysts lined with a single layer of epithelial cells have been given a variety of names depending on their location and microscopic features, including "neuroepithelial cyst," "colloid cyst," "ependymal cyst," "paraphyseal cyst," "glioependymal cyst," "choroid plexus cyst," and merely "epithelial cyst." The nature and origin of these lesions are still debatable. Neuroepithelial cysts are found throughout the neuraxis, but most commonly appear adjacent to the ventricular system or in the subarachnoid space above the tentorium. Rarely, they are located in the posterior fossa in the quadrigeminal, prepontine, cerebellopontine angle and lateral medullary cistern (1-4), the pons (1, 5), the cerebellar hemisphere (6), and the fourth ventricle (7). To our knowledge, there have been only two reported cases of this lesion occurring in the cerebellar vermis (8, 9).

Formation of xanthogranuloma is rarely encountered in the "colloid" cyst of the third ventricle or lateral ventricle (10-15), although some cases have been reported to occur de novo from the choroid plexus in the absence of neuroepithelial cyst (16). Localization in the infratentorial fossa seems to be exceptional (17). As speculated by Shuangshoti et al, bleeding in cyst is probably responsible for the development of a xanthogranuloma containing cholesterol crystals, although some authors have suggested that such a reaction may result from desquamation of the cells lining the cyst or from the irritative action of the colloid material (10). The color of the cyst at the operation suggested old hemorrhagic episodes. The high density of the cyst content on CT scan is attributable to increased electron density material probably caused by high protein or metallic content (18), possibly derived from previous bleeding or desquamation of cells. The high signal on T1- and low signal on T2-weighted MR images may be caused by high cholesterol content, metallic (Mg, Ca, Cu, Fe) content (18, 19) or by the presence of mucinous materials (20). The signal

on MR image of the xanthogranuloma (ie, low- to iso-signal in T1- and mixed signal in T2-weighted images) contrasts to the signal of cyst fluid. This difference in relaxation times between the cholesterol-rich cyst fluid and the xanthogranuloma is attributed to states of cholesterol (ie, liquid versus solid) (21).

Although the present case showed a striking resemblance in radiologic images to a hemorrhagic cystic hemangioblastoma with a mural nodule (22), there were some features that were not typical of a hemangioblastoma. Our case lacked the intense contrast enhancement of a "mural nodule," a vascular stain on angiography, the presence of a nodule along a pial surface, or flow void on MR, which are common to a hemangioblastoma. Therefore, it might be possible to differentiate the rare lesion of this kind from that more common cystic lesion of the infratentorial fossa.

References

1. Andrews BT, Halks-Miller M, Berger MS, Rosenblum ML, Wilson CB. Neuroepithelial cysts of the posterior fossa: pathogenesis and report of two cases. *Neurosurgery* 1984;15:91-95
2. Davis RP, Sachdev VP, Sachar M. Ependymal cyst of the quadrigeminal plate: case report. *Neurosurgery* 1985;16:96-99
3. Romero FJ, Ortega A, Ibarra B, Pomés J, Rovira M. Craniocervical neuroepithelial cyst (colloid cyst). *AJNR: Am J Neuroradiol* 1987;8:1001-1002
4. Warf BC, Mapstone TB. Ventral brain-stem compression from a subarachnoid ependymal cyst. *Childs Nerv Syst* 1990;6:225-227
5. Mortara RH, Markesbery WR, Brooks WH. Pontine cyst presenting as trigeminal pain: case report. *J Neurosurg* 1974;41:636-639
6. Honda E, Hayashi T, Kuramoto S. A case of choroid plexus papilloma in the lateral ventricle, complicated by a neuroepithelial cyst in the posterior fossa in a newborn infant. *Kurume Med* 1984;31:115-124
7. Sharpe JA, Deck JHN. Neuroepithelial cyst of the fourth ventricle: case report. *J Neurosurg* 1977;46:820-824
8. Handa H, Bucy PC. Benign cysts of brain simulating brain tumor. *J Neurosurg* 1956;13:489-499
9. Hasegawa H, Ushio Y, Oku Y, Iwata Y, Kanai N, Kamikawa K. Neuroepithelial cyst of the cerebellar vermis. *Surg Neurol* 1976;6:181-184
10. Shuangshoti S, Phonprasert C, Suwanwela N, Netsky M. Combined neuroepithelial (colloid) cyst and xanthogranuloma (xanthoma) in the third ventricle. *Neurology* 1975;25:547-552
11. Rush JL, Kusske JA, Porter RW. Xanthogranulomas of the third ventricle. *Neurosurgery* 1979;4:329-333
12. Szper I, Oi S, Leetsema J. Xanthogranuloma of the third ventricle: case report. *J Neurosurg* 1979;51:565-568
13. Antunes JL, Kvam D, Ganti SR, Louis KM, Goodman J. Mixed colloid cyst-xanthogranuloma of the third ventricle. *Surg Neurol* 1981;16:256-261
14. Matsushima T, Fukui M, Kitamura K. Mixed colloid cyst-xanthogranuloma of the third ventricle: a light and electron microscopic study. *Surg Neurol* 1985;24:457-462
15. Hadfield MG, Ghatak NR, Wanger GP. Xanthogranulomatous colloid cyst of the third ventricle. *Acta Neuropathol* 1985;66:343-346
16. Montaldi S, Deruaz J-P, Cai Z-T, de Tribolet N. Symptomatic xanthogranuloma of the third ventricle: report of two cases and review of the literature. *Surg Neurol* 1989;32:200-205
17. Vaquero J, Leunda G, Cabezudo JM. Posterior fossa xanthogranuloma: case report. *J Neurosurg* 1979;51:718-722
18. Maeder PP, Holtas SL, Basibuyuk LN, Salford LG, Tapper UA, Brun A. Colloid cysts of the third ventricle: correlation of MR and CT findings. *AJNR: Am J Neuroradiol* 1990;11:575-581
19. Wilms G, Marchal G, Van Hecke P, et al. Colloid cysts of the third ventricle: MR findings. *J Comput Assist Tomogr* 1990;14:527-531
20. Scotti G, Scialfa G, Colombo N, Londoni L. MR in the diagnosis of colloid cysts of the third ventricle. *AJNR: Am J Neuroradiol* 1988;8:370-372
21. Yuh WTC, Barloon TJ, Jacoby CG, Schultz DH. MR of fourth-ventricular epidermoid tumors. *AJNR: Am J Neuroradiol* 1988;9:794-796
22. Lee SR, Sanches J, Mark AS, Dillon WP, Norman D, Newton TH. Posterior fossa hemangioblastomas: MR imaging. *Radiology* 1989;171:463-468